

# Successful Catheter Ablation of Electrical Storm After Myocardial Infarction

Dietmar Bänsch, MD\*; Feifan Oyang, MD\*; Matthias Antz, MD; Thomas Arentz, MD; Reinhold Weber, MD; Jesus E. Val-Mejias, MD; Sabine Ernst, MD; Karl-Heinz Kuck, MD

**Background**—We report on 4 patients (aged 57 to 77 years; 3 men) who developed drug-refractory, repetitive ventricular tachyarrhythmias after acute myocardial infarction (MI). All episodes of ventricular arrhythmias were triggered by monomorphic ventricular premature beats (VPBs) with a right bundle-branch block morphology (RBBB).

**Methods and Results**—Left ventricular (LV) mapping was performed to attempt radiofrequency (RF) ablation of the triggering VPBs. Activation mapping of the clinical VPBs demonstrated the earliest activation in the anteromedial LV in 1 patient and in the inferomedial LV in 2 patients. Short, high-frequency, low-amplitude potentials were recorded that preceded the onset of each extrasystole by a maximum of 126 to 160 ms. At the same site, a Purkinje potential was documented that preceded the onset of the QRS complex by 23 to 26 ms during sinus rhythm. In 1 patient, only pace mapping was attempted to identify areas of interest in the LV. Six to 30 RF applications abolished all local Purkinje potentials at the site of earliest activation and/or perfect pace mapping and suppressed VPBs in all patients. No episode of ventricular tachycardia or fibrillation has recurred for 33, 14, 6, and 5 months in patients 1, 2, 3, and 4, respectively.

**Conclusions**—Incessant ventricular tachyarrhythmias after MI may be triggered by VPBs. RF ablation of the triggering VPBs is feasible and can prevent drug-resistant electrical storm, even after acute MI. Catheter ablation of the triggering VPBs may be used as a bailout therapy in these patients. (*Circulation*. 2003;108:3011-3016.)

**Key Words:** fibrillation ■ myocardial infarction ■ ablation ■ tachycardia

A persistent electrical storm after acute myocardial infarction (MI) is rare but very serious if it occurs.<sup>1</sup> Recommendations for antiarrhythmic drug therapy include class I antiarrhythmic drugs (eg, lidocaine, procainamid<sup>2</sup>), amiodarone,<sup>3,4</sup> and sympathetic blockade.<sup>1</sup> Class I antiarrhythmic drugs often fail to maintain sinus rhythm.<sup>1</sup> Amiodarone is effective, but sufficient rhythm control may take a few days.<sup>4-6</sup> Even with sympathetic blockade, overall mortality remains high.<sup>1</sup> We report on 4 patients in whom drug-refractory, life-threatening, repetitive ventricular tachyarrhythmias after MI could only be managed by radiofrequency (RF) ablation of the triggering ventricular premature beats (VPBs).<sup>4,6</sup>

## Methods

### Patients

During the past 3 years, 4 patients (aged 57 to 77 years; 3 men) were referred to our clinic with acute MI (2 anterior, 2 inferior), impaired left ventricular (LV) function, and persistent, drug-refractory electrical storm (Table). (As of this report, we have managed 2340 patients with acute MI. The 4 patients described were the only ones with persistent electrical storm despite therapy with amiodarone and  $\beta$ -blocker.) Maximum creatine kinase was 471 to 1615 U/L. All

patients were successfully revascularized by PTCA or bypass operation within 5 hours to 4 days after initial symptoms (Table).

Patients 1 and 2 did not have any conduction abnormalities during sinus rhythm, whereas patient 3 had intermittent sinus arrest, AV block I, and left anterior hemiblock (QRS duration 120 ms). Patient 4 had a right bundle-branch block (RBBB; QRS duration 120 ms).

Despite revascularization, all patients developed life-threatening repetitive episodes of ventricular fibrillation (VF) and rapid ventricular tachycardia (VT) triggered by frequent monomorphic VPBs with RBBB morphology. VPBs had a superior axis in patients 1 and 3, who had inferior MIs, and an inferior axis in patient 2, who had an anterior MI (Figure 1). Patient 4, with an anterior MI and a stenosis of the right coronary artery, had VPBs with both inferior and superior axes. VPBs had a QRS duration between 120 and 160 ms with discrete beat-to-beat variations in morphology and duration in each patient (Figures 2 through 5). VPBs were coupled to the preceding sinus or atrial paced beat by 270 to 400 ms. Coupling increased after initiation of antiarrhythmic drug therapy, especially in patient 3.

In patient 1, the VPBs triggered frequent nonsustained polymorphic VTs and 19 episodes of VF starting at day 7 after MI and emergency bypass operation. Patient 2 had repetitive nonsustained polymorphic VTs 3 days after acute MI and 1 day after PTCA of the left anterior descending artery and was defibrillated 72 times for VF during a 24-hour period (Figure 2). Patient 3 developed repetitive nonsustained polymorphic VTs and was resuscitated for prolonged phases of incessant VF beginning the first day of symptoms. He

Received February 5, 2003; de novo received August 15, 2003; revision received September 1, 2003; accepted September 12, 2003.

From the Department of Cardiology (D.B., F.O., M.A., S.E., K.-H.K.), AK St. Georg, Hamburg, Germany; Department of Rhythmology (T.A., R.W.), Bad Krozingen, Germany; and the Wichita Institute for Clinical Research, Wichita, Kan (J.E.V.-M.).

\*Dietmar Bänsch and Feifan Oyang contributed equally to ideas, data collection, and manuscript preparation.

Correspondence to Karl Heinz Kuck, MD, Department of Internal Medicine II, Cardiology, Allgemeines Krankenhaus St. Georg, Lohmühlenstrasse 5, 20099 Hamburg, Germany. E-mail BAE151162@aol.com

© 2003 American Heart Association, Inc.

*Circulation* is available at <http://www.circulationaha.org>

DOI: 10.1161/01.CIR.0000103701.30662.5C

## Patient Characteristics and Results

	Patient			
	1	2	3	4
Gender	Female	Male	Male	Male
Age, y	63	67	77	57
Ejection fraction, %	25	34	37	30
Infarction	Inferior, history of anterior	Anterior	Inferior	Anterior
Maximum creatine kinase, U/L	1057	1615	471	1076
Coronary status at initial presentation	RCA closure	LAD closure	RCA closure	LAD closure, RCA stenosis
Time between initial symptoms and coronary intervention, d	1	2	4	0.21
Intervention	CABG	CABG	PTCA/CABG	PTCA
Time between initial symptoms and occurrence of VF, d	7	3	1	5
Time between initial VF episode and catheter ablation, d	2	4	10	11
Type of ventricular tachyarrhythmia	Repetitive VF and pVT	Incessant VF and pVT	Incessant VF and mVT	Incessant VF and mVT
No. of VF episodes	19	72	Repetitive resuscitation	60
Intravenous antiarrhythmic drugs (oral antiarrhythmic drugs)	Amiodarone, lidocaine ( $\beta$ -blocker)	Amiodarone, lidocaine, $\beta$ -blocker	Amiodarone, lidocaine, $\beta$ -blocker	Amiodarone, lidocaine, $\beta$ -blocker
Temporary suppression of premature beats	IV adenosine	Overdrive pacing	Overdrive pacing	Overdrive pacing, phenytoin
Axis of triggering premature beat	Superior	Inferior	Superior	Inferior/superior
QRS duration of sinus beat (ms) and morphology	90	90	120 LAH	120 RBBB
QRS duration of VPB, ms	130–140	140–150	120–130	130–160
Sinus to premature beat, ms	320	270–300	320–400*	380
Earliest Purkinje to onset of VPB, ms	126	132	160	One VPB initiating 1 episode of VF
Stimulus to QRS onset at sites with best pace map, ms	30–40	30–40	40–50	0–10
No. of VF/VT episodes during EP study	0	9	6	1
No. of RF applications	13	6	21	30
Site of RF applications	Inferomedial	Anteromedial	Inferomedial	Anteromedial 10, inferomedial 20
Antiarrhythmic therapy after ablation	No AA drugs, ICD implantation	No AA drugs, ICD implantation	Amiodarone for atrial fibrillation	ICD implantation
Follow-up, mo	31	12	4	3
VF or VT recurrence	No	No	No	No

RCA indicates right coronary artery; LAD, left anterior descending artery; pVT, polymorphic VT; mVT, monomorphic VT; LAH, left anterior hemiblock; EP, electrophysiological; AA, antiarrhythmic; and ICD, implantable cardioverter defibrillator.

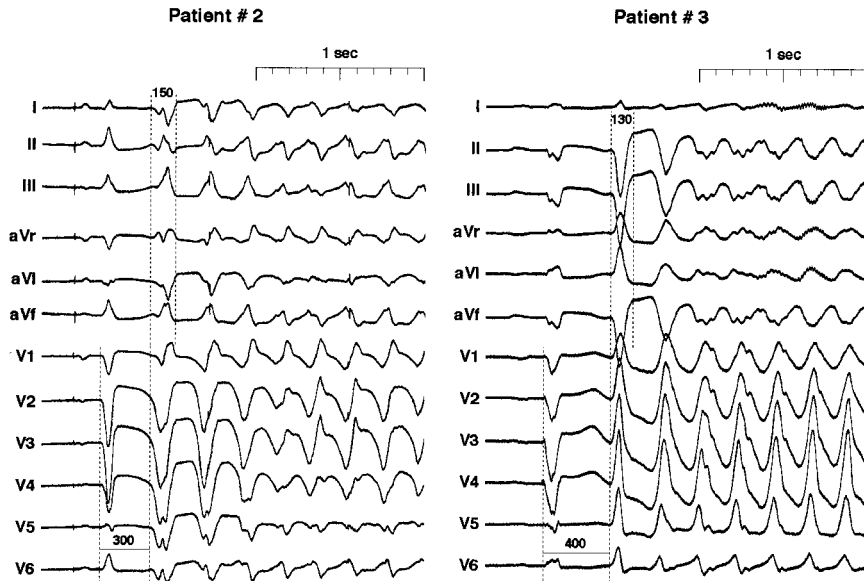
\*Coupling of the VPB was shorter early after MI. After initiation of antiarrhythmic drug therapy, coupling became prolonged.

continued to have repetitive episodes of VF beyond the day of coronary intervention. After initiation of amiodarone therapy, the VPBs initiated fast monomorphic VTs (cycle length 220 to 250 ms; Figure 2). Patient 4 began to have recurrent episodes of VF on day 5 after MI and had to be defibrillated 60 times during the following days.

Intravenous amiodarone (600-mg bolus, 1.4 g/24 hours) and lidocaine (150-mg bolus, 4 mg/min) were ineffective in all patients;  $\beta$ -blocker therapy (metoprolol 10-mg IV bolus and continuous infusion at 1 mg/h) was ineffective to suppress VPBs and ventricular

tachyarrhythmias in patients 2, 3, and 4. Patient 1 was undergoing oral  $\beta$ -blocker therapy when episodes of VF occurred. Overdrive pacing at a cycle length of 500 ms suppressed VPBs and VF temporarily in patients 2 through 4. When the pacing rate was reduced, VPBs recurred immediately. Suppression of VPBs by pacing allowed for acute stabilization and transportation of the patients to the electrophysiological laboratory. Adenosine temporarily suppressed VPBs in patient 1 for a few seconds.

All patients were sedated with midazolam and fentanyl and were mechanically ventilated. Patients 2 through 4 required catecholamine



**Figure 1.** Twelve-lead surface ECGs of VPBs initiating ventricular tachyarrhythmias. Left, ECG of patient 2. First beat is atrial paced beat, followed by VPB that initiates VF. Atrial paced beat has left to inferior axis and no R wave in V<sub>1</sub> through V<sub>4</sub> owing to anterior infarction in this patient. VPB shows right-axis deviation and RBBB pattern with QRS duration of 150 ms. Right, ECG of patient 3. First beat is atrial sensed and ventricular paced beat. Therefore, it reveals left bundle-branch block pattern with left superior axis. VPB has left superior axis with RBBB pattern, which indicates fast VT. Note changes in morphology of first and second VPBs during initiation of fast monomorphic VTs.

infusion (norepinephrine, in a blood pressure-adjusted dose) for hemodynamic support.

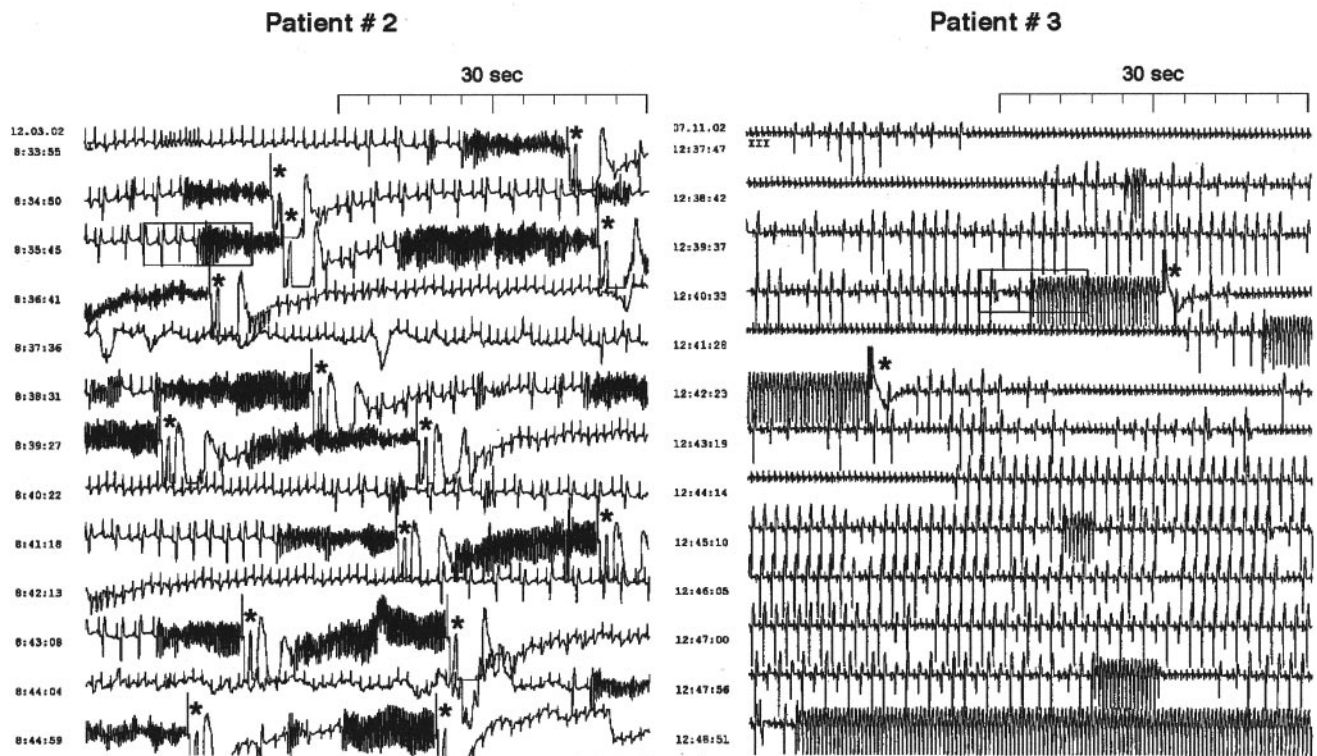
All patients underwent angiography again to exclude reocclusion of a coronary artery. When reocclusion of a coronary artery as a cause of recurrent episodes of VF was excluded and the life-threatening condition remained in all patients despite antiarrhythmic drug therapy, all patients were transferred to the electrophysiological laboratory to attempt catheter ablation of the VPBs triggering the ventricular tachyarrhythmias.

During transportation to the electrophysiological laboratory, patient 4 had a generalized seizure for the first time and received

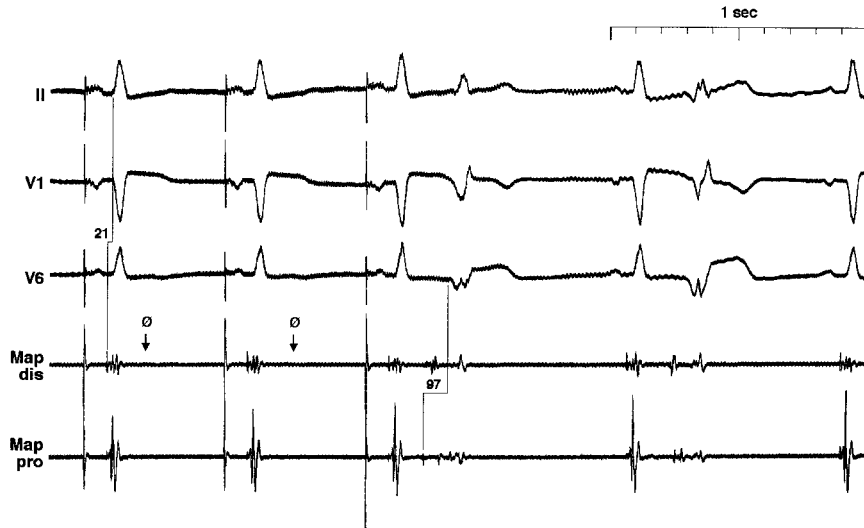
phenytoin at a dose of 20 mg · kg<sup>-1</sup> · min<sup>-1</sup> up to a cumulative dose of 800 mg, which also suppressed the VPBs.

**Methods**

Multipolar catheters were positioned from the femoral veins into the right atrium and at the His bundle. Left ventricular mapping was performed with a 7F, 4-mm-tip electrode (Biosense-Webster Inc) via a retrograde transaortic approach in patients 1, 2, and 4. The approach was both retrograde and transseptal in patient 3



**Figure 2.** Holter ECG of VPBs initiating ventricular tachyarrhythmias. Left, Holter ECG of patient 2 with multiple VPBs that initiated episodes of VF that required repeated external defibrillation (\*) at third day after MI. Right, Holter ECG of patient 3 at fourth day after coronary intervention, showing many VPBs that initiated fast sustained and nonsustained monomorphic VTs (cycle length 220 to 250 ms). Cardioversions are marked with asterisk.



**Figure 3.** Intracardiac electrogram during VPBs in patient 2. This figure shows leads II, V<sub>1</sub>, and V<sub>6</sub> and intracardiac electrograms from distal (Map dis) and proximal (Map pro) mapping catheter at successful ablation site. No diastolic potential is visible after first 2 atrial paced beats (d). Small, high-frequency potential precedes VPB after third atrial paced beat by 97 ms. Note discrete differences in QRS morphology and activation time during first and second VPBs. During first local VPB, activation is recorded in proximal mapping electrode, whereas in second VPB, earliest high-frequency potential is recorded in distal mapping electrode.

because of significant kinking of the aorta. Bipolar electrograms were recorded at a filter setting of 30 to 400 Hz.

Pace mapping was attempted to identify the origin of the VPBs in the LV in all patients (Figure 6). In addition, earliest endocardial activation of VPBs was used as a target for RF ablation in patients 1, 2, and 3. RF current was applied for a maximum of 120 seconds, with temperature limited to 55°C and maximum power limited to 50 W.

**Results**

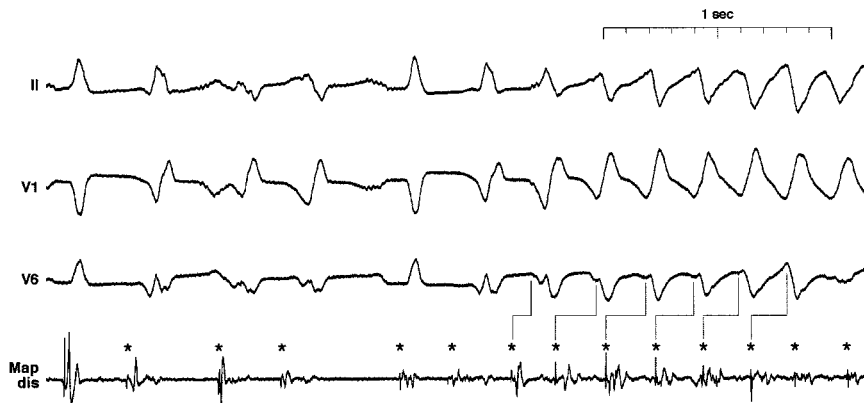
Mapping of clinical VPBs demonstrated earliest activation in the anteromedial LV in patient 2 and the inferomedial LV in patients 1 and 3 at the anatomical border of the MI. At these sites, short, high-frequency, low-amplitude potentials preceded each extrasystole by a maximum of 126 to 160 ms (Figures 3 through 5; Table). Activation times between these potentials and the VPBs varied from beat to beat (Figures 3 through 5). In patient 3, concealed conduction was observed, ie, local potentials were not followed by myocardial activation (Figure 5).

During sinus rhythm and atrial pacing, Purkinje potentials were found at the origin of the VPBs that preceded onset of the QRS complex by 23 to 26 ms (Figure 3). During the electrophysiological study, patients 2 through 4 had 9 episodes, 6 episodes, and 1 episode of triggered VF or VT, respectively. Before initiation of VF and VT, local potentials preceded ventricular activation for the first few tachycardia beats (Figure 4). Then the local potential followed ventricular

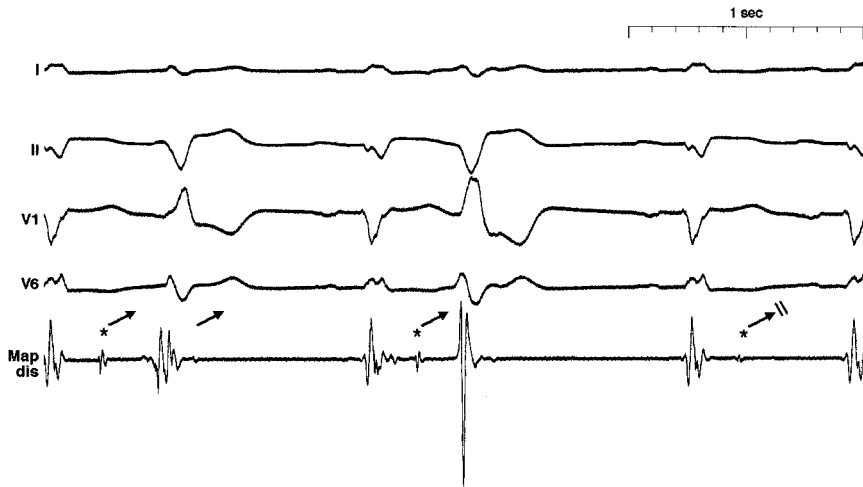
activation in a random order. The QRS morphology during the first few tachycardia beats also resembled the initial beat (Figure 4).

Pace mapping at sites with a QRS morphology similar to the VPBs showed a stimulus-to-ventricular activation interval between 0 and 50 ms. A high pacing output was necessary to capture local myocardium (Figure 6). The stimulus-to-QRS time was shorter than the local potential-to-QRS time, which indicates that separate capture of the local potential was not possible. In patient 4, no spontaneous VPB occurred except for 1 VPB that initiated 1 episode of VF, although 5000 VPBs were documented during a 24-hour Holter ECG before the ablation procedure. This was possibly due to the high dose of phenytoin the patient received for a seizure just before the electrophysiological study. Therefore, only pace mapping was attempted and compared with previously documented 12-lead ECGs of the VPBs. Areas with a QRS morphology similar to the VPBs and local Purkinje potentials during sinus rhythm were identified and used as a target for RF ablation.

In patients 1, 2, and 3, 6 to 21 RF applications at the sites of earliest activation and identical pace maps were needed to suppress the VPBs. In patient 4, Purkinje potentials in areas with a pace map similar to previously documented 12-lead ECGs were ablated with 10 RF applications in the anteromedial LV and 20 RF applications in the inferomedial LV. No



**Figure 4.** Local electrogram during VF initiation in patient 2. First beat is atrial paced beat with Purkinje potential that precedes ventricular activation. Second beat is VPB that is preceded by sharp, high-frequency potential. Third beat is probably fusion beat, fourth again is VPB followed by atrial paced beat. Subsequent VPBs induce VF. Initially, Purkinje potentials appear to drive the ventricle, inducing VT, which finally degenerates into VF. Note changes in activation time and morphology. \*Purkinje potentials during sinus rhythm, before premature beats, and during VF initiation. Map dis indicates distal mapping catheter.



**Figure 5.** Concealed conduction in patient 3. This figure shows 3 ventricular paced beats. Therefore, no Purkinje potential precedes local activation. Two Purkinje potentials after first 2 paced beats cause ventricular premature contractions; no contraction can be noted after third Purkinje potential. Note reduction of Purkinje potential during concealed conduction, which may be caused by mechanical block with mapping catheter. Map dis indicates distal mapping catheter.

conduction abnormalities were noted at the end of the ablation procedures in any patient.

**Follow-Up**

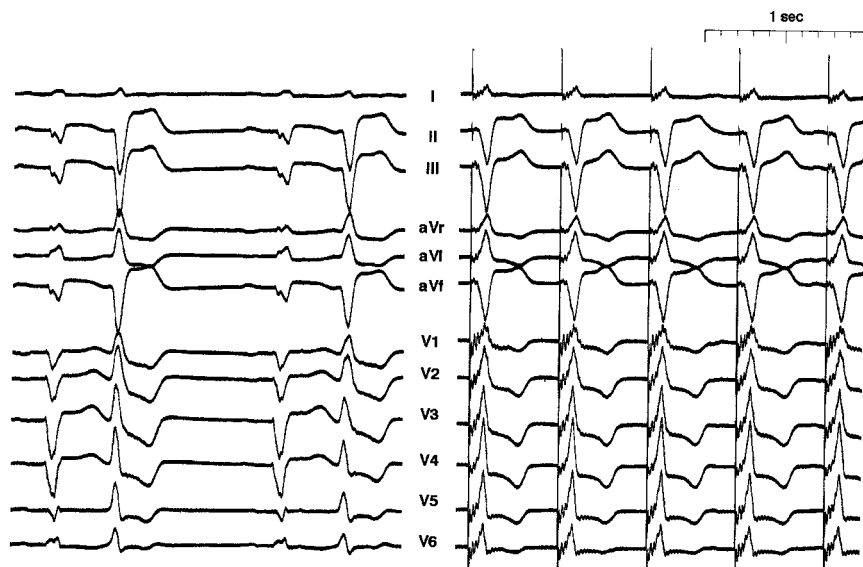
After the ablation procedure, all patients were brought back to the intensive care unit. Antiarrhythmic drugs were withdrawn in patients 1, 2, and 4; patient 3 continued to receive amiodarone (200 mg/d) for intermittent atrial fibrillation. All patients continued to receive  $\beta$ -blockers (metoprolol 100 to 200 mg/d). Patients 1, 2, and 4 received implantable defibrillators because of impaired LV function. Patient 3 did not receive a defibrillator owing to extensive comorbidity. All patients have survived free of any ventricular tachyarrhythmia for 33, 14, 6, and 5 months, respectively.

**Discussion**

We report on 4 patients with incessant VF and VT triggered by monomorphic VPBs after MI, which could not be controlled despite successful reperfusion, intravenous amiodarone, and  $\beta$ -blocker therapy. In all patients, electrical instability persisted for as long as 2 to 11 days until catheter ablation was attempted. Although ventricular R-on-T ectopies

are well known to initiate VF after MI,<sup>7</sup> we could demonstrate for the first time that RF ablation of the VPBs can prevent VF and VT recurrence in these patients, similar to patients with no apparent heart disease.<sup>8,9</sup>

During activation mapping, local sharp, high-frequency, low-amplitude potentials preceded each ventricular extrasystole by a maximum of 126 to 160 ms. Activation times varied between different VPBs, but these potentials were always found in a defined region close to the anatomic border of the infarction. At the same place, a Purkinje potential was observed during sinus rhythm, preceding the QRS complex by 23 to 26 ms. Similarly, the initial beats of VTs in animal models of acute ischemia were recorded from Purkinje fibers situated close to the ischemic border zone of the infarction.<sup>10,11</sup> Although gross ischemia due to reocclusion of a main coronary artery was excluded, time to reperfusion had been prolonged in all 4 patients, and regional ischemia may have persisted. Purkinje fibers are more resistant to ischemia than myocardial cells,<sup>12,13</sup> and endocardial Purkinje fibers may be nourished from cavity blood.<sup>14</sup> This may be sufficient to keep them structurally intact even though function may be impaired, giving rise to afterdepolarization and triggered activity.



**Figure 6.** VPBs and pacing map in patient 3. Left, VPBs; right, pacing map at effective ablation site. Distortion of initial QRS complexes, especially in leads V<sub>1</sub> through V<sub>6</sub>, was caused by high pacing output needed to capture both Purkinje fibers and myocardium. Time between stimulus and QRS onset was 40 to 50 ms, which indicates that isolated capture of Purkinje fibers was not possible.

In contrast to the patients in the present study, activation time between Purkinje fibers and ventricular muscle has been reported to be much shorter in patients without structural heart disease during sinus rhythm ( $11 \pm 5$  ms) and premature beats ( $38 \pm 28$  ms).<sup>8</sup> This may be related to a conduction delay between Purkinje fibers and myocardial tissue<sup>15,16</sup> or may be because myocardial cells close to the Purkinje fibers may be the origin of the VPBs. This may also account for the changes in morphology and width of the VPBs, which were wider than expected for VPBs originating from Purkinje fibers in normal hearts.

Overdrive pacing at a rate of  $\approx 120$  bpm suppressed VPBs and VF only for the time of pacing in 3 patients. When the pacing rate was reduced, VPBs recurred immediately. Adenosine suppressed VPBs in 1 patient for a few seconds, high-dose phenytoin for a few hours. These findings favor triggered activity as the underlying mechanism of the VPBs<sup>14,17,18</sup> and are in accordance with the recording of afterdepolarizations of Purkinje fibers demonstrated in animal models of acute ischemia.<sup>14,19–22</sup> Microreentry in small parts of the Purkinje network as the underlying mechanism of the VPBs, as has been suggested by Janse and Kleber,<sup>23</sup> cannot be excluded, because detailed mapping and entrainment studies were impossible in those fast and unstable VTs. At least the first tachycardia beats appeared to be triggered by local potentials, whereas later, local fibers were bystanders or were passively activated (Figure 4).

The most important clinical finding was that similar to patients without structural heart disease, catheter ablation of the VPBs could cure an electrical storm and prevent the recurrence of any sustained ventricular tachyarrhythmias even in patients after acute MI.<sup>1</sup> A considerable number of RF applications ( $n=6$  to 30) were necessary to abolish local Purkinje potentials and suppress VPBs, which suggests that the triggering fibers covered an extensive area at the border zone of the infarction and may have various connections to the surrounding tissue.

No episode of ventricular tachyarrhythmia has recurred in any of the patients to date, which is striking given the high number of episodes of VTs. This finding, however, is in line with the benign course of patients once they have survived the electrical storm.<sup>1</sup> This may indicate that in these patients, the triggering fibers finally die because of ischemia or regain normal function. Because antiarrhythmic drug therapy with amiodarone and sympathetic blockade leaves some patients unstable, or the time to stabilization may be prolonged, especially with amiodarone,<sup>1,6</sup> catheter ablation of the triggering VPBs should be used as a bailout therapy in patients with an electrical storm after MI.

### Conclusions

Incessant ventricular tachyarrhythmias after MI may be triggered by VPBs. RF ablation of the triggering VPBs is feasible and can prevent drug-resistant electrical storm even in patients after acute MI. Therefore, catheter ablation of the triggering VPBs may be used as a bailout therapy in these patients.

### Acknowledgment

We thank Michel Haissaguerre, Bordeaux, who transferred the data of 1 case from Jesus Val-Mejias, Wichita, Kansas, to us for inclusion of this patient in our series.

### References

- Nademanee K, Taylor R, Bailey WE, et al. Treating electrical storm: sympathetic blockade versus advanced cardiac life support-guided therapy. *Circulation*. 2000;102:742–747.
- Dorian P, Cass D. An overview of the management of electrical storm. *Can J Cardiol*. 1997;13(suppl A):13A–17A.
- Somberg JC, Bailin SJ, Haffajee CI, et al. Intravenous lidocaine versus intravenous amiodarone (in a new aqueous formulation) for incessant ventricular tachycardia. *Am J Cardiol*. 2002;90:853–859.
- Kowey PR. An overview of antiarrhythmic drug management of electrical storm. *Can J Cardiol*. 1996;12:3B–8B.
- Somberg JC, Bailin SJ, Haffajee CI, et al. Intravenous lidocaine versus intravenous amiodarone (in a new aqueous formulation) for incessant ventricular tachycardia. *Am J Cardiol*. 2002;90:853–859.
- Russo AM, Beauregard LM, Waxman HL. Oral amiodarone loading for the rapid treatment of frequent, refractory, sustained ventricular arrhythmias associated with coronary artery disease. *Am J Cardiol*. 1993;72:18–19.
- Maggioni AP, Zuanetti G, Franzosi MG, et al. Prevalence and prognostic significance of ventricular arrhythmias after acute myocardial infarction in the fibrinolytic era: GISSI-2 results. *Circulation*. 1993;87:2–22.
- Haissaguerre M, Shoda M, Jais P, et al. Mapping and ablation of idiopathic ventricular fibrillation. *Circulation*. 2002;106:962–967.
- Haissaguerre M, Shah DC, Jais P, et al. Role of Purkinje conducting system in triggering of idiopathic ventricular fibrillation. *Lancet*. 2002;359:677–678.
- Janse MJ, van Capelle FJ, Morsink H, et al. Flow of “injury” current and patterns of excitation during early ventricular arrhythmias in acute regional myocardial ischemia in isolated porcine and canine hearts: evidence for two different arrhythmogenic mechanisms. *Circ Res*. 1980;47:151–165.
- Janse MJ, Morena H, Cinca J, et al. Electrophysiological, metabolic and morphological aspects of acute myocardial ischemia in the isolated in the isolated porcine heart: characterization of the “border zone.” *J Physiol (Paris)*. 1980;76:785–790.
- Cha YM, Uchida T, Wolf PL, et al. Effects of chemical subendocardial ablation on activation rate gradient during ventricular fibrillation. *Am J Physiol*. 1995;269:H1998–H2009.
- Friedman PL, Stewart JR, Wit AL. Spontaneous and induced cardiac arrhythmias in subendocardial Purkinje fibers surviving extensive myocardial infarction in dogs. *Circ Res*. 1973;33:612–626.
- Arnar DO, Bulling JR, Martins JB. Role of the Purkinje system in spontaneous ventricular tachycardia during acute ischemia in a canine model. *Circulation*. 1997;96:2421–2429.
- Kawara T, Derksen R, de Groot JR, et al. Activation delay after premature stimulation in chronically diseased human myocardium relates to the architecture of interstitial fibrosis. *Circulation*. 2001;104:3069–3075.
- Cascio WE, Yang H, Johnson TA, et al. Electrical properties and conduction in reperfused papillary muscle. *Circ Res*. 2001;89:807–814.
- Rozanski GJ, Witt RC. Early afterdepolarizations and triggered activity in rabbit cardiac Purkinje fibers recovering from ischemic-like conditions: role of acidosis. *Circulation*. 1991;83:1352–1360.
- Boachie-Ansah G, Kane KA, Parratt JR. Electrophysiological effects of adenosine and adenosine triphosphate on sheep Purkinje fibres under normal and simulated ischaemic conditions. *Br J Pharmacol*. 1989;97:240–246.
- Mohabir R, Ferrier GR. Effects of verapamil and nifedipine on mechanisms of arrhythmia in an in vitro model of ischemia and reperfusion. *J Cardiovasc Pharmacol*. 1991;17:74–82.
- Rozanski GJ, Witt RC. Alterations in repolarization of cardiac Purkinje fibers recovering from ischemic-like conditions: genesis of early afterdepolarizations. *J Cardiovasc Electrophysiol*. 1993;4:134–143.
- Vera Z, Pride HP, Zipes DP. Reperfusion arrhythmias: role of early afterdepolarizations studied by monophasic action potential recordings in the intact canine heart during autonomically denervated and stimulated states. *J Cardiovasc Electrophysiol*. 1995;6:7–43.
- Molina-Viamonte V, Anyukhovskiy EP, Rosen MR. An alpha-1-adrenergic receptor subtype is responsible for delayed afterdepolarizations and triggered activity during simulated ischemia and reperfusion of isolated canine Purkinje fibers. *Circulation*. 1991;84:1732–1740.
- Janse MJ, Kleber AG. Electrophysiological changes and ventricular arrhythmias in the early phase of regional myocardial ischemia. *Circ Res*. 1981;49:1069–1081.