

AHA SCIENTIFIC STATEMENT

Evaluation and Management of Right-Sided Heart Failure

A Scientific Statement From the American Heart Association

Endorsed by the Heart Failure Society of America and International Society for Heart and Lung Transplantation

BACKGROUND AND PURPOSE: The diverse causes of right-sided heart failure (RHF) include, among others, primary cardiomyopathies with right ventricular (RV) involvement, RV ischemia and infarction, volume loading caused by cardiac lesions associated with congenital heart disease and valvular pathologies, and pressure loading resulting from pulmonic stenosis or pulmonary hypertension from a variety of causes, including left-sided heart disease. Progressive RV dysfunction in these disease states is associated with increased morbidity and mortality. The purpose of this scientific statement is to provide guidance on the assessment and management of RHF.

METHODS: The writing group used systematic literature reviews, published translational and clinical studies, clinical practice guidelines, and expert opinion/statements to summarize existing evidence and to identify areas of inadequacy requiring future research. The panel reviewed the most relevant adult medical literature excluding routine laboratory tests using MEDLINE, EMBASE, and Web of Science through September 2017. The document is organized and classified according to the American Heart Association to provide specific suggestions, considerations, or reference to contemporary clinical practice recommendations.

RESULTS: Chronic RHF is associated with decreased exercise tolerance, poor functional capacity, decreased cardiac output and progressive end-organ damage (caused by a combination of end-organ venous congestion and underperfusion), and cachexia resulting from poor absorption of nutrients, as well as a systemic proinflammatory state. It is the principal cause of death in patients with pulmonary arterial hypertension. Similarly, acute RHF is associated with hemodynamic instability and is the primary cause of death in patients presenting with massive pulmonary embolism, RV myocardial infarction, and postcardiotomy shock associated with cardiac surgery. Functional assessment of the right side of the heart can be hindered by its complex geometry. Multiple hemodynamic and biochemical markers are associated with worsening RHF and can serve to guide clinical assessment and therapeutic decision making. Pharmacological and mechanical interventions targeting isolated acute and chronic RHF have not been well investigated. Specific therapies promoting stabilization and recovery of RV function are lacking.

CONCLUSIONS: RHF is a complex syndrome including diverse causes, pathways, and pathological processes. In this scientific statement, we review the causes and epidemiology of RV dysfunction and the pathophysiology of acute and chronic RHF and provide guidance for the management of the associated conditions leading to and caused by RHF.

Marvin A. Konstam, MD,
Chair
Michael S. Kiernan, MD,
MS, FAHA, Co-Chair
Daniel Bernstein, MD
Biyykem Bozkurt, MD, PhD,
FAHA
Miriam Jacob, MD
Navin K. Kapur, MD
Robb D. Kociol, MD, MS
Eldrin F. Lewis, MD, MPH,
FAHA
Mandeep R. Mehra, MD
Francis D. Pagani, MD,
PhD, FAHA
Amish N. Raval, MD,
FAHA
Carey Ward, MD
On behalf of the American
Heart Association Council on Clinical Cardiology;
Council on Cardiovascular Disease in the
Young; and Council on
Cardiovascular Surgery
and Anesthesia

Key Words: AHA Scientific Statements
■ causality ■ disease management
■ heart failure ■ ventricular dysfunction, right

© 2018 American Heart Association, Inc.

<http://circ.ahajournals.org>

Over the years, there have been intermittent surges in interest in and investigation of the right ventricle (RV). One such period was the early 1980s, with the emergence of novel imaging techniques, advanced surgical approaches, enhanced understanding of RV infarction and ischemia, and intense physiological investigation of right-sided hemodynamics and ventricular interdependence. Now, once again, we enjoy intense interest in this area, owing in large part to advanced pharmacology for managing pulmonary hypertension (PH) and a mushrooming of both diagnostic techniques and durable and temporary mechanical circulatory support (MCS) devices, yielding expanded treatment options and enhanced outcomes in patients with acute and chronic disorders of the right side of the heart.

RV dysfunction (RVD), defined here as evidence of abnormal RV structure or function, is associated with poor clinical outcomes independently of the underlying mechanism of disease: across the spectrum of left ventricular (LV) ejection fraction (EF) in patients with acute and chronic heart failure (HF), after cardiac surgery, acute myocardial infarction (MI), congenital heart disease (CHD), and PH. To distinguish right-sided HF (RHF) from structural RVD, we define RHF as a clinical syndrome with signs and symptoms of HF resulting from RVD.¹ RHF is caused by the inability of the RV to support optimal circulation in the presence of adequate preload. This scientific statement provides evidence-based guidance in the following areas: pathophysiology of RVD, assessment and evaluation of RV function, epidemiology and prognosis of RHF, medical and surgical management of acute (ARHF) and chronic RHF (CRHF), and proposed areas for future investigation.

The recommendations and suggestions/considerations listed in this document are, whenever possible, evidence based. An extensive literature review was conducted through May 2017, with references selected as appropriate. Searches were limited to studies, reviews, and other evidence conducted in human subjects and published in English. In addition, the committee reviewed documents related to the subject matter previously published by clinical practice guideline task forces from the American Heart Association (AHA) and American College of Cardiology. References selected and published in this document are representative but not all inclusive. To provide clinicians with a representative evidence base, whenever deemed appropriate or when published, it was felt that critical appraisal of the quality of study be maintained and, whenever possible, robust statistical data be provided.

ORGANIZATION OF THE WRITING COMMITTEE

The committee was composed of physicians with a broad knowledge base in the epidemiology and pathophysiology of HF with expertise in the evaluation, care,

and management of patients with RHF. The authors' expertise included general cardiology, advanced HF and transplantation cardiology, cardiac surgery, interventional cardiology, PH, and CHD; physicians with methodological expertise also were included. The committee included representatives from the AHA Council on Clinical Cardiology, Council on Cardiovascular Disease in the Young, and Council on Cardiovascular Surgery and Anesthesia; the Heart Failure Society of America; and the International Society of Heart and Lung Transplantation.

DOCUMENT REVIEW AND APPROVAL

This document was reviewed by 5 official reviewers, each nominated by the AHA. All information on reviewers' relationships with industry was distributed to the writing committee and is published in this document. This document was approved for publication by the governing bodies of the AHA.

SUGGESTIONS/CONSIDERATIONS AND REFERENCE TO CLINICAL PRACTICE GUIDELINE RECOMMENDATIONS

To make certain that this document is aligned with the appropriate guideline statements but does not preempt those guidelines, the authors have opted to reference evidence-based clinical practice recommendations only and to refer the reader to the most recently published clinical practice guideline statement for more specific alignment with extant guidelines. Suggestions/considerations are included when the evidence does not warrant recommendations but there is still a desire to provide some guidance to the community.

SCOPE OF THIS SCIENTIFIC STATEMENT WITH REFERENCE TO OTHER RELEVANT GUIDELINES OR STATEMENTS

This scientific statement focuses on the evaluation and management of RHF. Some topics may have been reviewed in other clinical practice guidelines and scientific statements published by other working groups, including the American College of Cardiology/AHA task forces. The writing committee saw no need to reiterate the recommendations contained in those guidelines but chose instead to provide current suggestions or considerations for clinical practice and to clarify previous discrepancies if present.

ANATOMY AND EMBRYOLOGY OF THE RV

Several developmental and anatomic features distinguish the RV from the LV.^{2,3} The RV and RV outflow

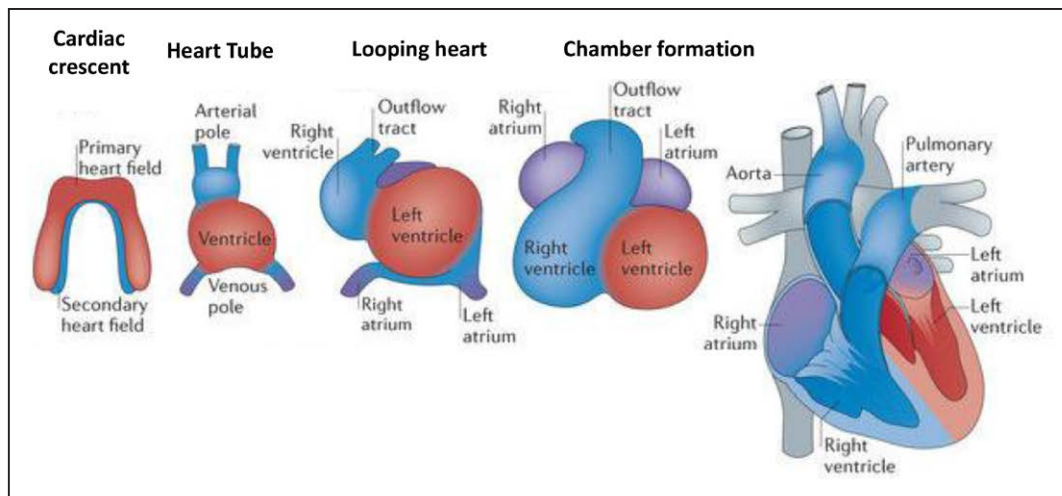


Figure 1. Cardiac embryogenesis.

During embryogenesis, the primary heart field is formed by early cardiac progenitor cells in the anterior mesoderm. The secondary heart field is derived from the pharyngeal mesoderm located medial and anterior to the primary heart field. Cells from the primary heart field migrate to the midline to form a linear heart tube, serving as a scaffold for subsequent heart growth. The heart tube is expanded posteriorly and anteriorly with cells migrating from the secondary heart field, giving rise to the arterial and venous poles. The linear heart tube undergoes a rightward looping, leading to the formation of primitive ventricles and atria. As a result, the venous pole moves anteriorly, positioning the future cardiac chambers for proper development. Heart maturation involves septation formation in the ventricles and atria, as well as valve formation. The primary heart field contributes to the left ventricle and right and left atria. The secondary heart field contributes to the right ventricle, outflow tract, and right and left atria. Cardiac neural crest cells migrating from the dorsal neural tube into the arterial pole participate in separation of the outflow tract. Reprinted by permission from Macmillan Publishers Ltd. Adapted from Xin et al.⁹ *Nature Reviews Molecular Cell Biology*. Copyright © 2013, Macmillan Publishers Ltd.

tracts originate from cells of the secondary (anterior) heart field, whereas the LV and left atria originate from the primary heart field.⁴ The identification of the secondary heart field has provided new insight into the development of congenital heart defects and may lead to discoveries identifying distinct intercellular signaling pathways and transcriptional regulation in response to injury by the RV in contrast to the LV.^{5–8} Beginning in the third week of embryonic development, the primitive heart tube begins beating and undergoes a series of twisting and folding movements to generate a single primitive ventricle that receives blood from a single atrium and ejects blood through a common outflow tube known as the truncus arteriosus (Figure 1).⁹ By the end of the fourth week, a muscular ventricular septum emerges from the floor of the primitive ventricle to form the earliest signs of distinct RVs and LVs. Between the fifth and eighth weeks, ridges within the truncus arteriosus grow into the aorticopulmonary septum, which fuses with the endocardial cushions and muscular interventricular septum to form the membranous septum. At the end of the eighth week, distinct pulmonary and systemic circulations exist. For the remainder of fetal development, the RV will account for ≈60% of total cardiac output (CO), which provides systemic perfusion via the foramen ovale and the ductus arteriosus. At birth, the LV becomes the dominant systemic ventricle while the RV adapts to provide flow through the pul-

monary circulation alone, assuming that the foramen ovale and ductus arteriosus close appropriately.

Anatomically, the RV free wall is thin (2–3 mm) and compliant and forms a hemi-ellipsoid shape that adheres to the LV³ (Figure 2). A large sinus for venous inflow and a tubular outflow tract provide a funnel-like configuration to the heavily trabeculated RV. Unlike the shared annulus of the aortic and mitral valves, the crista supraventricularis is a muscle bridge that is unique to the RV and separates the RV inflow (tricuspid annulus) from the outflow tract (pulmonic annulus). The crista supraventricularis shares muscle fibers with the interventricular septum and the RV free wall and serves to contract the orifice of the tricuspid valve (TV) while pulling the RV free wall toward the interventricular septum during systole.^{10,11}

PHYSIOLOGY OF THE RV

Normal RV function is governed by systemic venous return, PA load (RV afterload), pericardial compliance, and native contractility of the RV free wall and interventricular septum. Generating RV output requires one sixth the energy expenditure of the LV because much of RV stroke work maintains forward momentum of blood flow into a highly compliant, low-resistance pulmonary circulation. This difference is exemplified by the RV pressure-volume (PV) loop, which lacks isovolumic

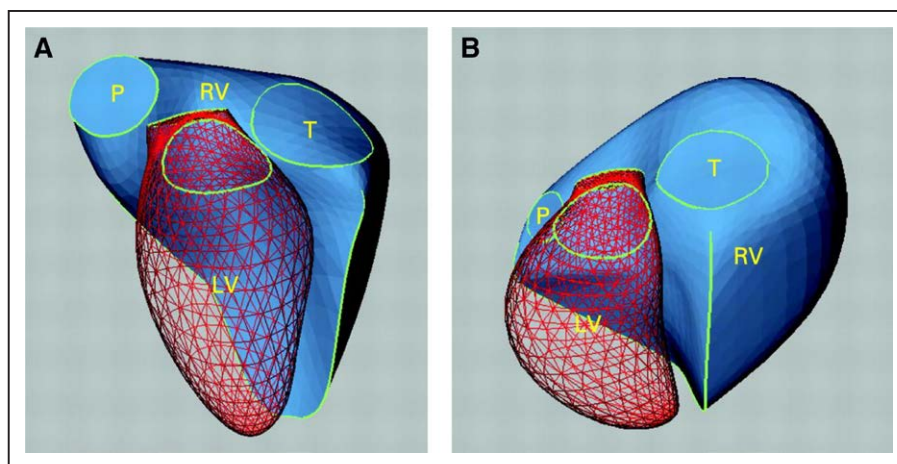


Figure 2. Right ventricular (RV) geometry in health and disease.

Three-dimensional reconstructions of the RV illustrating its complex shape in a normal subject (A). RV remodeling in diseased hearts can result in profound shape change with RV dilation caused by chronic volume or pressure overload (B). The red mesh surface is the left ventricle (LV), and the solid blue surface is the RV. P indicates pulmonary valve; and T, tricuspid valve. Reprinted from Sheehan and Redington³ with permission from BMJ Publishing Group, Ltd. Copyright © 2008, BMJ Publishing Group, Ltd.

phases of contraction and relaxation during systole and diastole, has a lower peak systolic pressure, and exists at a higher steady-state volume compared with the LV.¹² In contrast to the LV, peak RV pressure occurs before the end of systolic ejection, which leads to a more trapezoid-appearing RV PV loop (Figure 3).^{13–15}

Afterload is a primary determinant of normal RV function, and RVEF is inversely proportional to pulmonary artery (PA) pressure (PAP).¹⁶ The RV has a shallower end-systolic PV slope than the LV, which results in lesser change in end-systolic pressure, generating greater change in end-systolic volume.^{17,18} Accordingly, RV systolic function is highly sensitive to changes in afterload, with minor increases in afterload causing large decreases in stroke volume (SV)¹⁹ (Figure 4).²⁰ As dictated by the law of LaPlace, wall stress (afterload) is directly proportional to intracavitary pressure and to internal ventricular diameter and inversely related to ventricular wall thickness. However, regional wall stress may vary widely as a result of the nonspherical RV shape. RV afterload is most appropriately defined as the RV wall stress during systolic ejection estimated by the summation of the resistive and pulsatile components of blood flow.^{21,22} Commonly used measures of RV afterload, including PA systolic pressure (PASP) and pulmonary vascular resistance (PVR), provide an inadequate description of RV afterload because they do not account for contributions of pulsatile loading.²² As blood ejects from the RV into the lungs, antegrade flow away from the pulmonic valve (PV) encounters waves of retrograde flow generated by multiple bifurcations throughout the pulmonary vasculature. This retrograde impedance wave reduces antegrade flow and increases peak PASP.²³

In the setting of left-sided heart (LH) disease, elevations in left atrial pressures lead to lower PA compliance than would be anticipated from elevated PVR alone.^{24,25} Similarly, lowering of pulmonary capillary wedge pressure (PCWP) increases PA compliance more than would be anticipated from a fall in PVR alone.²⁶ Thus, elevated LH filling pressures directly increase RV afterload, secondarily reduce PA compliance, and increase PA resistance through acute vasoconstriction and chronic vascular remodeling.²²

Under steady-state conditions, optimal ventricular efficiency is achieved if end-systolic elastance (E_{es}) is matched by vascular load, defined by arterial elastance^{16,27–31} (Figure 5). The ratio of E_{es} to arterial elastance is known as ventriculo-arterial coupling, a framework to consider contractility in the context of load. The optimal mechanical coupling of RV function to afterload corresponds to a ratio of E_{es} to arterial elastance of 1.0, with uncoupling occurring below a ratio of 0.6 to 1.0.^{16,29,30} When PASP increases acutely, RV SV decreases significantly and arterial elastance increases out of proportion to E_{es} . As a result, RV function becomes inefficient, and more energy is expended to maintain adequate RV output. In contrast, an increase in aortic systolic pressure results in smaller decreases in LV SV, thereby maintaining a near-normal ventriculo-arterial coupling ratio.

Unlike the predominantly diastolic coronary flow of the LV, normal RV coronary perfusion occurs during both systole and diastole. The pressure-overloaded RV is at increased risk for developing ischemia as a result of decreased perfusion pressure in the setting of increased RV intramural pressure and decreased systemic arterial pressure.^{32,33} Any process that increases RV

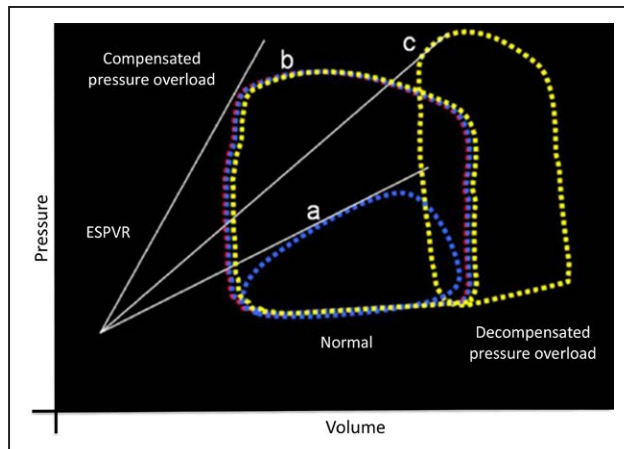


Figure 3. Right ventricular (RV) pressure-volume (PV) loops.

RV PV loops obtained by a conductance catheter. White solid lines reflect the end-systolic PV relationships (ESPVR) of a series of loops generated by varying the loading conditions. The slope of ESPVR line reflects the RV end-systolic elastance (E_{es}). A steeper slope represents higher E_{es} . Loop a depicts a normal RV PV loop. A lower proportion of RV stroke work goes to pressure generation, with a higher proportion going to blood momentum. In the normal state, in contrast to the left ventricle (LV), there is a relative absence of RV isovolemic periods. The high momentum of blood ejecting from the RV into the low-pressure pulmonary circulation results in continued RV ejection after LV systolic ejection has ended into RV relaxation. Loop b represents a compensated, chronically hypertensive RV. Loop c is obtained from a decompensated hypertensive RV. Note the decrease in RV E_{es} from the compensated RV depicted in loop b to the decompensated RV depicted by loop c. Reproduced from Friedberg and Redington¹³ with permission. Copyright © 2014, American Heart Association.

end-diastolic pressure leads to decreased RV coronary blood flow and has the potential to induce subendocardial ischemia.

PATHOPHYSIOLOGY OF RHF

Acute RHF

ARHF can occur because of abruptly increased RV afterload (pulmonary embolus, hypoxia, acidemia) or decreased RV contractility (RV ischemia, myocarditis, post-cardiotomy shock). Each condition represents a unique hemodynamic challenge for the RV. The RV is coupled to the high-compliance, low-resistance pulmonary circulation and is suited to adapt to changes in volume rather than pressure.² In a healthy individual, PVR is $<1/10$ th of the systemic vascular resistance. In contrast, the LV is coupled to the lower-compliance, higher-resistance systemic arterial circulation and adapts better to changes in pressure than volume. Thus, an acute increase in RV afterload such as can result from a large

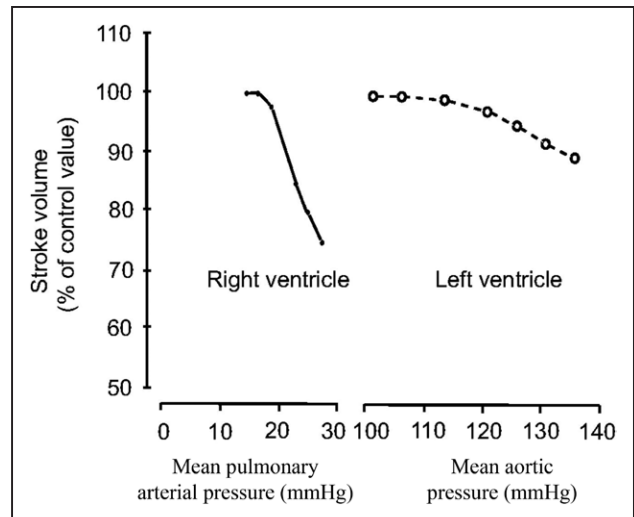


Figure 4. Relationship of right ventricular (RV) and left ventricular (LV) stroke volumes to increases in afterload.

Response of the RV and LV to an experimental increase in afterload. Note the comparatively steep decline in stroke volume associated with increases in pressure compared with the smaller reductions seen in LV stroke volume associated with similar pressure increments. Reprinted with permission of the American Thoracic Society. Copyright © 2018, American Thoracic Society. MacNee W. Pathophysiology of cor pulmonale in chronic obstructive pulmonary disease: part one. *Am J Respir Crit Care Med*. 1994;150:883–852.²⁰ The *American Journal of Respiratory and Critical Care Medicine* is an official journal of the American Thoracic Society.

pulmonary embolism (PE) may abruptly decrease RV SV, with minimal increase in RV systolic pressure.

Acute reductions in RV contractility may also be caused by direct myocardial injury from mechanisms such as myocardial inflammation (myocarditis) and ischemia. Reduced RV SV results in RV dilation, which promotes tricuspid regurgitation (TR), exacerbates RV dilation, and drives a ventricular-interdependent effect on LV filling. Ventricular interdependence is defined as the forces directly transmitted from one ventricle to the other through the myocardium and pericardium.¹⁶ Mechanical flattening with a leftward shift of the interventricular septum increases LV end-diastolic pressure, reduces LV transmural filling pressure, and impedes LV diastolic filling, contributing to systemic hypoperfusion¹⁸ (Figure 6). Diastolic interaction is described as ventricular competition for diastolic distension/filling within an acutely confined pericardial space. Systolic interactions also exist because it is estimated that 20% to 40% of RV systolic pressure results from LV contraction.^{3,34}

Elevated filling pressures of the right side of the heart also cause coronary sinus congestion, which reduces coronary blood flow and can provoke RV ischemia.^{35,36} High right-sided filling pressure with systemic

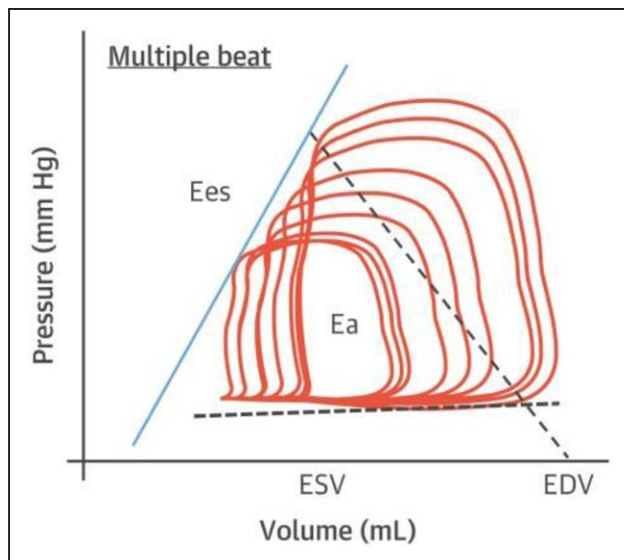


Figure 5. Pressure-volume (PV) loop.

Right ventricular–pulmonary arterial (RV-PA) coupling. The PV loop is a comprehensive description of the relationship between pressure and volume during the cardiac cycle. The area within the loop defines the stroke work of the RV, with the width of the loop representing stroke volume (SV). End-systolic elastance (Ees), a load-independent measure of contractility, is determined by a tangent fitted on the end-systolic portions of a family of PV. RV afterload is determined by dividing the end-systolic pressure by the SV, providing the effective arterial elastance (Ea). Ea is measured as the slope of a straight line drawn from the end-systolic to end-diastolic PV relationship (to end-diastolic volume [EDV] at $P=0$). The relationship of these 2 parameters (Ees:Ea) provides a ratio defining RV-PA coupling, which reflects contractility in the context of afterload. Determinations of Ees and Ea require instantaneous measurements of RV pressure and volume to generate sequential PV loops obtained by a decrease of venous return via stepwise inflation of an inferior vena cava balloon or a Valsalva maneuver. Reprinted from Guazzi and Naeije¹⁶ with permission from Elsevier. Copyright © 2017, Elsevier.

venous congestion also negatively affects hepatic and renal function, aggravating further fluid retention and worsening RHF.

Chronic RHF

CRHF most commonly results from gradual increases in RV afterload caused by PH most frequently from LH failure (LHF), although chronic volume overload from right-sided lesions such as TR can also lead to its development (Figure 7). Long-standing pressure or volume overload imposed on the RV initially promotes compensatory myocyte hypertrophy and fibrosis analogous to the remodeling that occurs in LHF. If the load persists, then the RV transitions from a compensated to decompensated phenotype characterized by myocyte loss and replacement/fibrosis.³⁷

During the initial compensated phase, the hypertrophied RV begins to develop isovolumic phases of contraction and relaxation with increased RV systolic pressure and higher end-diastolic volume (Figure 3). In the decompensating phase, there is a concomitant rise in PVR and right atrial (RA) pressure (RAP). While PVR remains persistently elevated, CO subsequently declines, followed by a reduction in PAP^{18,38} (Figure 8). Declining PAP in the setting of high PVR is an ominous clinical finding.

In the presence of an intact pericardium, RV dilation eventually compresses the LV cavity, impeding LV filling and equalizing biventricular diastolic pressures (Figure 6). Although it is true that patients with CRHF may require higher RV end-diastolic pressure (preload), reduced LH filling is more likely caused by RV dilation and ventricular interdependence than reduced RV forward output.³⁹ That is, increased transmural pressure caused by RV dilation with pericardial constraint impairs LV filling (preload). The combination of RV systolic and biventricular diastolic dysfunction reduces CO, impairs coronary blood flow, and exacerbates peripheral and abdominal congestion.

EPIDEMIOLOGY AND PATHOGENESIS OF RHF

HF With Reduced EF

Progressive RHF was first described as a component of the HF clinical syndrome in 1910.⁴⁰ Regardless of pathogenesis, RVD increases in prevalence with more advanced LHF. In this setting, RVD may occur secondary to increased RV afterload from postcapillary PH, volume overload, arrhythmias, or the underlying myocardial disease process affecting the LV (Table 1). The last factor may contribute to the higher prevalence of RVD observed in nonischemic dilated cardiomyopathy compared with ischemic cardiomyopathy, especially given the possible genetic predisposition in many of these patients. The overall prevalence of RVD in HF with reduced EF (HFrEF) varies widely with distinct differences in varied populations, but its presence is universally associated with increased mortality.⁴¹ The prevalence of RVD in a meta-analysis of patients with HFrEF was 48%.⁴¹ In a small cohort of patients with dilated cardiomyopathy, RVD was seen in ≈60% of patients and was associated with greater mitral regurgitation and TR, more rapid progression of clinical HF, and decreased survival.⁴² Likewise, in a separate series, patients with nonischemic dilated cardiomyopathy had a higher proportion of RVD than those with an ischemic pathogenesis: 65% versus 16%.⁴³ Among patients with HFrEF who underwent echocardiography during acute HF hospitalization, 48% had RVD. These patients had a 2.4-fold increased risk of mortality, urgent transplanta-

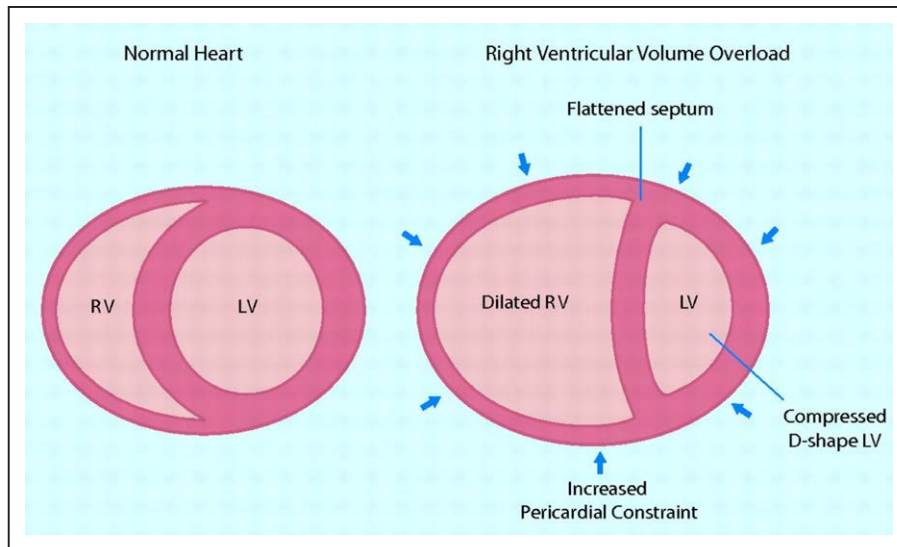


Figure 6. Ventricular interdependence in right-sided heart failure.

Pathological increases in right ventricular (RV) filling pressures are transmitted to the interventricular septum. As the RV is constrained by the pericardium (arrows), these forces result in leftward shift of the septum, altering left ventricular (LV) geometry. These changes contribute to reduced cardiac output by decreasing LV distensibility, preload, and ventricular elastance, adversely affecting LV diastolic filling. Leftward septal shift secondary to pericardial constraint from elevated RV end-diastolic pressure distorts the normal geometric ventricular relationship, also impairing RV contractile function. Adapted from Haddad et al¹⁸ with permission. Copyright © 2008, American Heart Association.

tion, or urgent LV assist device (LVAD) placement at 90 days compared with those without RVD.⁴⁴

RVD is also associated with decreased exercise capacity measured by peak oxygen consumption and worse New York Heart Association functional class.⁴⁵ In a study of 97 patients with HFrEF, RV exercise con-

tractile reserve and RV-PA coupling were assessed with tricuspid annular plane systolic excursion (TAPSE) versus PASP and the slope of mean PAP versus CO.⁴⁶ Patients were grouped according to whether their resting TAPSE was ≥ 16 mm. Those with TAPSE < 16 mm were further subdivided by whether TAPSE at peak

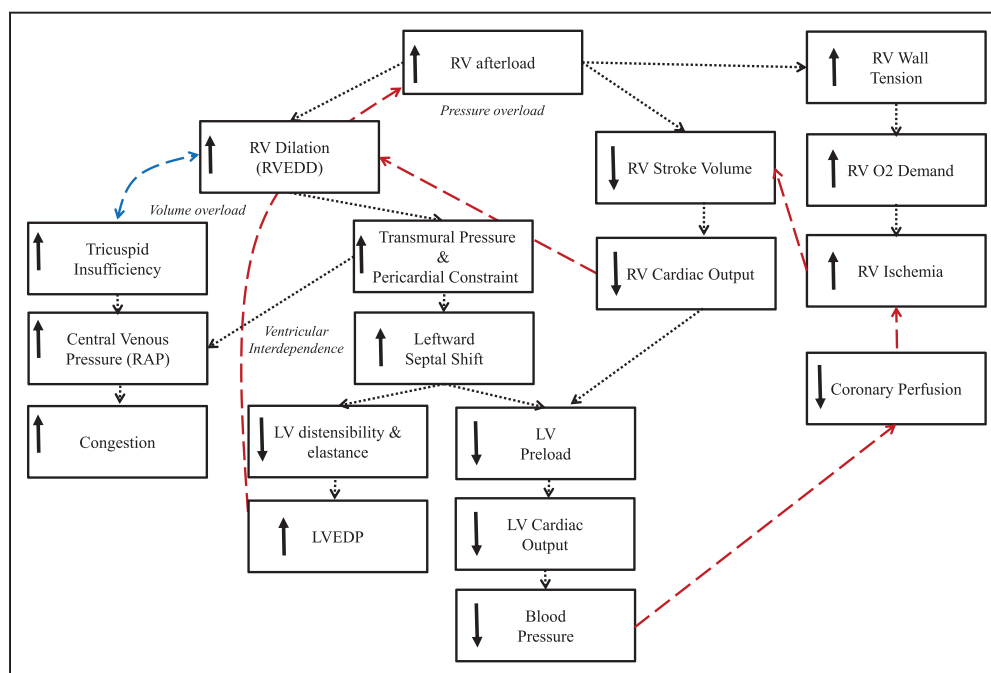


Figure 7. Pathophysiology of right-sided heart failure.

LV indicates left ventricular; LVEDP, left ventricular end-diastolic pressure; RAP, right atrial pressure; RV, right ventricle; and RVEDD, right ventricular end-diastolic dimension.

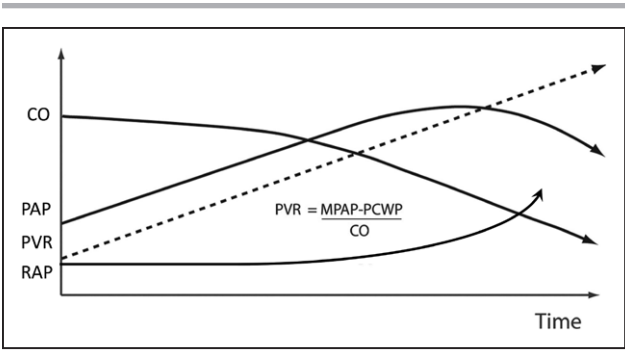


Figure 8. Hemodynamics in progressive pulmonary vascular disease.
A decrease in pulmonary arterial pressure (PAP) in patients with pulmonary hypertension may be a sign of low cardiac output (CO) and severe right ventricular dysfunction. MPAP indicates mean PAP; PCWP, pulmonary artery capillary wedge pressure; PVR, pulmonary vascular resistance; and RAP, right atrial pressure. Adapted from Haddad et al¹⁸ with permission. Copyright © 2008, American Heart Association.

exercise was ≥ 15.5 mm. Although patients had similar baseline profiles of biventricular function, those with higher TAPSE in response to exercise demonstrated improved RV contractile reserve and some degree of favorable RV-PA coupling in contrast to those patients with persistently low TAPSE. Thus, many patients with resting RVD can have residual contractile reserve with the ability to improve RV-PA coupling during exercise. Data directly linking RVD to reduced performance on structured health-related quality of life (HRQoL) questionnaires are sparse.

HF With Preserved EF

RV function is equally important in patients with HF with preserved EF (HFpEF). In this population, however, it is difficult to distinguish primary RV pathology from that resulting from secondary PH, given the afterload dependency of RV function.⁴⁷ Nevertheless, several small cohort studies have evaluated the prevalence of concomitant RV systolic dysfunction in the setting of HFpEF. In a Mayo Clinic cohort, 33% of patients with HFpEF had RVD defined as RV fractional area change (RVFAC) $<35\%$.⁴⁸ In a separate study of 51 patients, depending on the criteria used, RVD was present in 33% to 50% of patients with HFpEF in contrast to 63% to 76% of those with HFrEF.⁴⁹ Other groups have reported similar findings.⁵⁰ A meta-analysis including 4835 patients reported varied prevalence depending partly on the modality used to assess RV function: 31% by TAPSE, 26% by RV S', and 13% by RVFAC.⁴⁷ Approximately 70% of these patients with HFpEF with RVD had concomitant PH at rest. More novel indexes of RV function have led to higher prevalence estimates. RV longitudinal systolic strain abnormalities were identified in 75% of 208 patients with HFpEF, whereas RVFAC $<35\%$ was seen in only 28%.⁵¹ Compared with patients with HFpEF without RVD, those with RVD were more likely to be male, to have more renal impairment, and to have a higher prevalence of atrial fibrillation and coronary artery disease.^{48,51}

Analogous to outcomes in HFrEF populations, RVD is associated with increased morbidity and mortality in HFpEF populations.⁵¹ Two-year mortality in 1 study was $\approx 45\%$ for patients with RVD compared with 7%

Table 1. Causes of RHF

	Decreased RV Contractility	RV Volume Overload	RV Pressure Overload
Acute	Sepsis		Acidosis
	LVAD support		Hypoxia
	RVMI	Excessive transfusion	PE
	Myocarditis		ARDS
	Perioperative injury/ischemia (postcardiotomy)		Positive pressure ventilation
Chronic	RV cardiomyopathy	LH disease	
	ARVC	Single ventricle	
	Ebstein anomaly		Pericardial disease
		PR	PAH
		TGA	Chronic thromboembolic PH
		TR	PS
			Left-sided valvular heart disease
			Restrictive cardiomyopathy

ARDS indicates acute respiratory distress syndrome; ARVC, arrhythmogenic right ventricular cardiomyopathy; LH, left-sided heart disease; LVAD, left ventricular assist device; PAH, pulmonary arterial hypertension; PE, pulmonary embolism; PH, pulmonary hypertension; PR, pulmonary regurgitation; PS, pulmonary stenosis; RHF, right-sided heart failure; RV, right ventricular; RVMI, right ventricular myocardial infarction; TGA, transposition of the great arteries; and TR, tricuspid regurgitation.

in those without RVD.⁴⁸ Exercise intolerance is common in people with HFpEF, and those with evidence of RVD have lower New York Heart Association classification.⁵¹ In an exercise comparison between 50 patients with HFpEF and 24 control subjects, those with HFpEF had impaired RV systolic and diastolic functional enhancement measured by invasive cardiopulmonary exercise testing and simultaneous echocardiography.⁵² Increased left- and right-sided filling pressures and limitations in CO reserve correlated with abnormal augmentation in biventricular mechanics during stress, suggesting limited RV reserve with RV-PA uncoupling during.

Myocarditis

Inflammatory myocardial disease has varied clinical presentations and outcomes. The focus of myocarditis studies has been predominantly on characterization of LV function. RV involvement, however, may reflect a greater burden of inflammation, preexisting vulnerability to an acute process, or increased afterload caused by LHF. When treatment options are considered, the presence of RVD, depending on the severity, may dictate the need for biventricular support. In 174 patients with active or borderline myocarditis, RVD was present in 39% of patients with anti-heart autoantibodies compared with 17% of those without anti-heart autoantibodies.⁵³ The presence of RVD by cardiac magnetic resonance imaging (MRI) in a study of patients with myocarditis was associated with a hazard ratio of 3.4 for death or heart transplantation and was the strongest predictor of death.⁵³

RV Myocardial Infarction

Acute RVMI is prevalent in ≈50% of patients with an acute inferior MI.⁵⁴ A functionally-relevant acute RVMI generally requires disruption of blood flow to both the RV free wall and a portion of the interventricular septum. It typically occurs when a dominant right coronary artery is occluded proximally to the major RV branch(es), leading to reduced RV systolic function and acute RV dilation. A smaller proportion of patients have RVMI resulting from circumflex coronary artery occlusion in a left-dominant coronary system and rarely in association with left anterior descending coronary artery occlusion, in which this artery supplies collaterals to an otherwise underperfused anterior portion of the RV free wall.

RVMI is associated with hemodynamic compromise in 25% to 50% of patients presenting with this infarct pattern.⁵⁵ Early mortality is highest among patients with evidence of hemodynamic compromise.^{56,57} Patients with RVMI have a greater burden of arrhythmias, contributing to mortality.⁵⁷ Most patients recover RV func-

tion within days to weeks after the infarct.⁵⁸ One-year mortality after RVMI is reported to be 18% in patients with isolated right coronary artery lesions compared to 27% in the presence of combined right and left coronary artery disease. In long-term follow-up, mortality beyond the first year remains at an additional 2%/y to 3%/y through year 10.⁵⁹ In 1 series, mortality among patients with inferior MI with RVMI was 25% to 30% compared with 6% in patients without RVMI.⁶⁰ Similarly, among 666 patients with acute MI undergoing percutaneous coronary intervention, excluding those with cardiogenic shock on admission, electrocardiographic (ST-segment elevation of 0.1 mV in lead V₃R or V₄R) and echocardiographic evidence of RVMI (RV free wall motion abnormalities or RV dilatation) was associated with higher in-hospital and 1- and 6-month mortality compared with patients with either anterior or inferior MI without evidence of RVMI (although findings at 6 months were not statistically significant).⁵⁶ Although patients with inferior MI have, in general, a better prognosis than those with anterior MI, the presence of RV involvement increases the risk of death, shock, and arrhythmia.⁶¹ Among patients with MI complicated by cardiogenic shock enrolled in the SHOCK trial (Should We Emergently Revascularize Occluded Coronaries for Cardiogenic Shock), 5% had a picture of predominant RHF and the remainder had a shock syndrome characterized by LHF.⁶² Despite some favorable clinical characteristics among the patients with RHF, the mortality rate was similar between these 2 groups.

Postsurgical ARHF

ARHF may occur during or after noncardiac surgery as a result of the development of acute PH or intraoperative myocardial ischemia.⁶³ The prevalence of RHF after noncardiac surgery is difficult to determine. There is the potential for a survival bias whereby patients with more profound RHF die before full cardiac evaluation. Furthermore, preexisting HF may make the diagnosis of ARHF more challenging to differentiate.

During cardiac surgery, ARHF can be caused by hypoxia/myocardial ischemia, microemboli, air emboli leading to MI, arrhythmias, and excessive volume loading.^{64,65} Furthermore, there is a disruption in the native RV contractile pattern after cardiothoracic surgery. Although overall RV function remains preserved, the combination of cardiopulmonary bypass and pericardiotomy leads to a reduction in longitudinal contraction and an increase in transverse shortening.⁶⁶ In the normal RV, longitudinal shortening accounts for ≈80% of RV function.⁶⁷ Whether release of pericardial constraint after complete pericardiotomy predisposes the at-risk RV to the development of ARHF remains uncertain. RVD is frequently seen within 5 days of cardiac surgery and may persist despite improvements in LV function.⁶⁸

Postoperative ARHF is associated with increased mortality, prolonged length of stay, and increased resource use.⁶⁹ In a cohort of patients undergoing coronary artery bypass graft surgery, most patients did not demonstrate a significant postoperative change in RV function, although modest decreases in longitudinal strain were noted.⁷⁰

After Cardiac Transplantation

Primary graft dysfunction (PGD) affects $\approx 7\%$ or more of patients after cardiac transplantation and is the leading cause of early mortality.^{71,72} PGD may be classified as PGD of the LV, which includes biventricular dysfunction, versus PGD of the RV alone. Diagnosis of PGD of the RV alone requires both (1) RAP >15 mm Hg, PCWP <15 mm Hg, and cardiac index <2.0 L \cdot min $^{-1}\cdot$ m $^{-2}$ and (2) transpulmonary gradient <15 mm Hg and PASP <50 mm Hg or (3) the need for an RV assist device (RVAD).⁷¹ The pathogenesis of PGD is complex and likely multifactorial. Contributing causes consist of donor, procedural, and recipient-level factors, including inflammatory mediators resulting from brain death, elevated PVR, and ischemia/reperfusion injury associated with preservation issues.^{73,74} Although management of ARHF is discussed elsewhere, a decision on the need for right-sided MCS should be made before leaving the operative room, pending the initial response to medical interventions.^{74,75}

After LVAD

Twenty percent or more of patients undergoing isolated LVAD implantation experience ARHF, which is a leading cause of premature morbidity and mortality.^{76–78} Rates of RHF associated with LVAD insertion may be partially dependent on the underlying cause of myopathy. Patients with a history of chemotherapy-associated cardiomyopathy appear to be at higher risk than those with other forms of nonischemic or ischemic disease.⁷⁹ The physiology of ARHF after LVAD implantation is complex. From a hemodynamic perspective, activation of an LVAD increases venous return, potentially overwhelming a functionally impaired RV, leading to RV dilatation, TR, leftward shift of the interventricular septum, and decline in RV SV. As RV output falls and the septum shifts leftward, LV preload and LVAD flows are reduced. The RV is dependent on the LV for a significant portion of its contractile function, and leftward septal shift resulting from LV unloading can have a direct, detrimental effect on RV contraction.^{27,80} Furthermore, anchoring of the LVAD to the LV apex may alter the normal twisting contractile pattern of the heart. Whether the direction of apical deformation (ie, apical pull versus push, depending on device configuration and placement) alters the risk of RVD remains uncertain.

LV unloading with mechanical support may improve RV contractility via a reduction in PAP after the acute decline in PCWP associated with LVAD activation.^{80,81} PH, however, is a risk factor for the development of ARHF in LVAD recipients,^{82,83} and residual, fixed PH likely contributes to RV-PA uncoupling when other intraoperative complications are encountered. Even if compensated for in the preoperative period, a chronically dysfunctional RV coupled to a fixed and elevated pulmonary afterload may not be able to tolerate intraoperative insults such as ischemia and volume loading, which then precipitate ARHF.

In addition, it is possible that a reduction in systemic afterload after insertion of rotary blood pumps leads to a decline in LV contractility with a resultant secondary decline in RV contractility. The Anrep effect is the physiological consequence whereby increases in arterial afterload lead to increases in ventricular contractility. Although this relationship remains somewhat hypothetical in the LVAD-supported circulation, the converse of this is also true: Reductions in afterload may lead to reduced contractility.

Late RHF in the LVAD recipients, after initial hospital discharge, occurs in $\approx 10\%$ of patients and is similarly associated with reduced survival and lower HRQoL and functional capacity.^{84,85} The development of ventricular and atrial tachyarrhythmias may be a significant factor contributing to the development of late RHF.

PE With ARHF

Acute PE can lead to acute RV strain as a result of pressure overload within minutes of occlusion of a major PA segment and is a common cause of ARHF.^{33,63} Physical presentation often includes initial syncope or right-sided atrial arrhythmias. The prevalence of ARHF in the setting of acute PE ranges from 25% to 60%.^{86,87} Predictors of RVD include $>50\%$ of the PA tree occluded by thrombus.⁸⁸ Patients with evidence of RVD have a 2.4- to 3.5-fold increase in mortality compared with those without RVD.^{86,87} Given the poor prognosis, guidelines on the management of acute PE recommend early detection of RVD to guide risk stratification and therapeutic decision making.

Arrhythmogenic RV Cardiomyopathy

Arrhythmogenic RV cardiomyopathy (ARVC) is a disease of the cardiac myocytes caused by impaired desmosome function.⁸⁹ Desmosomes are intercellular junctions that provide adhesion between cells. Mutations in desmosomal proteins such as plakophilin and desmoplakin decrease the ability of the cells to tolerate mechanical stress, resulting in myocyte detachment and cell death. The inflammation that accompanies this process manifests as fibrofatty infiltration, causing ven-

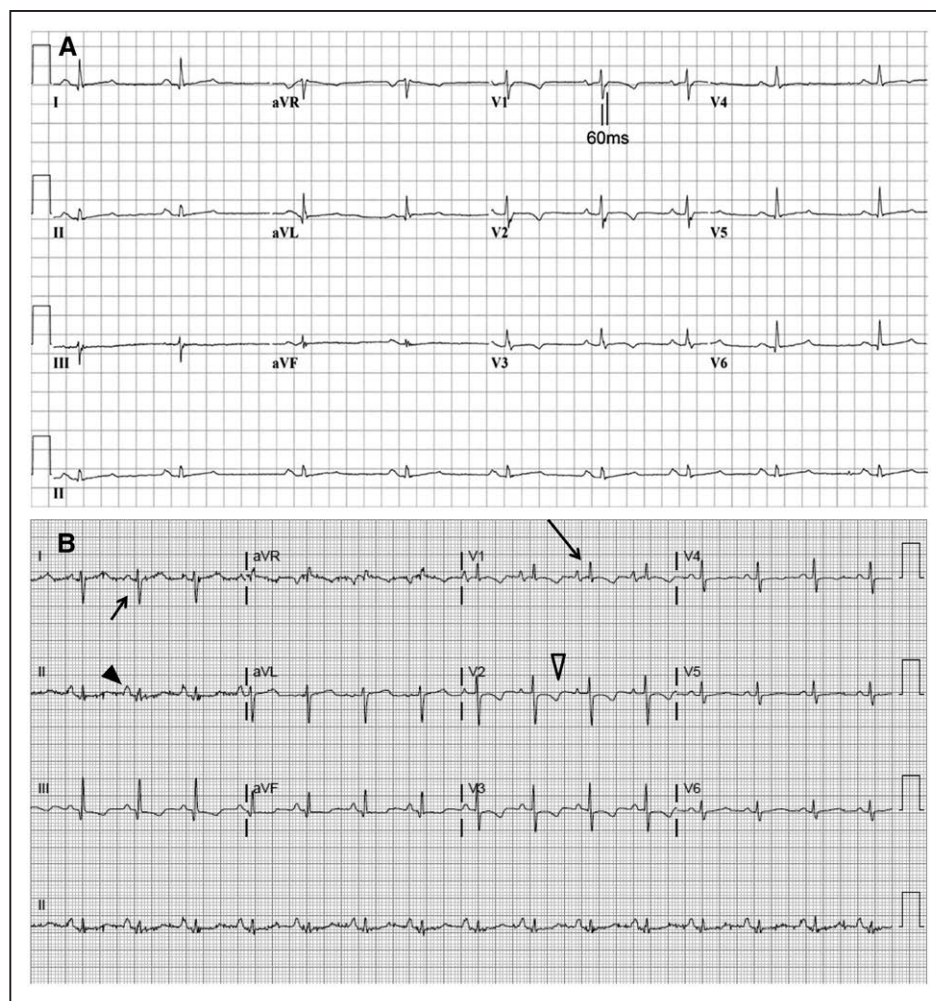


Figure 9. ECGs in patients with right-sided heart disease.

A, ECG from a patient with arrhythmogenic right ventricular cardiomyopathy. ECG from a patient with T-wave inversion in V_1 through V_4 and prolongation of the terminal activation of a 55-millisecond duration measured from the nadir of the S wave to the end of the QRS complex in V_1 . Reproduced with permission from Marcus et al.⁹² Copyright © 2010, American Heart Association. **B**, ECG with right ventricular hypertrophy. ECG demonstrating the changes of right ventricular hypertrophy. **Long arrow** indicates dominant R wave in V_1 ; **short arrow**, right-axis deviation; **black arrowhead**, right atrial abnormality; and **open arrowhead**, secondary ST-T changes.

tricular irritability and arrhythmias and eventually ventricular dysfunction. In affected patients, this process shows a predilection for the thinnest portions of the RV where mechanical stress is greatest. However, the LV also is often affected in advanced disease.⁹⁰

The prevalence of ARVC is estimated to be 1 in 2000 to 5000, and ARVC affects men more frequently than women. A familial component is identified in >50% of patients.⁹¹ Transmission is autosomal dominant with incomplete penetrance. Diagnosis of ARVC can be difficult, so standardized criteria have been developed that are based on family history, ventricular dysfunction, tissue characterization, electrocardiographic changes (Figure 9A), and history of arrhythmias.⁹³ The sensitivity of electrocardiographic criteria alone (Table 2) for the diagnosis of ARVC is low. Diagnosis requires a specific combination of major and minor criteria from the ECG,

RV imaging, and family history that are reviewed in detail elsewhere.⁹³ Genetic screening, although not required, may be helpful when screening family members of a recently diagnosed patient.^{93,94} Recommendations for the role of genetic testing of probands and first-degree relatives have been published.⁹⁴

ARVC is more often associated with arrhythmia than isolated RVD. In Italy, where young athletes undergo detailed screening before participation in sports, ARVC was a cause of sudden cardiac death (SCD) in >20%.⁹⁵ In a registry of SCDs in athletes from the United Kingdom, ARVC was detected in 13% of 357 subjects.⁹⁶ Among 100 US patients diagnosed with ARVC, the median age at presentation was 29 years, but age at presentation varied widely, from 2 to 70 years.⁹⁷ Thirty-one patients experienced SCD, and 6 patients progressed to RHF, one of whom died while awaiting cardiac transplantation.

Table 2. Revised Task Force Criteria for Electrocardiographic Diagnosis of ARVC

Repolarization abnormalities	
Major	Inverted T waves in right precordial leads (V_1 – V_3) or beyond in individuals >14 y of age (in the absence of complete right bundle-branch block QRS ≥ 120 ms)
Minor	Inverted T waves in leads V_1 and V_2 in individuals >14 y of age (in the absence of complete right bundle-branch block) or in V_4 , V_5 , or V_6 Inverted T waves in leads V_1 – V_4 in individuals >14 y of age in the presence of complete right bundle-branch block
Depolarization/conduction abnormalities	
Major	Epsilon wave (reproducible low-amplitude signals between end of QRS complex and onset of the T wave) in the right precordial leads (V_1 – V_3)
Minor	Late potentials by SAECG in ≥ 1 of 3 parameters in the absence of a QRS duration ≥ 110 ms on the standard ECG Filtered QRS duration ≥ 114 ms Duration of terminal QRS <40 V (low-amplitude signal duration) 38 ms Root-mean-square voltage of terminal 40 ms ≤ 20 μ V Terminal activation duration of QRS ≥ 55 ms measured from the nadir of the S wave to the end of the QRS, including R, in V_1 , V_2 , or V_3 , in the absence of complete right bundle-branch block

ARVC indicates arrhythmogenic right ventricular cardiomyopathy; and SAECG, signal-averaged ECG.

Adapted from Marcus et al⁹² with permission. Copyright © 2010, American Heart Association.

More than 90% of patients had a life-threatening arrhythmia at some point during follow-up.⁹⁷ This statistic is, of course, influenced by selection bias because the presence of ventricular arrhythmia increases the probability of ascertaining the diagnosis of ARVC. Indications for implantable cardioverter-defibrillator therapy in ARVC are available.⁹⁸

Tricuspid Regurgitation

TR is a common echocardiographic finding, and mild TR is present in 80% to 90% of individuals. Although less common, moderate to severe TR affects >1 million people in the United States.⁹⁹ TR can be related to 2 principal types: primary valvular TR and secondary functional TR. Functional changes of the TV related to annular dilation and leaflet tethering in the setting of RV remodeling caused by pressure and volume overload are the most common causes of significant TR, accounting for 85% of cases.¹⁰⁰ In contrast, primary TR is secondary to lesions of the valve structure itself such as endocardial cushion abnormalities, Ebstein anomaly, endocarditis, and carcinoid heart disease.

The severity of TR affects prognosis even when controlling for LV dysfunction or PH. In a study of 5223 patients at 3 Veterans Affairs medical centers, 1-year survival rates were 92%, 90%, 79%, and 64% in patient groups with no, mild, moderate, or severe TR, respectively.¹⁰¹ Moderate or greater TR was associated with

Table 3. Classification of PH

PH Category	Characteristics	Clinical Group
Precapillary	MPAP ≥ 25 mm Hg PCWP ≤ 15 mm Hg	WHO class 1, 3–5
Postcapillary	MPAP ≥ 25 mm Hg PCWP > 15 mm Hg	WHO class 2, 5
Isolated postcapillary PH	DPG < 7 mm Hg and/ or PVR ≤ 3 WU	
Combined precapillary and postcapillary PH	DPG ≥ 7 mm Hg and/ or PVR > 3 WU	

DPG indicates diastolic pulmonary gradient; MPAP, mean pulmonary artery pressure; PCWP, pulmonary capillary wedge pressure; PH, pulmonary hypertension; PVR, pulmonary vascular resistance; WHO, World Health Organization; and WU, Woods units.

Reproduced from Galie et al¹⁰⁹ with permission. Copyright © 2016, Oxford University Press.

increased mortality regardless of PASP or LVEF. Severe TR, older age, lower LVEF, inferior vena cava dilation, and moderate or greater RV enlargement were associated with worse survival.

PV Disease

Pulmonary stenosis (PS) occurs in $\approx 10\%$ of children with CHD. PS can be encountered as part of tetralogy of Fallot (TOF), the incidence of which is 6 in 20000 live births,^{102,103} or other complex CHDs such as transposition of the great arteries (TGA), ventricular septal defect, and PS or an isolated valve abnormality. PV atresia can be seen in patients with TOF but can also be encountered in those with an intact ventricular septum. PS can also be seen in patients with Noonan syndrome, in whom it can be isolated or seen in combination with cardiomyopathy. PV disease can be found in the setting of endocarditis, especially in intravenous drug users, or in carcinoid heart disease.^{104,105} Patients with isolated PS do quite well, usually treated with balloon valvuloplasty alone. When treated, long-term survival of patients with PS is not different from that in individuals without PS.¹⁰⁶ The development of RHF in patients with isolated PS is rare.

Pulmonary insufficiency is most often a consequence of balloon valvuloplasty or surgical repair of congenital abnormalities and is commonly seen after complete repair of TOF.¹⁰⁷ The highest-risk group is made up of patients with a small PV annulus, in whom surgical repair involves placement of a transannular patch, leaving the patient with an incompetent PV. Historically, surgeons have attempted to make this patch as large as possible to relieve PS; however, more contemporary techniques use a smaller transannular patch, recognizing that a small degree of residual PS is preferable for preservation of long-term RV function than wide-open pulmonary insufficiency. MRI studies have shown RV fibrosis in 99% of patients with repaired TOF and LV fibrosis in 53%.¹⁰⁸ In 10% to 15% of patients, pulmo-

nary insufficiency leads to progressive RV dilatation and dysfunction and may require PV replacement later in life.^{103,107} Left unrepaired, RV dilatation and dysfunction can lead to ventricular arrhythmias with a rate of SCD in this population estimated to be 0.3%/y.¹⁰³

PULMONARY HYPERTENSION

The evaluation of a patient with RVD includes an assessment for increased RV afterload. PH is characterized by alterations in the pulmonary vasculature leading to increased PVR and ultimately RVD. The increased afterload on the RV leads to RV hypertrophy, dilation, and systolic dysfunction. PH is defined as a mean PAP ≥ 25 mmHg and when present is associated with impaired survival. PH is found in isolation and as a consequence of other diseases as detailed below. Patients are categorized on the basis of the mechanism of disease (Table 3).

Group 1: Pulmonary Arterial Hypertension

Pulmonary arterial hypertension (PAH) describes a group of disorders characterized hemodynamically by the presence of precapillary PH, defined by a PCWP ≤ 15 mmHg and a PVR >3 Woods units in the absence of other causes of precapillary PH such as chronic lung disease.^{109,110} Initial PH screening is typically performed with echocardiography, but right-sided heart catheterization is required for definitive diagnosis. The incidence for all group 1 PAH is 2.3 cases per 1 million adults with an overall prevalence of 12.4 per 1 million adults.¹¹¹ Group 1 includes those patients with idiopathic PAH; hereditary PAH; PAH caused by drugs and toxins; PAH associated with connective tissues disease, portal hypertension, HIV, CHD with persistent pulmonary-to-systemic shunt, Eisenmenger physiology, and schistosomiasis; persistent PAH of the newborn; pulmonary veno-occlusive disease; and pulmonary capillary hemangiomatosis.¹¹²

Patients with PAH benefit from care provided in centers with expertise in this condition. Despite the introduction of new pulmonary vasodilator therapies, group 1 PH continues to be associated with high morbidity and mortality. In a US cohort of patients in the REVEAL registry (Registry to Evaluate Early and Long-Term Pulmonary Arterial Hypertension Disease Management), 1- and 5-year survival rates were 85% and 57%, respectively.¹¹³ PAH secondary to connective tissue disease or portopulmonary hypertension is associated with a worse prognosis. The presence of RVD in patients with PAH is a strong predictor of adverse outcomes and more closely associated with clinical outcomes than the PAPs.¹¹⁴ Hemodynamic and echocardiographic markers of RVD associated with increased mortality include

RA and RV dilation, elevated RAP, RV systolic dysfunction, the presence of a pericardial effusion, decreased PA capacitance, and reduced CO.^{110,113,115} Assessment of RV strain may add prognostic value to traditional markers of RVD in the assessment of PAH.^{116,117} There is significant variability in the timing of the onset of RHF among patients, including those with similarly elevated PAP.^{18,114,118,119} Other variables associated with reduced survival include lower functional class, lower blood pressure (BP), higher heart rate, increased BNP (B-type natriuretic peptide), reduced diffusion capacity of the lung for carbon monoxide, and reduced 6-minute walk distance.¹²⁰ In the subset of patients with elevated RV pressure secondary to Eisenmenger syndrome or congenital PS, chronic RV pressure overload can be reasonably well tolerated for decades.^{121–123}

Pulmonary veno-occlusive disease represents a small subgroup of group 1 PAH associated with a particularly poor prognosis.¹²⁴ In contrast to other forms of PAH, pulmonary veno-occlusive disease results in postcapillary PH. Vasodilatory therapy can lead to clinical worsening in patients with pulmonary veno-occlusive disease, and these patients should be considered for lung transplantation.

Group 2: LH Disease

Chronically elevated left-sided filling pressures from LV systolic and diastolic dysfunction or significant left-sided valvular heart disease can lead to PH.¹²⁵ A study of 1063 patients with HF found that 68% of those with HFrEF and 54% with HFpEF had PH.²⁵ The definition of group 2 PH requires a mean PAP ≥ 25 mmHg with a PCWP >15 mmHg or LV end-diastolic pressure ≥ 18 mmHg.¹¹⁰ Most patients with HF have postcapillary PH, characterized by low PVR (<3 Woods units) and low transpulmonary gradient (≤ 12 mmHg). Others, however, have elevation of PVR and transpulmonary gradient, historically described as out-of-proportion or mixed PH. The commonly used measures of out-of-proportion PH include transpulmonary gradient, PVR, and the diastolic pulmonary gradient (diastolic pulmonary gradient = PA diastolic pressure – PCWP).¹⁶ A diastolic pulmonary gradient ≥ 7 mmHg suggests pulmonary vascular disease superimposed on left-sided pressure elevation.¹²⁶ Classification of postcapillary PH in the 2015 European Society of Cardiology guidelines for the diagnosis and treatment of PH identified patients as having either isolated postcapillary PH, defined by a diastolic pulmonary gradient <7 mmHg, or combined precapillary or postcapillary PH (Cpc-PH) with diastolic pulmonary gradient ≥ 7 mmHg and concomitantly elevated PVR >3 Woods units (Table 3).¹⁰⁹ In 1 study, Cpc-PH was observed in 12% of patients with HF with an equal prevalence in HFrEF and HFpEF.²⁵ Predictors of Cpc-PH included younger age, coexistent chronic obstructive

pulmonary disease, and valvular heart disease. Compared with isolated postcapillary PH, Cpc-PH was associated with increased mortality. RV–pulmonary vascular coupling is poor in Cpc-PH and has been proposed as an explanation for poor outcomes associated with this syndrome.^{25,127,128}

Group 3: Chronic Lung Disease and Hypoxia

PH caused by chronic obstructive pulmonary disease or interstitial lung disease is usually mild to moderate in severity.¹²⁹ The small number of patients with severe PH in this category may have an additional underlying pathogenesis for an elevated PVR. PH is seen in ≈20% of patients with obstructive sleep apnea.^{130,131} Obesity hypoventilation syndrome is similarly associated with a high prevalence of PH and RVD^{132–134} and a high rate of overlap among patients with these 2 diagnoses.

Group 4: Chronic Thromboembolic Disease

When PH is identified, exclusion of chronic thromboembolic PH is required, given that surgical intervention can alter the natural history of this disease. A significant proportion of patients without a history of PE are ultimately diagnosed with chronic thromboembolic PH. Ventilation/perfusion scan is standard in the evaluation of newly diagnosed PH.^{109,110} Among patients undergoing pulmonary endarterectomy at experienced centers, 3-year survival is as high as 90%, and 10-year survival is 72%.¹³⁵ Limited data from observational studies describe a potential role for percutaneous balloon angioplasty in patients with inoperable disease.^{136–138}

Group 5: Miscellaneous

Group 5 PH is characterized by diseases with multiple or unclear mechanisms contributing to the development of PH. This group includes systemic illnesses such as sarcoidosis, chronic hemolytic disorders, and chronic kidney disease. Myocardial depression during sepsis is a well-known phenomenon, and RHF can occur independently of PH or respiratory status.¹³⁹ RVD can occur in isolation or concomitantly with LV dysfunction. A combination of reduced RV contractility and decreased preload caused by systemic vasodilation can impair circulation. Acute respiratory distress syndrome and mechanical ventilation are associated with increased PVR, which can also precipitate RVD. In a small study of septic patients evaluated with radionuclide imaging, patients with worsening respiratory status and PH were less likely to have recovery of RV function.¹⁴⁰

CONGENITAL HEART DISEASE

CHD affects nearly 1% of births per year.^{141,142} Because of improved surgical techniques and advances in the medical care of patients with CHD, the prevalence of congenital heart defects in adult patients has grown substantially over the past decade. As of 2003, the estimated 1.4 million adults in the United States living with CHD exceeded the number of children with CHD.¹⁴³ Many patients with CHD have significant RV involvement because of right-sided valvular lesions, intracardiac shunting, or the presence of a systemic RV. The prognosis for each lesion of CHD is dependent on the severity of the residual hemodynamic abnormalities and other associated defects.

Atrial Septal Defect

There are 3 types of atrial septal defects (ASDs): ostium secundum (most common), ostium primum, and sinus venosus.^{102,144} Larger ASDs pose little or no resistance to intra-atrial flow, yielding equalization or near equalization of left atrial pressure and RAP. In the absence of pulmonary vascular obstructive disease (Eisenmenger physiology), the magnitude of the left-to-right shunt in unrestrictive ASDs relates primarily to the relative compliance characteristics of the 2 ventricles. The shunt poses a volume load on the RV, dilating this chamber, as well as the pulmonary vasculature and left atrium, but if not complicated by additional anomalies or PH, it seldom results in RHF in early life. RV volume overload is associated with LV dysfunction secondary to altered chamber geometry and decreased myofiber preload, which is immediately reversible after ASD closure and reflective of the ventricular interdependence.¹⁴⁵ Across multiple disease types, in the absence of primary RV pathology, RVEF tends to correlate with PAP. However, because of increased preload associated with an ASD, RVEF is higher than would otherwise be expected for any degree of RV contractile dysfunction or afterload.¹⁴⁶

ASDs do not close spontaneously, and in developed countries, they are generally surgically corrected in childhood. Left uncorrected, they are associated with pulmonary vascular obstructive disease and Eisenmenger physiology in a small percentage of cases. Eisenmenger syndrome is characterized by progressive PVR, PH, reversal (or bidirectionality) of the intracardiac shunt, cyanosis, and RV hypertrophy and failure. The frequency of this syndrome is much lower with an ASD than a ventricular septal defect because in the latter case increased pulmonary blood flow is accompanied by increased pressure caused (effectively) by direct LV ejection into the pulmonary circulation, impeded only by the resistance posed by the intracardiac defect itself. When ASDs are allowed to persist into late adult life, in the absence of Eisenmenger physiology, an in-

creased rate of morbidity and mortality may be driven by an increased magnitude of the left-to-right shunt, the result of progressive LV stiffness caused by systemic hypertension or aging.^{121,144} In these cases, RHF may ensue as a result of the increase in both volume and pressure load, the latter generally driven more by the increased magnitude of pulmonary flow than obstructive pulmonary vascular disease. Therefore, if the ASD is missed or ignored in childhood, it is not unusual for the patient to present symptomatically for the first time in late life.

Ebstein Anomaly

In Ebstein anomaly, ≥ 1 leaflets of the TV are adherent to the RV wall, leading to atrialization of a portion of the RV chamber with varying degrees of TR.¹⁰² In neonates, severe Ebstein anomaly can lead to profound cyanosis caused by the inability of the RV to eject into the pulmonary circulation. In older patients with milder forms, it can lead to cyanosis with exercise caused by shunting across a foramen ovale or an ASD. The degree of long-term RHF depends on the degree of RV hypoplasia or the success of TV reparative surgery.

Transposition of the Great Arteries

L-TGA is commonly referred to as corrected transposition. In this lesion, the morphological RV serves as the systemic ventricle and is coupled to the high-pressure systemic circulation. The majority of patients with L-TGA have other significant cardiac defects, most commonly including ventricular septal defect and PS. The TV is almost always abnormal, frequently with Ebstein-like displacement, leading to TR and RV volume overload. RHF occurs in up to 50% of patients with L-TGA by middle age, with the risk increased by the presence of associated lesions such as TV disease.¹⁴⁷

D-TGA results in cyanosis in the newborn period. Before the 1980s, surgical repair involved placement of an atrial baffle (atrial switch, Mustard or Senning procedure) to redirect venous return, leaving the RV as the systemic ventricle. Analogous to patients with L-TGA, the RV in these patients is at increased risk of dilatation and failure. The arterial switch operation involves transection of both great arteries and translocation of the vessels to the opposite root, creating ventriculoarterial concordance, and has become the standard corrective procedure for this lesion.¹⁴⁸

Single-Ventricle (RV) Physiology

There are various forms of single-ventricle morphology. In the most severe forms of CHD involving hypoplasia or total absence of the LV (ie, hypoplastic LH syndrome), surgical palliative procedures result in the RV

Table 4. Manifestations of RHF

Clinical manifestations of RHF
Increased mortality
Fatigue/decreased functional capacity
Cardiorenal abnormalities
Cardiohepatic abnormalities
Protein malnutrition
Coagulopathy
Cachexia
Signs and symptoms
Elevated jugular venous pressure with prominent V wave
Peripheral edema
Bloating/early satiety/abdominal discomfort
Ascites and hepatomegaly
Pleural effusion
Prominent S ₂ (P ₂) (PH)
Right-sided S ₃ gallop
Holosystolic murmur LLSB (TR)
RV parasternal heave

LLSB indicates left lower sternal border; PH, pulmonary hypertension; RHF, right-sided heart failure; RV, right ventricular; and TR, tricuspid regurgitation.

being used as the systemic ventricle, coupled to the high-resistance systemic circulation. In these patients, pulmonary blood flow is achieved by connecting the vena cavae directly to the pulmonary arteries (Glenn and Fontan operations). There are a number of long-term complications in patients with a single ventricle, including protein-losing enteropathy, plastic bronchitis, and hepatic fibrosis. However, systemic RV dilation, TR, and RHF become increasingly common as patients enter their third and fourth decades. Patients with a systemic RV are at greater risk of developing HF than patients with a systemic LV.¹⁴⁹ Fibrosis is present in >25% of patients with a Fontan operation.¹⁵⁰

CLINICAL MANIFESTATIONS OF RHF

Acute RHF

ARHF is generally characterized by acute RV dilation, a ventricular-interdependent effect limiting LV filling, reduced RV forward flow, and elevated systemic venous pressure. Patients with ARHF typically show signs of hypoperfusion and hypotension, including diaphoresis, listlessness, cyanosis, cool extremities, hypotension, and tachycardia.¹⁵¹ Although chest auscultation may point to underlying lung pathology, the finding of pulmonary edema is not consistent with isolated ARHF. Instead, if pulmonary edema is present, it suggests ARHF combined with or secondary to LHF. In this setting, many of the common clinical findings of CRHF (see Chronic RHF) such as peripheral

edema may initially be less prominent or absent altogether. Besides systemic hypoperfusion, prominent clinical findings in ARHF include shortness of breath resulting from diminished peripheral oxygen delivery, as well as atrial and ventricular arrhythmias. On clinical examination, signs of ARHF include increased jugular venous pressure with a prominent v wave, prominent midprecordial cardiac impulse, right-sided third heart sound, and holosystolic murmur of TR. Hepatomegaly, ascites, and peripheral edema may be present when ARHF is superimposed on CRHF. Right upper quadrant discomfort may be caused by stretch of the hepatic capsule by hepatic congestion. If a patent foramen ovale is present ($\approx 15\%$ of adults), right-to-left shunting at the atrial level can lead to systemic hypoxemia and cyanosis.

Chronic RHF

Peripheral edema is often the most prominent clinical feature in patients with CRHF⁶³ (Table 4). Although patients with early stages of CRHF may initially have mild symptoms, as RV function worsens, the reduction in CO leads to progressive exercise intolerance and fatigue. Atrial tachyarrhythmias are common in the setting of elevated RAP and can lead to hemodynamic deterioration in CRHF.¹⁵² Ventricular tachycardia and heart block are additional electrophysiological complications and common causes of SCD in this population. In patients with PH, CRHF closely correlates with increased morbidity and mortality.^{114,153}

The hemodynamic constellation driving the deleterious effects of CRHF on end-organ function differs between CRHF and primary LHF, the former representing a combination of increased central venous pressure (CVP) and reduced LV filling resulting from ventricular interdependence as a consequence of RV dilation.^{18,63} Recent studies have also suggested a primary role for elevated CVP in the pathophysiology of end-organ dysfunction occurring in the setting of primary LHF.³⁹ In the later stages of CRHF when systemic output is reduced, impaired end-organ function may be caused by both elevated central venous filling pressure and reduced CO (Figure 7). Increased systemic venous pressure impedes lung lymphatic drainage, decreasing lung fluid clearance and exacerbating pulmonary edema and the development of pleural effusions in the setting of concomitant postcapillary PH.¹⁸ The organs most affected in CRHF are the kidneys and liver, with recent studies implicating the gastrointestinal tract.^{154,155}

Cardiorenal Syndrome

In patients with RHF, the increase in CVP and consequent rise in renal vein pressure worsen renal function, even in the absence of decreased CO (Figure 10).¹⁵⁷ In-

creased CVP has been identified as an independent risk factor for impaired renal function in patients with HF of diverse origins.^{39,157} Clinical features include decreased urine output, worsening fluid retention, and increased diuretic requirements.⁶³ Laboratory abnormalities include increased blood urea nitrogen and creatinine.⁶³ Elevated and worsening levels of serum creatinine and blood urea nitrogen are independent predictors of adverse outcomes, unless they are accompanied by significant decongestion in the setting of acute HF.¹⁵⁸ These findings, connoting worsening renal function, may be causally linked to adverse outcomes or may, in part, represent epiphenomena connoting worsening HF and cardiac function. Furthermore, these findings may limit the clinician's aggressiveness in pursuing diuresis and using guideline-directed medical therapy, including renin-angiotensin-aldosterone system-inhibiting agents, and may promote the use of inotropic agents with their associated deleterious effects. Considerable efforts to identify treatments that simultaneously resolve congestion, improve clinical HF, and preserve or improve renal function have had limited success.^{159–161} Continued investigation into the interdependency of right-sided heart function and the cardiorenal syndrome is warranted.

Increasing evidence of acute kidney injury in the setting of elevated right-sided filling pressures may motivate clinicians to erroneously reduce loop diuretic therapy. However, this action may be deleterious because there is a proverbial "hump" one must get over to improve hemodynamics sufficiently that diuresis becomes increasingly effective. If the volume status is unclear or there is concern that the clinical presentation represents isolated RHF, then placement of a PA catheter may be informative.

Cardiohepatic Syndrome

The term *congestive hepatopathy* is a misnomer because it generally results from a combination of hepatic congestion and reduced hepatic perfusion. Over time, congestive hepatopathy can lead to the development of cardiac cirrhosis.^{155,162} The most prominent laboratory abnormalities include markers of cholestasis (elevated bilirubin, γ -glutamyl transpeptidase, and alkaline phosphatase) and altered synthetic function (prolonged prothrombin time). These laboratory abnormalities are more commonly encountered than elevations in transaminases.^{163,164} Severity of TR has been found to be closely associated with liver function abnormalities,¹⁶⁵ and markers of cholestasis are independently associated with mortality among patients with HF.^{163,164} Likewise, hyperbilirubinemia is a risk factor for poor outcomes in patients with PH.¹⁶⁶ In the setting of these abnormalities, patients being considered for advanced HF therapies such as cardiac transplantation may require a liver biopsy to exclude cirrhosis,

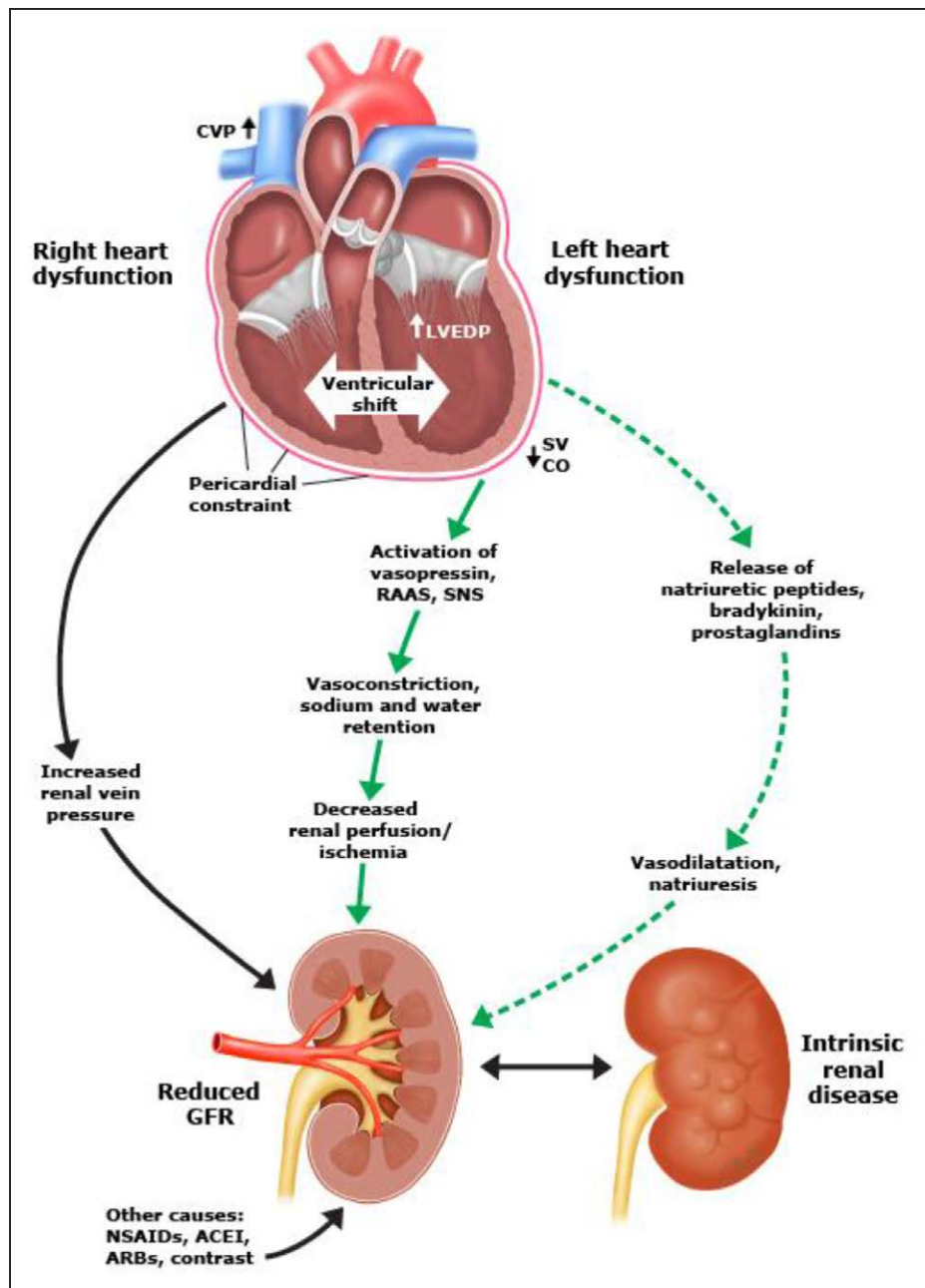


Figure 10. Pathophysiology of cardiorenal disease: acute decompensated heart failure leading to kidney injury.

ACEI indicates angiotensin-converting enzyme inhibitor; ARB, angiotensin-2 receptor blocker; CO, cardiac output; CVP, central venous pressure; GFR, glomerular filtration rate; LVEDP, left ventricular end-diastolic pressure; NSAID, nonsteroidal anti-inflammatory drug; RAAS, renin-angiotensin-aldosterone system; SNS, sympathetic nervous system; and SV, stroke volume. Reproduced with permission from Kiernan MS, Udelson JE, Sarnak M, Konstam M. Cardiorenal syndrome: definition, prevalence, diagnosis, and pathophysiology. In: Post TW, ed. UpToDate. Waltham, MA: UpToDate.¹⁵⁶ Accessed on January 30, 2018. Copyright © 2017, UpToDate, Inc. For more information, visit www.uptodate.com.

particularly if hepatic imaging is also abnormal.¹⁶⁷ Furthermore, patients with end-stage liver disease are at risk for the developing portopulmonary hypertension, which is associated with worse outcomes after liver transplantation.¹⁶⁸ Isolated and markedly elevated transaminases are more commonly caused by severely reduced CO/cardiac shock and respond better to inotropes than diuretic therapy. Increased serum am-

monia is also associated with adverse prognosis in decompensated HF.¹⁶⁹

Gastrointestinal Involvement

Gastrointestinal tract function can be impaired by RHF as a consequence of increased CVP and reduced CO, leading to reduced absorption and malnutrition.^{155,169} Splanchnic venous congestion with deficient abdominal

lymph flow causes interstitial edema with ensuing increases in intra-abdominal pressure that may contribute to RHF-induced renal failure.^{155,170} Visceral edema also impairs the barrier function of the intestine, allowing entrance of toxins produced by microorganisms in the gut lumen into the bloodstream, which can further suppress cardiac and renal function and contribute to systemic inflammation.^{154,171} Protein-losing enteropathy, a complication most commonly associated with single-ventricle physiology, is also less commonly seen with other forms of RHF, including severe TR.^{172,173} Laboratory abnormalities include reduced serum albumin and increased stool α_1 -antitrypsin.

EVALUATION OF RHF

Physical Examination

Patients with severe RHF may appear emaciated, tachypneic, and cyanotic. Patients with significant RHF typically have elevated jugular venous pressure with a prominent V wave from TR. Atrial fibrillation is common. Those in sinus rhythm may have a prominent A wave caused by RV diastolic abnormalities. Increased jugular venous pressure with inspiration (Kussmaul sign) may also be seen with a noncompliant RV. The abdominojugular reflex test, defined as a sustained rise of >3 cm in the jugular venous pressure for at least 15 seconds with calm spontaneous respiration, may unmask subtle venous hypertension.¹⁷⁴ A precordial RV heave, hepatomegaly and ascites, and lower extremity or presacral edema may be observed. For patients with RHF secondary to PH, a prominent pulmonic component of the second heart sound (P_2) may be heard on auscultation. In contrast, for those with CHD, P_2 may be soft or even absent in cases when there is a structural or postsurgical abnormality of the PV. A low-amplitude holosystolic murmur of TR may be present. An increase in the amplitude of the systolic murmur during inspiration (Carvallo sign) may distinguish TR from mitral regurgitation. For patients with CHD such as repaired TOF, there may be a to-and-fro murmur of combined PS and insufficiency at the upper left sternal border, with radiation to the lungs.

Electrocardiographic Evaluation

CRHF is often associated with right-axis deviation, R:S amplitude ratio of >1 in lead V_1 , R wave >0.5 mV in V_1 , and p-wave amplitude of >2.5 mm in II, III, aVF or >1.5 mm in V_1 indicative of RA enlargement (Figure 9B). ARHF may be associated with sinus tachycardia and a qR pattern in lead V_1 .^{175,176} An initial S deflection in I, initial Q deflection in III, and inverted T in III (SI, QIII, TIII) may point to acute RV strain such as in the case of large PE (high specificity, low sensitivity). Atrial arrhythmias, especially atrial flutter, are common.

Serum Markers

In CRHF, the transaminases may be normal or minimally elevated; however, in ARHF, transaminase levels are commonly high.¹⁷⁷ In advanced CRHF, liver synthetic function may be impaired as evidenced by reduced albumin and elevated international normalized ratio. Increased bilirubin can be related to passive congestion or cholestasis or could suggest the onset of fibrosis and cirrhosis. In more severe cases, venous congestion combined with systemic hypoperfusion can lead to renal insufficiency characterized by an elevation in the blood urea nitrogen and creatinine.³⁹

Echocardiography

Guidelines on the echocardiographic assessment of the RV are available elsewhere.¹⁷⁸ There are limitations to the quantification of RV function by 2-dimensional echocardiography because of the complex geometry and retrosternal position of the RV, significant intraobserver variability, and load and angle dependence of standard imaging parameters, including TAPSE, RVFAC, and tricuspid annular systolic velocity by tissue Doppler.¹⁷⁹ Although strain and strain rate are independent of ventricular morphology and angle independent when obtained by speckle tracking, these measures are intrinsically load dependent.¹⁸⁰ RV strain imaging is becoming an increasingly popular tool in the evaluation of PH and, when performed in experienced hands, is independently prognostic.^{116,117} However, given the high variability in addition to a current lack of standardization and normative data, the American Society of Echocardiography does not yet recommend tissue Doppler imaging for this purpose.¹⁷⁸

RV Size

Compared with volumetric MRI, 2-dimensional measurements of RV size can be erroneous because of the complex shape of the RV.¹⁸¹ RV enlargement is suggested if the RV area dimension is larger than the LV area in end diastole in the apical 4-chamber view. A linear RV basal dimension of >4.2 cm also suggests significant enlargement. RV end-diastolic wall thickness of >5 mm in the subcostal view indicates hypertrophy.¹⁷⁸

RV Function

RV motion is restricted mainly to longitudinal (base to apex) shortening and systolic thickening. Longitudinal shortening of the RV may be measured by TAPSE (normal reference limit ≥ 1.7 cm). TAPSE reflects systolic motion of a single point of tricuspid annulus, disregarding the contribution of mid, apical, and free wall segments.¹⁷⁸ Motion of the TV annulus is affected by prior cardiac surgery, which may render TAPSE less useful in this population. Additional measures of RV systolic dysfunction include RVFAC <35% and RV tissue Doppler S'

velocity <10 cm/s at the plane of the tricuspid annulus. Three-dimensional echocardiography is emerging as a potential alternative, perhaps more accurate, method of evaluating RV size and contractility.^{182,183} Close correlation exists between 3-dimensional echocardiography and MRI for RV size in patients with PH and CHD.^{184,185}

RV diastolic dysfunction may be measured with tissue Doppler early diastolic myocardial velocity at the tricuspid lateral annulus (E) and early diastolic tricuspid inflow (E') ratio (E/E') as demonstrated in patients with PH.^{186,187}

An estimate of PASP can be made by Doppler interrogation of TR, assuming an adequate Doppler envelope. PASP is calculated as the Doppler gradient across the TV plus estimated RAP. PASP may be underestimated with poor ultrasound alignment and overestimated if the patient is anemic, as well as in cases when RAP is severely elevated.

The TAPSE/PASP ratio has recently been proposed as a potential marker of RV-PA coupling because TAPSE reflects RV contractile function and PASP serves as a surrogate of afterload.¹⁸⁸ This ratio was lower in subjects who died with a similar distribution in the HFrEF and HFpEF populations.

The inferior vena cava diameter and collapsibility with respiration can be used to estimate RAP as a marker of volume status. Hepatic vein flow reversal indicates severe TR, whereas leftward interatrial septal bowing also indicates RAP or volume overload. Although volume overload and pressure overload frequently occur simultaneously, diastolic septal flattening is associated with a volume-overloaded state, whereas systolic flattening is more consistent with pressure overload.

Cardiac MRI

Cardiac MRI offers 3-dimensional, tomographic imaging of the entire heart and has become the gold standard for quantitative noninvasive measurement of RV volume, mass, and EF, including patients with CHD.^{189–193} Delayed gadolinium enhancement methods can identify areas of RV fibrosis, although given the thinner wall of the RV, this may be more challenging compared with use for quantification of LV fibrosis. Dynamic real-time imaging during deep inspiration and expiration has been developed to detect RV volume changes and intermittent interventricular septal flattening.¹⁹⁴ Velocity-encoded methods also measure CO.

Multidetector Computed Tomography

Similar to cardiac MRI and 3-dimensional echocardiography, multidetector computed tomography provides volumetric information about RV size and function.^{195,196} The high spatial resolution of contrast-enhanced computed tomography, combined with its

rapid scan sequence, makes it an appealing modality for RV assessment. Limitations with computed tomography include the need to bolus potentially nephrotoxic iodinated contrast material and the need for ionizing radiation, which is a problem for radiosensitive patient populations, including children, and for serial surveillance studies. Although the patient must be able to lie flat and perform a breath hold, the scan process occurs over a shorter period compared with cardiac MRI. Furthermore, implanted devices do not prevent the use of computed tomography, and claustrophobia is rarely an issue given the short bore length.

Radionuclide Imaging

Radionuclide imaging can be used for the assessment of RV size, function, and infiltration.¹⁴⁴ It is less frequently used for these purposes in the contemporary era given its poorer spatial resolution compared with other imaging modalities and the need for ionizing radiotracers. However, radionuclide ventriculography can be more accurate than echocardiography in measuring RV volumes given its reliance on count density rather than on geometric assumptions, which may be stymied by complex RV geometry. Increased RV uptake of [¹⁸F]-2-fluoro-2-deoxy-D-glucose has been described in cases of PH, including its potential utility in tracking response to pulmonary vasodilator therapy.^{197,198} Technetium pyrophosphate imaging is a sensitive means of detecting certain infiltrative processes, particularly cardiac involvement by transthyretin amyloidosis. It is most frequently used via ventilation/perfusion scan to screen for chronic thromboembolic PH in patients with PH and RV enlargement detected by other imaging modalities.

Chest Radiograph

In cases of significant RV enlargement, the cardiac silhouette on a chest radiograph will have a globular appearance. Loss of the retrosternal airspace on a lateral projection also indicates RV enlargement. Rightward displacement of the cardiac silhouette, well beyond the spine, almost always represents RA enlargement (the alternative being a giant left atrium). With coexisting PH, the main PA will be enlarged and the distal PA branches may have a "pruned" appearance.^{199,200} Elevated CVP may sometimes be recognized by an enlarged azygous vein. Pulmonary vascular redistribution, increased interstitial markings, and Kerley lines are signs of pulmonary venous hypertension, evidence of which often diminishes as pulmonary vascular obstructive disease progresses and signs of RHF dominate those of LHF in the presence of chronic biventricular failure. Pleural effusions are frequent in the presence of severe HF, particularly when pulmonary and systemic venous pressures are both elevated.

Table 5. Hemodynamic Assessment of RH Function

Hemodynamic Parameters Associated With RV Function		
Variable	Calculation	Thresholds Associated With Clinical Events in Specific Populations
RAP	RAP (or CVP)	>15 mmHg (RHF after LVAD) ^{83,201}
Right-to-left discordance of filling pressures	RAP:PCWP	>0.63 (RHF after LVAD) ⁷⁶ >0.86 (RHF in acute MI) ²⁰²
PA pulsatility index	(PASP–PADP)/RAP	<1.0 (RHF in acute MI) ²⁰³ <1.85 (RHF after LVAD) ²⁰⁴
RV stroke work index	(MPAP–CVP)×SVI	<0.25–0.30 mmHg·L/m ² (RHF after LVAD) ^{205,206}
PVR	(MPAP–PCWP)/CO	>3.6 WU (RHF after LVAD) ²⁰⁷
PA compliance	SV/(PASP–PADP)	<2.5 mL/mmHg (RHF in chronic HF, RV-PA coupling in PAH) ^{26,115}

CO indicates cardiac output; CVP, central venous pressure; LVAD, left ventricular assist device; MI, myocardial infarction; MPAP, mean pulmonary artery pressure; PA, pulmonary artery; PADP, pulmonary artery diastolic pressure; PAH, pulmonary artery hypertension; PASP, pulmonary artery systolic pressure; PCWP, pulmonary capillary wedge pressure; PVR, pulmonary vascular resistance; RAP, right atrial pressure; RH, right-sided heart; RHF, right-sided heart failure; RV, right ventricular; SV, stroke volume; SVI, stroke volume index (SVI=cardiac index/heart rate); and WU, Woods units.

Adapted with permission from Kapur et al.²⁰⁸ Copyright © 2017, American Heart Association.

Hemodynamic Assessment of RV Function

Several hemodynamic variables have been identified as risk factors for the development of RHF, predominantly after LVAD surgery (Table 5).⁷⁷ As with imaging parameters of RV function, hemodynamic correlates are largely inconsistent across studies. Elevated RAP, particularly when this elevation is disproportionate relative to the rise in PCWP, is a marker of RVD.^{83,201} A normal RA/PCWP ratio is ≈0.5; higher ratios imply RVD.^{209,210} A preoperative RA/PCWP ratio >0.63 is associated with RHF after LVAD surgery.⁷⁶ PA pulsatility is another potential correlate of RHF.^{203,204} PA pulse pressure index, defined as the ratio of PA pulse pressure (PASP minus PA diastolic pressure) to RAP, was recently proposed as a sensitive marker of disproportionate RVD and a predictor of post-VAD RHF.²⁰³ This metric, however, has also yet to be validated in larger, prospective cohorts. RV stroke work index [(mean PAP–RAP)×SV index] is an established marker of RV function. SV index is calculated by dividing cardiac index by heart rate. RV stroke work index is influenced by preload, however, and its calculation is dependent on multiple measured parameters susceptible to acquisition error.^{201,211–213}

Risk Models of RHF

Durable mechanical circulatory assist devices are increasingly offered to patients with advanced HF as a bridge to transplantation or as long-term destination therapy.²¹⁴

Despite technological advances in the use of continuous-flow LVADs, RHF remains a major cause of morbidity and mortality after LVAD implantation.^{179,215} Postoperative RHF can occur immediately, before the patient leaves the operating room, whereas in other cases, it may develop over weeks, months, or even years as a result of the progression of underlying myocardial disease, worsening TR, or PH.⁸⁴ Several clinical prediction scores have been developed to facilitate preoperative identification of patients at risk for post-LVAD RHF.^{76,78,83,201,205,207,216} Age, vital signs, invasive hemodynamic metrics, echocardiographic parameters, indexes of end-organ function, and the need for cardiorespiratory support have been used to identify high-risk individuals. Although these scores perform well in their derivation cohorts, they perform less well in external validation studies.²¹⁷ The complex physiology of RHF complicates accurate prediction of postoperative events, and these scores are unable to incorporate intraoperative parameters or events that can precipitate ARHF. Such events include volume loading from transfusions and short-term increases in PVR secondary to hypoxia, acidemia, or increases in airway pressure from mechanical ventilation.⁷⁷ Furthermore, prediction models cannot model RV-LVAD interactions and the direct impact of LVAD hemodynamics on RV function, including volume loading of the right-sided circulation and geometric changes in the contractile pattern of the interventricular septum that affect RV SV.²⁷ Other limitations of risk scores include the heterogeneity of populations studied and the variability in definitions of RHF used.²¹⁷

The overall clinical profile of the patient tends to be the strongest correlate of the failing RV, with greater acuity of illness being associated with more severe RHF. Severe RHF with diminished systemic perfusion is commonly characterized by a state of vasodilation, interstitial fluid leakage, and systemic inflammation, potentially with fever in the absence of infection.²¹⁸ Profound vasodilation can be present and should not be mistaken for alternative causes of distributive shock. Refractory cardiogenic shock is generally accompanied by severe biventricular dysfunction.²¹⁹ Given the known limitations of echocardiographic and hemodynamic variables, no parameter in isolation can adequately identify clinically significant RHF with a high sensitivity or specificity. The assessment of RV function requires a multimodality approach with careful evaluation of trends across hemodynamic, hematologic, and imaging parameters. Confidence in the clinical diagnosis of RHF increases when multiple parameters across modalities collectively suggest a state of RVD.

Biomarkers to Assess RV Function

There has been much interest in identifying biomarkers such as NT-proBNP (N-terminal pro-BNP) to help guide

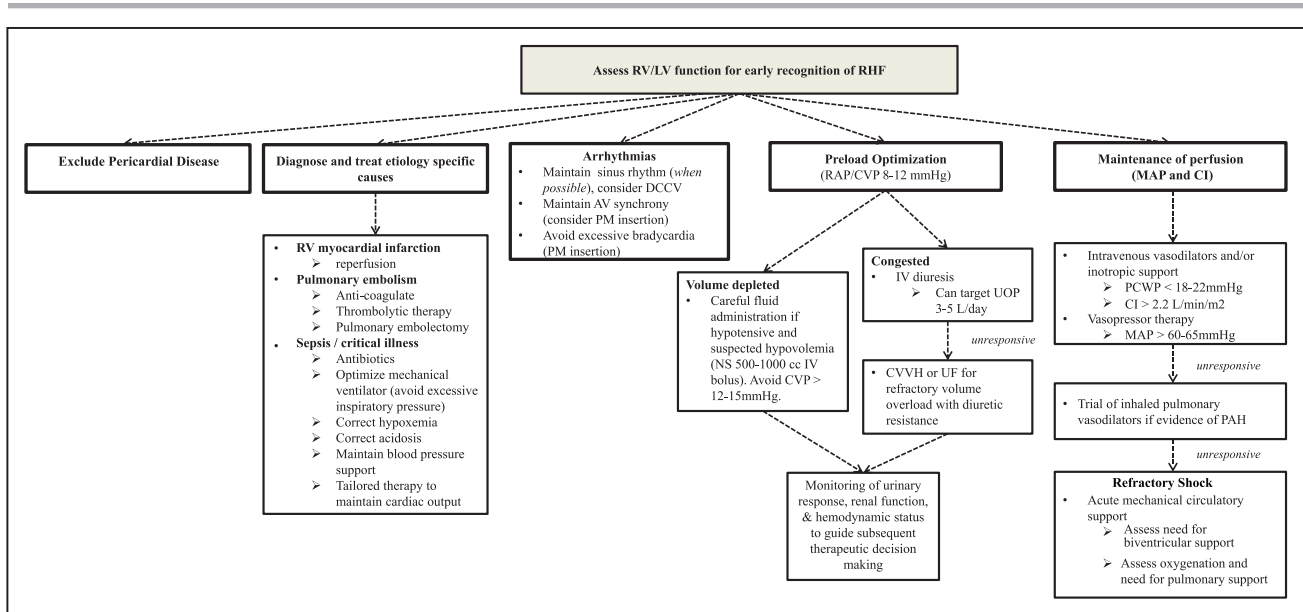


Figure 11. Management of acute right-sided heart failure.

All management must be undertaken with an awareness of the patient's hemodynamic status. If this status is not clear clinically, then invasive assessment/monitoring should be undertaken. Hemodynamic targets provide rough guidelines for tailored therapy. AV indicates atrial-ventricular; CI, cardiac index; CVP, central venous pressure; CVVHF, continuous venovenous hemofiltration; DCCV, direct current cardioversion; IV, intravenous; LV, left ventricular; MAP, mean arterial pressure; NS, normal saline; PAH, pulmonary arterial hypertension; PCWP, pulmonary capillary wedge pressure; PM, pacemaker; RAP, right atrial pressure; RHC, right-sided heart catheterization; RV, right ventricular; UF, ultrafiltration; and UOP, urine output.

the identification and management of patients with HF. The focus, however, has historically been on identifying patients with LV dysfunction.²²⁰ NT-proBNP may also be useful in patients with predominantly RHF but is relatively nonspecific.^{118,221} Likewise, elevated BNP is observed in both LH and right-sided heart dysfunction and is not a reliable marker to distinguish the level of dysfunction within each ventricle.^{222,223} BNP, however, has emerged as a useful marker of prognosis in RHF accompanying PAH.²²⁴ The reliability of other biomarkers such as creatine phosphokinase-MB and troponins is less well established in the setting of RHF.^{225–227} Elevated BNP and troponin have adverse prognostic implications in the setting of acute PE.^{228,229}

Several small, predominantly exploratory studies have examined RV-specific gene expression patterns, microRNAs, exosomes, and proteins associated with RHF, primarily in patients with CHD and PH.^{230–238} One study used unbiased RNA sequencing to identify several differentially expressed genes in patients with RVD.²³⁹ Of these, *STEAP4*, *SPARCL1*, and *VSIG4* were differentially expressed between the RV and LV, suggesting their role as RV-specific biomarkers. Lewis et al²⁴⁰ identified 21 metabolites that were closely related to hemodynamic indexes of RVD using mass spectrometry-based methods in 11 subjects with PH. Similarly, early animal studies have identified unique microRNAs associated with RV but not LV failure.^{238,241} Identifying novel RV-specific biomarkers may lead to targeted therapies for RHF.²⁴²

MEDICAL MANAGEMENT OF ARHF

Management of ARHF focuses on management of volume and preload, myocardial contractility, and RV afterload with pharmacotherapy and, if needed, MCS (Figure 11).^{243,244} Abnormalities in the pulmonary circulation and LV filling should be identified as targets for reducing RV afterload and augmenting RV function.

Volume Management

Volume management is a critical consideration in ARHF, and the volume status of the patient should be determined on initial examination.²⁴⁵ A primary goal should be a reduction in left atrial pressure with an aim of reducing congestion and pulsatile RV loading.¹⁶ In the absence of gross volume overload, evident by findings such as peripheral edema, careful inspection of the jugular venous pulsation should allow the clinician in most cases to determine the presence or absence of elevated CVP. This examination may be confounded by the large A waves of atrial contraction against a poorly compliant RV and large V waves caused by a poorly compliant RA or significant TR. Hemodynamic monitoring with a central venous catheter or PA catheter can be informative if the volume status is uncertain or if a patient has hemodynamic instability or worsening renal function in response to therapy.^{210,245}

The teaching that ARHF is a preload-dependent condition requiring volume loading is overly simplistic.

Although it may be reasonable to consider a small intravenous fluid bolus in the setting of ARHF complicated by hypotension, excess RV preload can lead to further clinical deterioration if it results in increased RV dilation, TR, RV afterload, and myocardial wall tension causing ischemia.^{18,246–248} As the RV dilates, the interventricular septum is pushed leftward in diastole. Limits of pericardial compliance result in RV constraint, causing impaired LV filling and a reduction in CO. This ventricular-interdependent effect is often more important than impaired RVEF in reducing CO. If the CVP exceeds 8 to 12 mm Hg, the patient will likely benefit from decongestion to restore more favorable intraventricular loading conditions and normalized interventricular interaction.²⁴⁹ Invasive hemodynamic monitoring is very useful to help determine the optimal RAP needed to maintain appropriate preload. Decongestion leads to RV decompression, reduced ventricular interdependence, downward displacement of the effective LV diastolic PV curve, improved LV filling, and augmentation of SV, CO, and BP.

Diuretics

Diuretic resistance can be a significant barrier to effective therapy in the setting of acute decompensation.^{250,251} Patients may not respond to high doses of intravenous loop diuretics because of a combination of factors, including elevated CVP and renal venous congestion, hypotension, low CO, and oliguric acute kidney injury.²⁵² Although efficacy has not been clearly demonstrated, there is mounting evidence for the safety of an early, aggressive high-dose diuretic strategy, with rapid titration in patients failing to respond to initial interventions^{159,160} (Table 6²⁵³). It is reasonable to consider adding a thiazide diuretic to augment natriuresis with intravenous loop diuretics.^{160,254} Aldosterone antagonists may help to maintain potassium homeostasis from potassium losses, although a trial of high-versus low-dose spironolactone in acute HF did not lead to improved clinical outcomes.²⁵⁵ Likewise, carbonic anhydrase inhibitors can improve the hypochloremic metabolic alkalosis resulting from aggressive loop and thiazide diuresis.

Diuretics should not be held in a hypotensive patient who is clearly volume-overloaded. Hypotension in this setting is a marker of a critically ill patient, and measures should be taken to support the BP with vasoactive therapies while concomitantly attempting to improve clinical congestion with diuretic or renal replacement therapies. Hypotension requiring vasoconstrictors and persistent poor hemodynamics should prompt strong consideration for MCS.

Renal Replacement Therapies

Among patients who fail to respond to escalating diuretics therapy, continuous veno-venous hemofiltration or ultrafiltration may be needed to mechanically re-

Table 6. Stepped Pharmacological Care: Treatment Algorithm From the CARRESS-HF Trial

Stepped Pharmacological Care Treatment Algorithm		
UO goals to be assessed daily from randomization to 96 h		
UO >5 L/d→reduce current diuretic regimen if desired		
UO 3–5 L/d→continue current diuretic regimen		
UO <3 L/d→see diuretic grid		
24-h assessment		
UO recommendations as above		
Advance to next step on grid if UO <3 L/d		
48-h assessment		
UO recommendations as above		
Advance to next step on grid if UO <3 L/d		
Consider dopamine or dobutamine at 2 µg·kg ⁻¹ ·h ⁻¹ if SBP <110 mm Hg and EF <40% or RV systolic dysfunction		
Consider nitroglycerin or nesiritide if SBP >120 mm Hg (any EF) and severe symptoms		
72- and 96-h assessments		
UO recommendations as above		
Advance to next step on grid if UO <3 L/d		
Consider dopamine or dobutamine at 2 µg·kg ⁻¹ ·h ⁻¹ if SBP <110 mm Hg and EF <40% or RV systolic dysfunction		
Consider nitroglycerin or nesiritide if SBP >120 mm Hg (any EF) and severe symptoms		
Consider hemodynamic-guided IV therapy, LVAD, dialysis, or ultrafiltration crossover		
Diuretic Grid		
	Suggested Dose	
Current Dose	Daily Loop Dose	Thiazide
A <80 mg	40 mg IV bolus 5 mg/h	None
B 81–160 mg	80 mg IV bolus+10 mg/h	5 mg metolazone once daily
C 161–240 mg	80 mg IV bolus+20 mg/h	5 mg metolazone twice daily
D >240 mg	80 mg IV bolus+30 mg/h	5 mg metolazone twice daily

CARRESS-HF indicates Cardiorenal Rescue Study in Acute Decompensated Heart Failure; EF, ejection fraction; IV, intravenous; Loop, loop diuretic dose in furosemide equivalents; LVAD, left ventricular assist device; RV, right ventricular; SBP, systolic blood pressure; and UO, urine output.

Reproduced from Bart et al²⁵³ with permission. Copyright © 2012, Elsevier.

move intravascular volume.^{245,254} Care should be taken not to remove fluid at a rate that exceeds the ability of the body to shift extravascular fluid into the intravascular space (the plasma refill rate) because such an excess is likely to result in new or worsening acute kidney dysfunction or injury.²⁴⁹ Markers of hemoconcentration include increases in hemoglobin, hematocrit, serum albumin, and total serum protein levels.^{158,256}

Ultrafiltration, which refers to the removal of isotonic fluid from the venous compartment via filtration of plasma across a semipermeable membrane, has been evaluated for the treatment of acute HF in multiple trials, although not specifically targeting subjects with RHF. The UNLOAD trial (Ultrafiltration Versus IV Diuretics in Patients Hospitalized for Acute Decompensated

Congestive Heart Failure) showed that early ultrafiltration produced greater weight and fluid loss compared with intravenous diuretics.²⁵⁷ The subsequent CARRESS-HF trial (Cardiorenal Rescue Study in Acute Decompensated Heart Failure), however, failed to demonstrate a benefit of ultrafiltration compared with a prescribed stepwise escalation of diuretic therapy based on urinary response in patients with acute HF and worsening kidney function.²⁵³ The diuretic algorithm (Table 6) included high doses of loop diuretics via both bolus and continuous infusion, the addition of thiazide diuretics, and selected intravenous inotrope and vasodilatory therapy. The AVOID-HF trial (Aquapheresis vs Intravenous Diuretics and Hospitalizations for Heart Failure) was designed to clarify the role of ultrafiltration in the management of acute HF but was terminated prematurely after the sponsor withdrew financial support.²⁵⁸ Whereas ultrafiltration may be helpful for fluid removal, available evidence does not support ultrafiltration as a first-line therapy for acute HF, and its use should be reserved for patients with persistent congestion refractory to escalation of diuretic therapies.

Vasoactive Therapies

Vasoactive medical therapy plays an important role in the management of ARHF. Global goals of therapy include reducing RV afterload, enhancing forward flow, and augmenting RV perfusion. There are few clinical trials to guide selection of vasoactive agents for ARHF, and most available data are from observational series.^{248,259,260} Medication choice relies on clinician experience, expert consensus opinion, and a firm understanding of the mechanism of action of chemotherapeutics and cardiovascular physiology. If a patient remains resistant to therapy, a PA catheter may be helpful to measure biventricular filling pressures and CO.²⁴⁵

Afterload Reduction

Correcting reversible causes of elevated PVR such as hypoxia and acidosis is a primary consideration. By relaxing vascular tone, vasodilators decrease systolic stress, enabling more effective systolic contraction. Nonselective vasodilators, including intravenous nitroglycerin and sodium nitroprusside, decrease both PVR and systemic vascular resistance, augmenting RV and LV SV and facilitating decongestion of the pulmonary and systemic circulations.^{261–263} Conceptually, vasodilator therapy may also relieve renal venous congestion and augment renal perfusion, although this strategy has not had positive results when studied in patients with acute HF and cardiorenal disease.¹⁶¹ Both nitroglycerin and sodium nitroprusside have short half-lives, which is advantageous in the event of hypotension.

Partially selective pulmonary vasodilators provide clinicians another option to decrease PVR in an effort to

improve RV SV.²⁶¹ For appropriately selected patients, available agents include inhaled and parenteral epoprostenol and nitric oxide.²⁶⁰ When long-term use of pulmonary vasodilatory therapy is being considered, it should be recognized that adverse effects have been observed in patients with LH disease.²⁶⁴ Inhaled agents have the advantage of avoiding systemic hypotension and worsening ventilation/perfusion mismatch. In primarily observational studies, short-term use of inhaled nitric oxide resulted in lower PVR, increased RV ejection, less RV distension, and improved oxygen consumption in patients with PH,^{265–267} RVMI, or PE^{268,269} and after LVAD implantation.^{270–272} In chronic HF, however, augmented RV CO from inhaled nitric oxide administration can precipitate acute pulmonary edema caused by an abrupt increase in the filling of an already volume-overloaded or poorly compliant LV.²⁷³

Oral agents include the phosphodiesterase-5 inhibitors (PDE5is). There are anecdotal reports of the beneficial impact of this class of medications on persistent PH after LVAD implantation complicated by ARHF,²⁷⁴ although these findings have been inconsistent.^{274,275}

Augment Contractility

In broad terms, inotropes augment myocardial contractility and augment failing RV SV while reducing RV end-diastolic volume and pressure. If the CO and BP are inadequate, inotropes should be considered to increase forward flow and possibly renal perfusion, recognizing the potential for inducing ischemia and arrhythmia.²⁷⁶ Milrinone and dobutamine have combined inotropic and vasodilator properties.^{277–279} Therefore, they can precipitate or worsen hypotension, although this is less likely if LV preload is adequate, and their use results in improved CO. Overall, direct comparisons of dobutamine and milrinone have shown similar clinical outcomes, including similar hemodynamic efficacy and arrhythmogenic potential.^{280,281}

Compared with dobutamine, milrinone leads to greater reductions in RV and LV end-diastolic pressure because of its potent pulmonary and systemic vasodilatory properties.^{282,283} In addition, milrinone less commonly causes tachycardia and may be considered a more rational choice in the setting of concomitant β -blocker therapy. Patients are also less likely to develop drug tolerance during prolonged infusions of milrinone. However, milrinone is more likely than dobutamine to provoke hypotension, particularly during bolus administration, which is subsequently less easily reversed by discontinuation of therapy. Given the long half-life, vasopressor support may be necessary to counteract vasoplegia in this setting. In addition, milrinone is partially renally cleared, and the estimated glomerular filtration rate must be considered in the determination of appropriate dosing.

Dobutamine has the advantage of a short half-life with rapid onset and offset of effect when discontin-

ued. It has only a modest direct vasodilator effect, mediated through β_2 -adrenergic peripheral vasodilation and thus a lower propensity for causing hypotension. Accordingly, it also has less effect on RV and LV afterload. In rare cases, dobutamine can cause an eosinophilic myocarditis, which may result in further deterioration of cardiac function.²⁸⁴

Although short-term administration of inotropic agents leads to hemodynamic improvement, long-term administration is associated with increased myocardial oxygen consumption and possibly increased mortality.^{276,285–288} Clinical guidelines recommend against the routine use of these agents in hospitalized patients with acute HF.²⁴⁵

Maintain Perfusion

In cases of hypotension, a drug with combined inotropic and vasopressor properties may be necessary to maintain adequate perfusion. Studies comparing outcomes of vasoactive agents are limited.²⁸⁹ Given the inherent inotropic properties and a dose-dependent vasopressor effect from α_1 agonism, dopamine, norepinephrine, and epinephrine are useful adjuncts to augment contractility in the setting of significant hypotension (systolic BP <80–90 mm Hg).^{290,291} Norepinephrine, for example, is a potent α_1 -receptor agonist with weaker β -receptor activity. Its administration leads to vasoconstriction with less prominent inotropic and chronotropic effects.

Recognizing the downside of increasing ventricular afterload, cases of refractory hypotension caused by peripheral vasodilation not responding to initial interventions may require the use of more pure vasopressors such as arginine vasopressin or phenylephrine.²⁹² Arginine vasopressin causes peripheral vasoconstriction with less impact on PVR and has beneficial effects supporting glomerular filtration via selective efferent arteriole constriction.^{292,293} These agents can augment mean arterial pressure to improve coronary artery perfusion and to reduce the risk of RV myocardial ischemia. Furthermore, supportive care with arginine vasopressin may be beneficial to limit the arrhythmogenic properties of catecholamines. Attempts should be made to wean off these treatments as rapidly as possible.

MEDICAL MANAGEMENT OF CRHF

Diuretics and Sodium Restriction

Similar to ARHF, diuretics remain the mainstay of therapy to treat congestion in CRHF.^{109,245} The intensity of diuretic therapy needed may vary according to the pathogenesis and severity of RHF, in addition to other factors such as coexisting renal disease. Because patients with RHF can have normal or low LV filling pres-

ures, clinical monitoring is necessary to prevent the development of prerenal azotemia and worsening renal function. Akin to ARHF, the goals of volume management in CRHF are to maintain sufficient preload for adequate cardiac filling while providing relief from RV volume overload, ventricular interdependence, and congestion.

Patients with CRHF frequently require large diuretic doses because of neurohormonal activation, including upregulation of the renin-angiotensin-aldosterone system axis, resulting in fluid and sodium retention.²⁹⁴ Congestion leads to increased volume of distribution, visceral edema causing impaired drug absorption and tubular drug delivery, and rebound sodium absorption in the hypertrophied distal nephron resulting from chronic Na-K-2CL blockade.^{252,295} Combination therapy including loop diuretics with thiazides may be helpful to augment natriuresis via sequential nephron blockade of sodium reabsorption.¹⁶⁰ Compared with furosemide, torsemide has more consistent absorption, especially during decompensation, and may be a preferred loop diuretic in CRHF.^{295,296}

According to the AHA/American College of Cardiology HF practice guidelines, sodium restriction is considered reasonable for patients with symptomatic HF to reduce symptoms of congestion.²⁴⁵ This recommendation is applicable to patients with symptomatic biventricular failure or isolated RHF, but it should be noted that no large-scale studies have demonstrated the safety or efficacy of sodium restriction in these populations. Clinicians should consider some degree (ie, <3 g/d) of sodium restriction in patients with symptomatic CRHF, although insufficiency of data and inconsistency of recommendations across guidelines make it difficult to provide precise recommendations.^{245,297} Similarly, fluid restriction (1.5–2 L/d) is considered reasonable in patients with refractory congestion and hyponatremia.²⁴⁵

Renin-Angiotensin-Aldosterone System Inhibitors, β -Blockers, and Hydralazine

Patients with biventricular dysfunction should be managed according to current practice guidelines for the management of chronic HF.^{245,298} In contrast to clear guidelines available for the management of HFrEF, less evidence is available to guide therapy of predominant RHF syndromes. Small-scale, single-center studies support the use of β -blockers,^{299–307} renin-angiotensin-aldosterone system inhibitors,^{308–311} and hydralazine,³¹² although results are inconsistent and vary across populations, depending on the pathogenesis of RHF.^{313–315} Early studies with systemic vasodilators, including hydralazine, produced inconsistent hemodynamic benefits in patients with PH.^{312,316,317} These agents were also frequently associated with serious adverse events.^{318–320} At present, the use of angiotensin-converting enzyme inhibitors, angiotensin-2 receptor blockers, and β -blockers

is not recommended in patients with PH regardless of RHF,³²¹ unless associated with hypertension, coronary artery disease, or LHF.¹⁰⁹ Prospective trials are also not available on the role of mineralocorticoid antagonists, including spironolactone, in the setting of RHF caused by PH.

Digoxin

Few studies have evaluated the use of digoxin use for CRHF. In early small studies, digoxin administration was associated with acute increases in CO or RVEF when administered to patients with PH and RVD.^{322–324} In other studies, digoxin in subjects with severe chronic airflow obstruction and RVD did not improve exercise capacity or RVEF.³²⁵ Likewise, a meta-analysis did not find digoxin to be associated with improvement in RVEF, exercise capacity, or New York Heart Association class.³²⁶ The clinical efficacy of digoxin remains unknown when administered long term in patients with RHF.³²⁷

Pulmonary Vasodilators

RHF is the final common pathway of PH, and vasodilator therapy relieving RV afterload has led to improved outcomes among group 1 patients with RHF.^{109,110} Medical therapy is also now available for treatment of refractory group 4 disease because riociguat, a soluble guanylate cyclase stimulator, has been shown to improve exercise capacity and PVR in patients with persistent chronic thromboembolic PH after pulmonary endarterectomy or in patients with inoperable disease.³²⁸ Although some trials have investigated pulmonary vasodilator therapy in patients with LH disease (group 2), these trials have not specifically targeted patients with evidence of PH. Comprehensive guidelines for the treatment of PH are available elsewhere.¹⁰⁹ The SOPRANO trial (Clinical Study to Assess the Efficacy and Safety of Macitentan in Patients With Pulmonary Hypertension After Left Ventricular Assist Device Implantation; NCT02554930) is actively investigating the potential for macitentan to lower PVR after LVAD.

Prostacyclin Analogs

The role of pulmonary vasodilators with prostacyclin analogs has been extensively studied in patients with group 1 PH, a significant proportion of whom have RVD. Among patients with PAH, intravenous epoprostenol has long-term clinical benefits, including improved survival and functional capacity.^{329,330} Compared with epoprostenol, other prostacyclin analogs, including treprostinil and iloprost, are more easily administered, have longer half-lives, and are able to be administered subcutaneously or by inhalation, with similar pharmacological actions and comparable hemodynamic effects. These agents also improve exercise tolerance

and HRQoL in group 1 PH.^{331–336} Parenteral prostanoids, however, remain the first-line therapy for patients with advanced disease.^{109,329}

In contrast, epoprostenol resulted in increased mortality when used to treat patients with LHF. A study of patients with severe HFrEF was terminated early because of a strong signal of decreased survival in patients treated with epoprostenol, despite increases in cardiac index and decreases in PCWP.²⁶⁴ Similarly, epoprostenol was not associated with improvement in distance walked or HRQoL in this population. The use of prostacyclin analogs is not recommended to treat group 2 PH.¹⁰⁹

Phosphodiesterase-5 Inhibitors

Oral PDE5is, including sildenafil and tadalafil, are established, effective, and well-tolerated therapy in patients with group 1 PH, either alone or as combination therapy with other vasodilators.^{337–340} PDE5is are associated with improvements in pulmonary vascular remodeling, improvements in RV contractility, and antiproliferative effects. They are also associated with improvements in exercise capacity and reduced rates of clinical events in patients with group 1 PH.^{337–345} These trials did not specifically select patients with RHF.

In smaller studies, PDE5i treatment has been demonstrated to improve exercise capacity, exercise hemodynamics, and HRQoL in patients with HFrEF and secondary PH (group 2)^{346–349}; however, these results await validation in large-scale multicenter randomized clinical trials. A multicenter trial of PDE5i treatment in patients with HFpEF failed to demonstrate improvement in exercise capacity or clinical status.³⁵⁰ This trial did not specifically select patients with evidence of PH or RHF. These agents are well tolerated and generally not associated with clinically significant reductions in BP, although decreases in BP may be accentuated by concomitant medications such as nitrates. This combination is specifically contraindicated. Although treatment with PDE5is is beneficial in patients with group 1 PH, their role in patients with isolated RHF or PH caused by LH disease remains uncertain.

Endothelin Receptor Antagonists

Endothelin-1, a potent vasoconstrictor, is implicated in the pathogenesis of PAH, and endothelin receptor antagonists targeting endothelin receptors type A and B have been extensively studied in group 1 PH. Whereas these studies did not explicitly select patients with PH with RHF, endothelin receptor antagonists are nonetheless associated with improvements in HF symptoms, exercise capacity, hemodynamics, and time to clinical worsening in group 1 patients.^{351–357}

Phase II studies of endothelin receptor antagonist administration in patients with HFrEF have documented short-term hemodynamic benefits.^{358,359} Unfortunately, phase III HFrEF trials failed to demonstrate improvements in morbidity or mortality in this population,

and increases in hepatic aminotransferases were reported.^{360,361} Because of hepatic congestion commonly seen in RHF, monitoring of liver function should be performed routinely in patients receiving endothelin receptor antagonist therapy.

Management of CRHF in CHD

Despite the significant contribution of RHF to premature morbidity and mortality in the acute CHD population, no adequately powered clinical trials have been completed to elucidate the role of medical therapies in this population. Furthermore, although many patients with acute CHD have RHF, these patients have typically been excluded from adult HF clinical trials. Thus, most standard HF therapies must be regarded as LV specific until proven otherwise. RHF resulting from pressure and volume loading may be seen after repair of TOF, pulmonary atresia, Ebstein anomaly, and pulmonary valvotomy for congenital PS.¹⁴ A thorough evaluation at a center specializing in HF of patients with CHD is recommended to identify and correct any hemodynamically-significant lesions contributing to RHF.³⁶² Specific populations of patients with CHD with RHF are reviewed briefly, including those with systemic RVD (in whom the RV is subaortic) in patients with a 2-ventricle circulation, those with a single-ventricle Fontan palliation circulation in whom the single ventricle is of RV morphology, and patients with a subpulmonary RV who are at risk for RV failure resulting from chronic PS or insufficiency. Comprehensive guidelines for the management of CHD are available elsewhere.^{363,364}

Patients with a systemic RV generally include those who have D-TGA that has been corrected with an atrial switch (Mustard or Senning) procedure or those with congenitally corrected L-TGA. A major determinant of survival in patients with a systemic RV is progressive systolic dysfunction of the systemic ventricle, which is often associated with progressive atrial-ventricular (tricuspid) valve regurgitation.¹⁴⁷ Worsening atrial-ventricular regurgitation can lead to deterioration in systemic ventricular function.^{365,366} Atrial-ventricular valve repair or replacement can improve the course of disease, particularly if performed before a decline in systemic RVEF.^{364,367,368} Cardiac resynchronization therapy has also been proposed in patients with CHD and systemic RVD.^{369–371} These preliminary studies have demonstrated markers of clinical improvement and improvement in RV function, although larger, longer-term studies are necessary. Few studies have addressed the role of standard HF therapies in this population. Given the physiological and anatomic differences in the RV, the response of the RV to standard HF therapies remains uncertain.

A number of small single-center reports suggest a potential clinical benefit of β -blockade in patients with

systemic RV, including improvement in symptoms and functional capacity, less systemic atrial-ventricular valve regurgitation, and potential beneficial effects of reverse RV remodeling.^{301,372,373} However, in the largest clinical trial to date, carvedilol did not improve HF outcomes or echocardiographic measures of ventricular function in a randomized, double-blind, placebo-controlled study of children with systolic HF, including those with a systemic RV.³⁷⁴ Indeed, there was instead a nonsignificant trend toward worsening of ventricular function in those patients who had a systemic RV and were treated with the β -blocker. Unfortunately, this study was not powered to fully address this question. Thus, routine use of β -blocker therapy cannot at this time be recommended in patients with systemic RVD³⁷⁵ and, if used, should be done so with caution. Furthermore, given an increased risk of sinus node dysfunction after atrial switch procedures in patients with D-TGA and a risk of heart block in those with L-TGA, β -blocker use requires close observation in these populations.³⁶²

There have been a number of small prospective randomized trials of angiotensin-2 receptor blocker^{311,376} and angiotensin-converting enzyme inhibitor^{309,315,377} administration in patients a systemic RV secondary to D-TGA or L-TGA. These trials have demonstrated mixed results and generally have not demonstrated a clear benefit or renin-angiotensin-aldosterone system inhibition in this population.³⁶² In a study of 26 patients with atrial switch repair for D-TGA, randomization to eplerenone was not associated with improvement in MRI parameters or RV function, although there was a trend toward improvement in biomarkers of collagen turnover.³⁷⁸

Patients with a single-ventricle circulation in whom the single ventricle is of RV morphology are at greater risk of HF than patients whose single ventricles are of LV morphology.³⁷⁹ Manifestations of a failing Fontan circuit are variable and may include systemic venous congestion, protein-losing enteropathy, plastic bronchitis, and cirrhosis. It is important to evaluate for potentially reversible conditions of HF in patients with a Fontan operation such as a correctable mechanical obstruction.³⁶² Even small pressure gradients in the low-pressure Fontan circuit can be deleterious to the single-ventricle circulation. Diuretics remain the mainstay therapy. In a multicenter randomized trial in infants with a single ventricle, enalapril did not improve ventricular function, HF severity, or somatic growth, although the duration of follow-up was too short to assess longer-term benefits.³⁸⁰ Similarly, a randomized, double-blind, placebo-controlled crossover trial of enalapril did not demonstrate improvement in functional capacity or hemodynamic measurements.³⁸¹ A crossover trial of oral sildenafil in patients with a Fontan circulation likewise did not lead to increased maximal oxygen consumption, although ventilatory efficiency was improved.³⁸²

Small series of patients with protein-losing enteropathy report a benefit of mineralocorticoid receptor antagonism with high-dose spironolactone.^{383,384} In a separate report, short-term therapy with spironolactone led to evidence of improved endothelial function and improvement in cytokine profiles in patients with a Fontan operation.³⁸⁵ Data, however, remain limited.

Finally, in patients with a pulmonary RV and CHD, for example, those after repair of TOF with a transannular patch or after repair of pulmonary atresia with an RV-PA conduit, the risk of RV dilation and RV failure persists. Few studies have shown definitive efficacy of any of the standard heart rate therapies in this patient population. In a study of adults with repaired TOF, the β -blocker bisoprolol did not improve echocardiographic or MRI parameters of RV size and function,³⁸⁶ and in a randomized trial of the angiotensin-converting enzyme inhibitor ramipril in repaired TOF and pulmonary regurgitation, RVEF was not increased, although in a subgroup of patients with restrictive RV physiology, ramipril decreased LV end-systolic volume index and increased LVEF.³⁸⁷

In summary, current data do not support the routine administration of standard HF drug therapies to patients with CHD with either a single RV or systemic RV or in patients with a pulmonary RV at risk for RV failure. Patients with CHD and HF should be cared for by clinicians with specific expertise in HF in the setting of CHD. Select patients may be considered for a trial of these LV-specific HF therapies with close monitoring in these settings.^{238,388,389} Ultimately, many appropriately selected patients with refractory symptoms require consideration for heart or heart-lung transplantation.³⁶³

MCS AND TRANSPLANTATION FOR RHF

MCS is reserved for patients refractory to optimal medical management of acute or chronic RHF.³²⁷ Appropriate timing of intervention to prevent delays in instituting MCS therapy is critical to its success in optimizing patient outcomes and preventing unnecessary morbidity and mortality. MCS is used for bridge to recovery; bridge to heart, lung, or heart-lung transplantation; or, in unique cases, as destination therapy (ie, permanent use). Recent literature suggests that 42% to 75% of patients with acute forms of RHF may recover sufficient function to allow MCS device explantation.^{390–392} Thus, appropriate application of MCS is essential to maximize the possibility of myocardial recovery. The appropriate type of MCS device used for RHF is determined by whether the pathogenesis is a primary RV insult or is the result of disease of the pulmonary vasculature or LV (Figure 12). Typically, primary pathogenesises of the RV

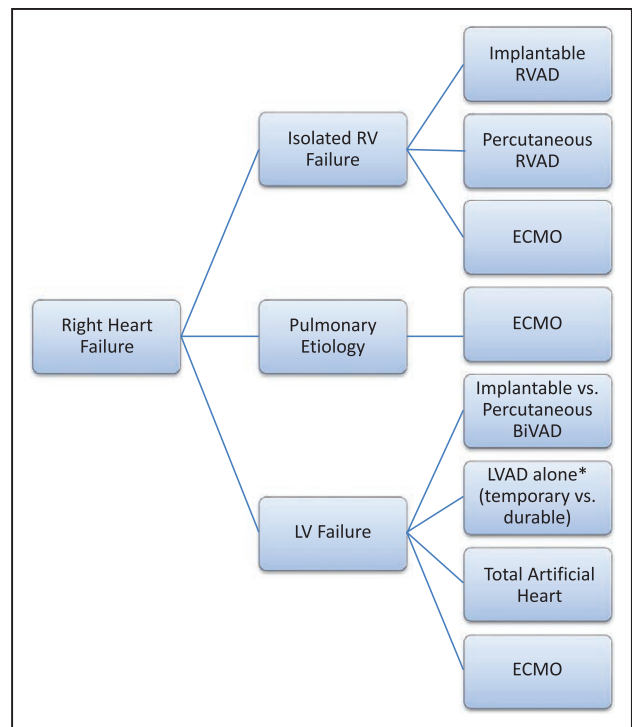


Figure 12. Mechanical circulatory support options based on the pathogenesis of right ventricular (RV) failure.

A challenge in the management of patients with biventricular dysfunction is discriminating between patients who have primary RV involvement necessitating true biventricular support and those with right-sided heart failure caused primarily by left-sided heart disease. Among this latter group, left ventricular (LV) mechanical circulatory support alone may provide adequate cardiac support given secondary unloading of the RV after LV decompression. Clinician experience and estimations of the probability of recovery guide decisions on the need for durable vs temporary support devices. The presence of pulmonary disease also influences device selection. BiVAD indicates biventricular assist device; ECMO, extracorporeal membrane support; LVAD, left ventricular assist device and RVAD, right ventricular assist device.

lend themselves to application with temporary implantable or percutaneous VADs.

ARHF secondary to obstructive diseases of the pulmonary vasculature may be more appropriately treated with extracorporeal membrane oxygenation (ECMO) as opposed to an RVAD because increased pulmonary blood flow from an RVAD will further increase PAP.³⁹³ There is a risk that when PH is present, excessive further increase in PAP could precipitate pulmonary hemorrhage. ARHF caused by LHF is often more suitably treated with temporary or durable MCS support of the LV, alongside temporary or durable RV support if needed (biventricular assist device support). Not all patients with biventricular dysfunction need biventricular support. However, determining which patients can be adequately supported by isolated LV support is challenging

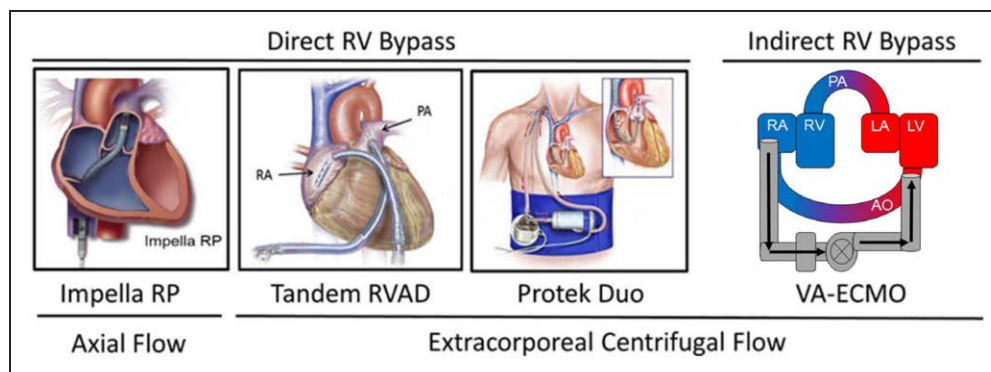


Figure 13. Mechanical circulatory support options for acute right ventricular (RV) support.

LA indicates left atrium; LV, left ventricle; PA, pulmonary artery; RA, right atrium; RVAD, right ventricular assist device; and VA-ECMO, veno-arterial extracorporeal membrane oxygenation. Adapted with permission from Kapur et al.²⁰⁸ Copyright © 2017, American Heart Association.

and requires the expert review of a multidisciplinary HF team experienced with MCS. Patients with biventricular dysfunction who receive isolated LV support should be closely monitored for clinical deterioration. Evidence of worsening RHF should lead to rapid deployment of RV mechanical support. Common indications for right-sided MCS use in ARHF include ARHF after LVAD, heart transplantation, RVMI, and myocarditis.

Temporary Support

Temporary MCS device options include newer percutaneous devices designed specifically for RV support and include the Impella RP (Abiomed Inc, Danvers, MA)³⁹⁴ and TandemHeart pVAD^{395–397} with the PROTEK Duo³⁹⁸ cannula (TandemLife, Inc, Pittsburgh, PA) (Figure 13). The Impella RP is a microaxial temporary extracorporeal VAD that is placed percutaneously through the femoral vein and positioned with the distal tip in the PA. The microaxial pump positioned within the catheter drains blood from the RA and pumps it into the PA. The efficacy and safety of this device were investigated in RECOVER RIGHT (The Use of Impella RP Support System in Patients With Right Heart Failure: A Clinical Safety and Probable Benefit Study), a prospective, multicenter, single-arm outcomes trial.³⁹⁴ Two groups of patients with RHF were enrolled, the first after LVAD placement and the second consisting of a mixture of patients after cardiectomy, after transplantation, and with acute MI. The primary outcome was a combined end point of either survival at 30 days or hospital discharge or survival to next therapy (ie, transplantation or surgical RVAD). Thirty patients were enrolled with 73% survival to discharge. The major complication was postoperative bleeding, which occurred in 36.6% of patients.

The PROTEK Duo³⁹⁸ cannula is a dual-lumen coaxial cannula positioned, via the internal jugular vein, with its distal tip in the PA and connected to an extracorporeal centrifugal blood pump. Because of its internal jug-

ular cannulation site, this configuration allows ambulation during support. These devices provide an option for MCS because of the ease of device insertion and removal, and they obviate the need for surgical sternotomy. These devices have corresponding variations designed specifically to support the LV so that biventricular assist device support can be achieved completely with a percutaneous option.^{399,400}

ECMO represents a viable alternative for acute MCS for ARHF that is either caused by primary RVD or is a consequence of PA disease, including in the presence of systemic oxygen desaturation.⁴⁰¹ There has been a significant adoption of ECMO in adults.⁴⁰² The benefits of ECMO are that it can be applied percutaneously at the bedside for initiation of emergent support, it provides biventricular support, and it addresses pathogenesis of the pulmonary system that are not addressed with isolated RV support. The more typical support configuration includes femoral venous drainage and arterial outflow to the femoral artery. This configuration can be achieved either percutaneously or by surgical procedure. Other configurations, including internal jugular cannulation for venous drainage and arterial outflow to the axillary artery, are also feasible to facilitate ambulation.⁴⁰¹ An RVAD-like configuration with RA inflow to PA outflow with an oxygenator has also been described. The complications of ECMO have been well chronicled in the literature.^{401,403}

Intermediate Support

Surgical options of intermediate-term RV support remain important, particularly for patients experiencing postcardiotomy failure to wean from cardiopulmonary bypass after open heart surgery, including heart transplantation, or for ARHF after implantation of a durable LVAD.^{76,216,392,404,405} Surgical implantation of an RVAD involves cannulation of the RA or RV for venous drainage and PA for arterial outflow. The cannulas are

connected to an extracorporeal centrifugal flow pump such as the CentriMag (Abbott Medical, Abbott Park, IL).^{392,406} Numerous reports detailing the use of a surgically implanted temporary RVAD after LVAD have demonstrated that this strategy is effective in supporting the patient through severe ARHF during the postoperative period. However, patients requiring RVAD after implantation of a durable LVAD have consistently worse outcomes related to bleeding complications and hepatic and renal dysfunction compared with those who do not need an RVAD.^{76,205,214} Although effective, a surgical RVAD typically requires a repeat sternotomy if not placed at the same time as the LVAD, and a second surgery is usually required to remove the device at the time of RV recovery.

Long-Term Support

Long-term, durable MCS device options for irrecoverable forms of RHF are limited, and destination therapy for chronic advanced RHF is not well studied.⁴⁰⁷ Whether MCS with newer, durable, implantable continuous-flow VADs could be of benefit in patients with refractory CRHF with a contraindication to transplantation is unknown. The off-label use of durable MCS devices in the setting of RHF caused by chronic PH is controversial, and rigorous data on its efficacy in this setting are lacking.

Typically, durable devices used for long-term or permanent RV support have been designed for LV support, and their use for the RV represents an off-label or unapproved indication. The most frequently used durable VAD for chronic RV support has been the HeartWare HVAD (Medtronic, Inc, Minneapolis, MN), which is a small, continuous-flow centrifugal device with magnetic and hydrodynamic levitation of the internal impeller.⁴⁰⁸ Small, single-center observational series have demonstrated successful application of this device for long-term RV support. Typically, the durable RVAD has been used in conjunction with a durable LVAD. The inflow cannula of the device has been positioned within the diaphragmatic surface of the RV, anterior surface of the RV, or RA, with outflow connected to the PA. However, the use of durable continuous-flow rotary pumps for RV support raises many issues of feasibility, including the increased risk of thrombus generated in the venous system and embolizing to the pump.

The total artificial heart (TAH) represents an alternative therapy for biventricular support for the failing RV and LV. The most used TAH is the Syncardia TAH-t (Syncardia Systems, LLC, Tucson, AZ).^{408,409} The Syncardia TAH-t is a pneumatically-driven pulsatile device currently approved for bridge to transplantation in the United States. The device is available in 50- and 70-cm sizes and is being investigated for destination therapy indication. The use of the TAH may be advantageous

over biventricular assist device support options in clinical situations such as ARVC, restrictive cardiomyopathies, biventricular failure with significant intraventricular thrombus burden, very large body size, and failed transplantation.⁴⁰⁸

Transplantation

In patients with advanced refractory CRHF, transplantation can be considered after the exclusion of all reversible causes of CRHF and careful assessment of comorbidities, including cachexia, cardiac cirrhosis, chronic kidney disease, protein malnutrition, and other potential contraindications to transplantation. In patients with PH and CRHF (RAP >15 mm Hg and a cardiac index <2.0 L·min⁻¹·m⁻²), prognosis is generally poor, and referral for transplantation should be considered. In carefully selected patients with CRHF from severe pulmonary vascular disease, heart-lung or double-lung transplantation can be considered.^{18,110,363,410,411}

Outcomes for isolated heart transplantation are generally excellent, and 1-year survival is ≈90% in the most recent era for all patients according to registry data.^{410,412} However, the presence of RVAD support before heart transplantation is associated with a relative mortality hazard of 3.03 after transplantation.⁴¹⁰ Similarly, outcomes have improved after lung transplantation, with a 1-year survival of ≈84% for all patients reported in the most recent era.⁴¹¹

Palliative Interventions

Balloon atrial septostomy (BAS) represents a percutaneous option to treat RHF caused by severe PH, creating a surgical right-to-left shunt to unload the RV. The associated decrease in systemic oxygenation must be outweighed by the increased oxygen delivery mediated by the increased CO. BAS is typically used as a bridge to lung transplantation or as a palliative measure in refractory PH.⁴¹³ Preoperative optimization of filling pressures is crucial, and perioperative inotropic support may be necessary. BAS is contraindicated in severe RHF and should not be offered to patients with RAP >20 mm Hg, significant hypoxemia (<90% on room air), or PVR index >4400 dynes·s·cm⁻⁵/m². Surgical shunt placement between the left PA and descending aorta (Potts shunt) has also been described as a palliative intervention for refractory PH.⁴¹⁴

SURGICAL MANAGEMENT OF VALVULAR LESIONS

TV Surgery

TR is a common valve disorder; however, data clarifying indications for interventions or outcomes after TV

repair or replacement are less robust compared with disorders of the aortic or mitral valves. Severe TR (effective regurgitant orifice $>0.4 \text{ cm}^2$) can result in significant symptoms and mortality but remains undertreated.^{101,415,416} Despite the morbidity and mortality associated with significant TR, patients are rarely referred for isolated surgical intervention, and most surgeries of the TV are performed in the context of other planned cardiac procedures. Patients with severe TR and signs or symptoms of CRHF are classified as having stage D TV disease.⁴¹⁵ Recent data have demonstrated that isolated TV surgery can be performed with acceptable risk if patients undergo intervention before the onset of advanced HF or severe RVD.⁴¹⁷ Patients with RHF caused by severe TR from implantable cardioverter-defibrillator or pacemaker leads should also be considered for surgical evaluation.⁴¹⁸

In the setting of concomitant valve disease, severe TR of either a primary or functional nature may not improve after treatment of the left-sided valve lesions and reduction of RV afterload.⁴¹⁶ The addition of TV repair during surgery for left-sided valve disease does not add appreciable risk, whereas reoperation for severe, isolated TR after left-sided valve surgery is associated with a perioperative mortality rate of up to 25%.⁴¹⁶ These observations have prompted clinicians toward a higher rate of TV intervention during surgery for left-sided valve disease. Moderate or even mild degrees of functional TR left uncorrected at the time of left-sided valve surgery may progress over time in approximately a quarter of patients and result in reduced long-term functional outcome and survival.⁴¹⁹ Risk factors for persistence or progression of TR include TV annular dilatation $>40 \text{ mm}$ or 21 mm/m^2 on transthoracic echocardiogram, significant RVD or dilatation, significant tricuspid leaflet tethering, atrial fibrillation or PH at the time of left-sided valve surgery, rheumatic or functional origin of the mitral disease, or history of RHF.⁴¹⁹

The overwhelming majority of cases requiring surgery for TR are amenable to repair. Singh et al⁴²⁰ demonstrated that TV repair is associated with improved perioperative, midterm, and event-free survival compared with TV replacement for patients with organic tricuspid disease. Repair was associated with greater recurrence of TR, although reoperation rates and functional class were similar. Thus, repair should be pursued whenever possible.⁴²⁰ Repair should include an annuloplasty ring because it is associated with improved survival and event-free survival compared with other techniques not using an annuloplasty ring (eg, De Vega technique).⁴²¹ The durability of TV repair may be limited, even in circumstances when an annuloplasty ring is used, because of increased preoperative TV leaflet tethering height and area, low LVEF, and increased RV pressure. These factors are associated with a greater degree of TR during follow-up.⁴²¹ Patients with significant tethering, sig-

nificant distortion of the TV, significant RVD, or severe PH may require TV replacement to avoid long-term failure of repair and worse clinical outcome. Percutaneous options for TV replacement may become available in the future.^{99,422} Although the impact of concomitant TV repair at the time of LVAD implantation on long-term outcomes remains poorly defined, anecdotally, most operators err toward addressing moderate or worse TR at the time of LVAD surgery.^{423–425} Recommendations from the AHA/American College of Cardiology guideline for TV surgery are provided in Figure 14.⁴¹⁵

Tricuspid Stenosis

Surgery for severe tricuspid stenosis (TS) is generally performed in conjunction with surgery for left-sided valve disease, most commonly mitral valve stenosis. TS is usually caused by rheumatic heart disease; carcinoid disease is a less common cause. TV surgery for relief of symptomatic TS is preferred over percutaneous balloon tricuspid commissurotomy because most cases of severe TS have important concomitant TR (rheumatic, carcinoid, or congenital). Indications for surgery for TS include stage C or D TS characterized by $T1/2 \geq 190$ milliseconds and valve area $<1.0 \text{ cm}^2$ with or without the presence of symptoms.⁴¹⁵ Repair for primary TS is feasible but has a higher rate of need for reoperation.

Pulmonary Insufficiency

Significant PV regurgitation (PR) is uncommon but is most typically observed after surgery for TOF or other congenital lesions. Residual PR after repair of TOF is initially well tolerated but eventually contributes to RV enlargement, RVD, decreased exercise tolerance, increased incidence of arrhythmias, and increased risk of sudden death.^{363,426,427} PR is less commonly seen in association with infective endocarditis or carcinoid syndrome. Secondary PR after long-standing PH and annular dilation is uncommon. Primary treatment of PR in this setting should focus on the cause(s) of elevated PAP.

Surgery for PR is considered when symptoms or signs of RVD have occurred and PR is severe. Surgery is generally recommended for asymptomatic severe PR in the setting of severe RV dilation or dysfunction (cardiac MRI-derived RV end-diastolic volume index $>150 \text{ mL/m}^2$, RV end-systolic volume index $>80 \text{ mL/m}^2$, RVEF $<47\%$) or symptomatic atrial and ventricular arrhythmias.^{363,426,427} Current guidelines support surgery for severe PR along with (1) moderate to severe RVD (Class IIa; Level of Evidence B), (2) moderate to severe RV enlargement (Class IIa; Level of Evidence B), (3) symptomatic or sustained atrial and ventricular arrhythmias (Class IIa; Level of Evidence C), or (4) moderate to se-

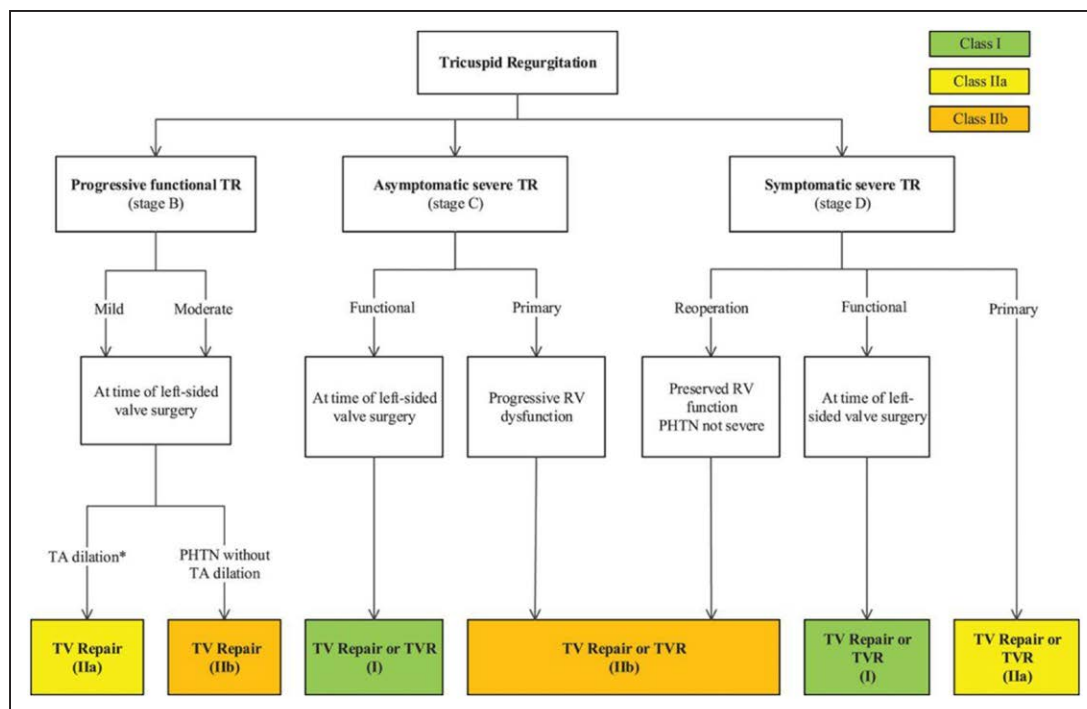


Figure 14. Indications for surgery for tricuspid regurgitation (TR).

Tricuspid annular (TA) dilation is defined by >40 mm on transthoracic echocardiography (>21 mm/m²) or >70 mm on direct intraoperative measurement. LV indicates left ventricular; PHTN, pulmonary hypertension; RV, right ventricular; TV, tricuspid valve; and TVR, tricuspid valve replacement. Reproduced with permission from Nishimura et al.⁴¹⁵ Copyright © 2014, American Heart Association.

vere TR (Class IIa; Level of Evidence B). Transcatheter PV replacement is also now possible. In patients with concomitant severe TR undergoing transcatheter PV replacement, transcatheter PV replacement resulted in a clinically relevant reduction in TR that persisted over 5 years of follow-up.⁴²⁸

Pulmonic Stenosis

PS is typically caused by CHD. Acquired types are less common and include carcinoid disease or obstructing vegetations from endocarditis or obstructing tumors. PS may be treated with either percutaneous balloon PV commissurotomy or valve replacement. Surgical therapy, as opposed to percutaneous therapies, is recommended for patients with severe PS and associated hypoplastic pulmonary annulus, severe PR, subvalvular PS, or supra-annular PS. Surgical therapy is also generally preferred for a dysplastic PV or when there is associated severe TR or the need for a surgical Maze procedure (Class I; Level of Evidence C).³⁶³

CONCLUSIONS AND FUTURE DIRECTIONS

We must continue to enhance our understanding of pathophysiology. It is remarkable how misunderstood

are some basic concepts of right-sided heart dysfunction among practicing clinicians and the impact that such misunderstanding can have on appropriate patient management. Acute right-sided heart syndromes such as acute RV infarction or acute PE must be recognized principally as syndromes of impaired LH filling caused by direct ventricular interdependence to avoid excessive volume administration and to turn more rapidly to RV mechanical unloading and support. Likewise, central and renal venous engorgement must be recognized as at least as important as impaired forward output in the pathogenesis of the cardiorenal syndrome.

Our management of these conditions remains suboptimal, and new therapies, pharmacological and device based, should be sought. For example, as we continue to grow in our understanding of the interdependency of LH function, right-sided heart function, and renal hemodynamics, it may be possible to develop drugs and devices tailored to alleviation of diuretic resistance and the cardiorenal syndrome. Ultimately, however, it may be time that matters most because unrecognized and undertreated RHF inevitably results in sequelae of end-organ damage caused by chronic congestion and acute malperfusion. Early identification is critical to improve care targeting this complex syndrome, which remains frequently misjudged given the diverse pathways and pathological processes leading to its condition.

We should improve our ability to distinguish among RHF caused by LHF, pulmonary vascular obstructive disease, and intrinsic RV pathology through novel hemodynamic indexes and biomarkers of load-dependent and load-independent forms of RHF. Although we currently define pulmonary vascular obstruction as either fixed or reversible, perhaps the notion of fixed pathology merely connotes our pathophysiological naiveté. Improved understanding of the pathobiology of pulmonary microvascular disease will lead us to novel approaches for reversing fixed pathology.

Although we have come a long way in RV imaging, more advances are warranted, particularly in relating measures of systolic and diastolic performance to indexes of load. Although we have made enormous strides in advanced MCS, we continue to struggle with patients who have biventricular disease. There is room for considerable advance in biventricular support technologies, particularly durable devices with applicability to broader patient populations.

We have seen progressive advances in our understanding and managing of RHF, but we have much more to learn. The future holds many diagnostic and therapeutic advances that will markedly expand our ability to tackle these many complex clinical challenges.

ARTICLE INFORMATION

The American Heart Association makes every effort to avoid any actual or potential conflicts of interest that may arise as a result of an outside relationship or a personal, professional, or business interest of a member of the writing panel. Specifically, all members of the writing group are required to complete and submit a Disclosure Questionnaire showing all such relationships that might be perceived as real or potential conflicts of interest.

This statement was approved by the American Heart Association Science Advisory and Coordinating Committee on October 27, 2017, and the American Heart Association Executive Committee on December 11, 2017. A copy of the document is available at <http://professional.heart.org/statements> by using either "Search for Guidelines & Statements" or the "Browse by Topic" area. To purchase additional reprints, call 843-216-2533 or e-mail kelle.ramsay@wolterskluwer.com.

The American Heart Association requests that this document be cited as follows: Konstam MA, Kiernan MS, Bernstein D, Bozkurt B, Jacob M, Kapur NK, Kociol RD, Lewis EF, Mehra MR, Pagani FD, Raval AN, Ward C; on behalf of the American Heart Association Council on Clinical Cardiology; Council on Cardiovascular Disease in the Young; and Council on Cardiovascular Surgery and Anesthesia. Evaluation and management of right-sided heart failure: a scientific statement from the American Heart Association. *Circulation*. 2018;137:e578–e622. DOI: 10.1161/CIR.0000000000000560.

The expert peer review of AHA-commissioned documents (eg, scientific statements, clinical practice guidelines, systematic reviews) is conducted by the AHA Office of Science Operations. For more on AHA statements and guidelines development, visit <http://professional.heart.org/statements>. Select the "Guidelines & Statements" drop-down menu, then click "Publication Development."

Permissions: Multiple copies, modification, alteration, enhancement, and/or distribution of this document are not permitted without the express permission of the American Heart Association. Instructions for obtaining permission are located at http://www.heart.org/HEARTORG/General/Copyright-Permission-Guidelines_UCM_300404_Article.jsp. A link to the "Copyright Permissions Request Form" appears on the right side of the page.

Disclosures

Writing Group Disclosures

Writing Group Member	Employment	Research Grant	Other Research Support	Speakers' Bureau/Honoraria	Expert Witness	Ownership Interest	Consultant/Advisory Board	Other
Marvin A. Konstam	Tufts Medical Center	None	None	None	None	None	None	None
Michael S. Kiernan	Tufts Medical Center	None	None	None	None	None	Abbott*; Medtronic*	None
Daniel Bernstein	Stanford University	Department of Defense (grant to explore mechanisms of defective angiogenesis in right ventricular failure)†	None	None	None	Regencor*	None	None
Biyeem Bozkurt	Baylor College of Medicine and MEDVAMC	None	None	None	None	None	None	None
Miriam Jacob	Cleveland Clinic Foundation Heart and Vascular Institute	None	None	None	None	None	None	None
Navin K. Kapur	Tufts Medical Center	None	Abiomed†; Cardiac Assist†; St. Jude (preclinical research)†; Maquet (translational research)†	Abiomed†; Heartware*; Maquet*; St. Jude*	None	None	Abiomed*; Cardiac Assist*; Maquet*; St. Jude*	None
Robb D. Kociol	Beth Israel Deaconess Medical Center	DCRI (steering committee—connect-HF)*	HFSA (executive board, speaker at meeting) *	AHA spotlight series—HF*	None	None	None	None
Eldrin F. Lewis	Brigham & Women's Hospital	Amgen†; Novartis†; Sanofi†	None	None	None	None	Novartis†	None

(Continued)

Writing Group Disclosures Continued

Writing Group Member	Employment	Research Grant	Other Research Support	Speakers' Bureau/Honoraria	Expert Witness	Ownership Interest	Consultant/Advisory Board	Other
Mandeep R. Mehra	Brigham and Women's Hospital and Harvard Medical School	None	Heart Failure Society of America (president)*; International Society for Heart and Lung Transplantation (editor-in-chief of the <i>Journal of Heart and Lung Transplantation</i>)†	None	None	NuPulse, Inc†	Abbott*; Johnson and Johnson (Janssen)*; Medtronic*; Mesoblast*; Portola*	None
Francis D. Pagani	University of Michigan Health System Cardiac Surgery	None	None	None	None	None	None	None
Amish N. Raval	University of Wisconsin	None	None	None	None	None	None	None
Carey Ward	Duke University	None	None	None	None	None	None	None

This table represents the relationships of writing group members that may be perceived as actual or reasonably perceived conflicts of interest as reported on the Disclosure Questionnaire, which all members of the writing group are required to complete and submit. A relationship is considered to be "significant" if (a) the person receives \$10 000 or more during any 12-month period, or 5% or more of the person's gross income; or (b) the person owns 5% or more of the voting stock or share of the entity, or owns \$10 000 or more of the fair market value of the entity. A relationship is considered to be "modest" if it is less than "significant" under the preceding definition.

*Modest.

†Significant.

Reviewer Disclosures

Reviewer	Employment	Research Grant	Other Research Support	Speakers' Bureau/Honoraria	Expert Witness	Ownership Interest	Consultant/Advisory Board	Other
Robert P. Frantz	Mayo Clinic	None	None	None	None	None	Actelion (unpaid)*; Arena Pharmaceuticals*; Bayer (unpaid)*; Abbott*; Novartis*; United Therapeutics (unpaid)*	None
Jason N. Katz	University of North Carolina	None	None	None	None	None	None	None
Robert L. Kormos	University of Pittsburgh	None	None	None	None	None	None	None
Gregory D. Lewis	Massachusetts General Hospital	NHLBI (investigation of markers of right ventricular dysfunction)†; NHLBI (evaluation of metabolic disease in relation to pulmonary hypertension in heart failure)*	Bayer (clinical trial research)†	None	None	None	Ironwood*	None
Myung Park	Houston Methodist DeBakey Heart & Vascular Center	None	None	Bayer*	None	None	Actelion*; Bayer*	None

This table represents the relationships of reviewers that may be perceived as actual or reasonably perceived conflicts of interest as reported on the Disclosure Questionnaire, which all reviewers are required to complete and submit. A relationship is considered to be "significant" if (a) the person receives \$10 000 or more during any 12-month period, or 5% or more of the person's gross income; or (b) the person owns 5% or more of the voting stock or share of the entity, or owns \$10 000 or more of the fair market value of the entity. A relationship is considered to be "modest" if it is less than "significant" under the preceding definition.

*Modest.

†Significant.

REFERENCES

- Mehra MR, Park MH, Landzberg MJ, Lala A, Waxman AB; International Right Heart Failure Foundation Scientific Working Group. Right heart failure: toward a common language. *J Heart Lung Transplant*. 2014;33:123–126. doi: 10.1016/j.healun.2013.10.015.
- Haddad F, Hunt SA, Rosenthal DN, Murphy DJ. Right ventricular function in cardiovascular disease, part I: anatomy, physiology, aging, and functional assessment of the right ventricle. *Circulation*. 2008;117:1436–1448. doi: 10.1161/CIRCULATIONAHA.107.653576.
- Sheehan F, Redington A. The right ventricle: anatomy, physiology and clinical imaging. *Heart*. 2008;94:1510–1515. doi: 10.1136/hrt.2007.132779.
- Zaffran S, Kelly RG, Meilhac SM, Buckingham ME, Brown NA. Right ventricular myocardium derives from the anterior heart field. *Circ Res*. 2004;95:261–268. doi: 10.1161/01.RES.0000136815.73623.BE.
- Dyer LA, Kirby ML. The role of secondary heart field in cardiac development. *Dev Biol*. 2009;336:137–144. doi: 10.1016/j.ydbio.2009.10.009.
- Francou A, Saint-Michel E, Mesbah K, Théveniau-Ruissy M, Rana MS, Christoffels VM, Kelly RG. Second heart field cardiac progenitor cells in the early mouse embryo. *Biochim Biophys Acta*. 2013;1833:795–798. doi: 10.1016/j.bbamcr.2012.10.003.
- Gittenberger-de Groot AC, Bartelings MM, Deruiter MC, Poelmann RE. Basics of cardiac development for the understanding of congenital heart malformations. *Pediatr Res*. 2005;57:169–176.
- Kelly RG, Buckingham ME, Moorman AF. Heart fields and cardiac morphogenesis. *Cold Spring Harb Perspect Med*. 2014;4:a015750XXX. doi: 10.1101/cshperspect.a015750.
- Xin M, Olson EN, Bassel-Duby R. Mending broken hearts: cardiac development as a basis for adult heart regeneration and repair. *Nat Rev Mol Cell Biol*. 2013;14:529–541. doi: 10.1038/nrm3619.
- Buckberg G, Hoffman JL. Right ventricular architecture responsible for mechanical performance: unifying role of ventricular septum. *J Thorac Cardiovasc Surg*. 2014;148:3166–3171.e4.
- James TN. Anatomy of the crista supraventricularis: its importance for understanding right ventricular function, right ventricular infarction and related conditions. *J Am Coll Cardiol*. 1985;6:1083–1095.
- Hudsmith LE, Petersen SE, Francis JM, Robson MD, Neubauer S. Normal human left and right ventricular and left atrial dimensions using steady state free precession magnetic resonance imaging. *J Cardiovasc Magn Reson*. 2005;7:775–782.
- Friedberg MK, Redington AN. Right versus left ventricular failure: differences, similarities, and interactions. *Circulation*. 2014;129:1033–1044. doi: 10.1161/CIRCULATIONAHA.113.001375.
- Faber MJ, Dalinghaus M, Lankhuizen IM, Steendijk P, Hop WC, Schoemaker RG, Duncker DJ, Lamers JM, Helbing WA. Right and left ventricular function after chronic pulmonary artery banding in rats assessed with biventricular pressure-volume loops. *Am J Physiol Heart Circ Physiol*. 2006;291:H1580–H1586. doi: 10.1152/ajpheart.00286.2006.
- Kapur NK, Paruchuri V, Aronovitz MJ, Qiao X, Mackey EE, Daly GH, Ughreja K, Levine J, Blanton R, Hill NS, Karas RH. Biventricular remodeling in murine models of right ventricular pressure overload. *PLoS One*. 2013;8:e70802. doi: 10.1371/journal.pone.0070802.
- Guazzi M, Naeije R. Pulmonary hypertension in heart failure: pathophysiology, pathobiology, and emerging clinical perspectives. *J Am Coll Cardiol*. 2017;69:1718–1734. doi: 10.1016/j.jacc.2017.01.051.
- Konstam MA, Cohen SR, Salem DN, Conlon TP, Isner JM, Das D, Zile MR, Levine HJ, Kahn PC. Comparison of left and right ventricular end-systolic pressure-volume relations in congestive heart failure. *J Am Coll Cardiol*. 1985;5:1326–1334.
- Haddad F, Doyle R, Murphy DJ, Hunt SA. Right ventricular function in cardiovascular disease, part II: pathophysiology, clinical importance, and management of right ventricular failure. *Circulation*. 2008;117:1717–1731. doi: 10.1161/CIRCULATIONAHA.107.653584.
- Abel FL, Waldhausen JA. Effects of alterations in pulmonary vascular resistance on right ventricular function. *J Thorac Cardiovasc Surg*. 1967;54:886–894.
- MacNee W. Pathophysiology of cor pulmonale in chronic obstructive pulmonary disease: part one. *Am J Respir Crit Care Med*. 1994;150:883–852.
- Iskandrian AS, Hakki AH, Ren JF, Kotler MN, Mintz GS, Ross J, Kane SA. Correlation among right ventricular preload, afterload and ejection fraction in mitral valve disease: radionuclide, echocardiographic and hemodynamic evaluation. *J Am Coll Cardiol*. 1984;3:1403–1411.
- Tedford RJ. Determinants of right ventricular afterload (2013 Grover Conference Series). *Pulm Circ*. 2014;4:211–219.
- Champion HC, Michelakis ED, Hassoun PM. Comprehensive invasive and noninvasive approach to the right ventricle-pulmonary circulation unit: state of the art and clinical and research implications. *Circulation*. 2009;120:992–1007. doi: 10.1161/CIRCULATIONAHA.106.674028.
- Tedford RJ, Hassoun PM, Mathai SC, Gargis RE, Russell SD, Thieman DR, Cingolani OH, Mudd JO, Borlaug BA, Redfield MM, Lederer DJ, Kass DA. Pulmonary capillary wedge pressure augments right ventricular pulsatile loading. *Circulation*. 2012;125:289–297. doi: 10.1161/CIRCULATIONAHA.111.051540.
- Gerges M, Gerges C, Pistrutto AM, Lang MB, Trip P, Jakowitsch J, Binder T, Lang IM. Pulmonary hypertension in heart failure: epidemiology, right ventricular function, and survival. *Am J Respir Crit Care Med*. 2015;192:1234–1246. doi: 10.1164/rccm.201503-0529OC.
- Dupont M, Mullens W, Skouri HN, Abrahams Z, Wu Y, Taylor DO, Starling RC, Tang WH. Prognostic role of pulmonary arterial capacitance in advanced heart failure. *Circ Heart Fail*. 2012;5:778–785. doi: 10.1161/CIRCHEARTFAILURE.112.968511.
- Houston BA, Shah KB, Mehra MR, Tedford RJ. A new “twist” on right heart failure with left ventricular assist systems. *J Heart Lung Transplant*. 2017;36:701–707. doi: 10.1016/j.healun.2017.03.014.
- Kelly RP, Ting CT, Yang TM, Liu CP, Maughan WL, Chang MS, Kass DA. Effective arterial elastance as index of arterial vascular load in humans. *Circulation*. 1992;86:513–521. doi: 10.1161/01.CIR.86.2.513.
- Fourie PR, Coetzee AR, Bolliger CT. Pulmonary artery compliance: its role in right ventricular-arterial coupling. *Cardiovasc Res*. 1992;26:839–844.
- Ghuysen A, Lambermont B, Kolh P, Tchana-Sato V, Magis D, Gerard P, Mommens V, Janssens N, Desai T, D’Orto V. Alteration of right ventricular-pulmonary vascular coupling in a porcine model of progressive pressure overload. *Shock*. 2008;29:197–204. doi: 10.1097/SHK.0b013e318070c790.
- Pellegrini P, Rossi A, Pasotti M, Raineri C, Ciccoira M, Bonapace S, Dini FL, Temporelli PL, Vassanelli C, Vanderpool R, Naeije R, Ghio S. Prognostic relevance of pulmonary arterial compliance in patients with chronic heart failure. *Chest*. 2014;145:1064–1070. doi: 10.1378/chest.13-1510.
- Goldstein JA. Pathophysiology and management of right heart ischemia. *J Am Coll Cardiol*. 2002;40:841–853.
- Watts JA, Marchick MR, Kline JA. Right ventricular heart failure from pulmonary embolism: key distinctions from chronic pulmonary hypertension. *J Card Fail*. 2010;16:250–259. doi: 10.1016/j.cardfail.2009.11.008.
- Santamore WP, Dell’Italia LJ. Ventricular interdependence: significant left ventricular contributions to right ventricular systolic function. *Prog Cardiovasc Dis*. 1998;40:289–308.
- Gibbons Kroeker CA, Adeeb S, Shrive NG, Tyberg JV. Compression induced by RV pressure overload decreases regional coronary blood flow in anesthetized dogs. *Am J Physiol Heart Circ Physiol*. 2006;290:H2432–H2438. doi: 10.1152/ajpheart.01140.2005.
- Scheel KW, Williams SE, Parker JB. Coronary sinus pressure has a direct effect on gradient for coronary perfusion. *Am J Physiol*. 1990;258(pt 2):H1739–H1744. doi: 10.1152/ajpheart.1990.258.6.H1739.
- Ryan JJ, Huston J, Kutty S, Hatton ND, Bowman L, Tian L, Herr JE, Johri AM, Archer SL. Right ventricular adaptation and failure in pulmonary arterial hypertension. *Can J Cardiol*. 2015;31:391–406. doi: 10.1016/j.cjca.2015.01.023.
- Vonk-Noordegraaf A, Haddad F, Chin KM, Forfia PR, Kawut SM, Lumens J, Naeije R, Newman J, Oudiz RJ, Provencher S, Torbicki A, Voelkel NF, Hassoun PM. Right heart adaptation to pulmonary arterial hypertension: physiology and pathobiology. *J Am Coll Cardiol*. 2013;62(suppl):D22–D33. doi: 10.1016/j.jacc.2013.10.027.
- Mullens W, Abrahams Z, Francis GS, Sokos G, Taylor DO, Starling RC, Young JB, Tang WH. Importance of venous congestion for worsening of renal function in advanced decompensated heart failure. *J Am Coll Cardiol*. 2009;53:589–596. doi: 10.1016/j.jacc.2008.05.068.
- Bernheim P. De l’asystole veineuse dans l’hypertrophie du coeur gauche par stenose concomitante du ventricule droit. *Rev Med*. 1910;39:785–794.
- Iglesias-Garriz I, Olalla-Gómez C, Garrote C, López-Benito M, Martín J, Alonso D, Rodríguez MA. Contribution of right ventricular dysfunction to heart failure mortality: a meta-analysis. *Rev Cardiovasc Med*. 2012;13:e62–e69.
- Lewis JF, Webber JD, Sutton LL, Chesoni S, Curry CL. Discordance in degree of right and left ventricular dilation in patients with dilated cardiomyopathy: recognition and clinical implications. *J Am Coll Cardiol*. 1993;21:649–654.
- La Vecchia L, Paccanaro M, Bonanno C, Varotto L, Ometto R, Vincenzi M. Left ventricular versus biventricular dysfunction in idiopathic dilated cardiomyopathy. *Am J Cardiol*. 1999;83:120–122, A9.
- Freja S, Pidello S, Bovolo V, Iacovino C, Franco E, Pinneri F, Galluzzo A, Volpe A, Visconti M, Peirone A, Morello M, Bergerone S, Gaita F. Prognostic incremental role of right ventricular function in acute decompensation of advanced chronic heart failure. *Eur J Heart Fail*. 2016;18:564–572. doi: 10.1002/ehf.504.
- Baker BJ, Wilen MM, Boyd CM, Dinh H, Franciosa JA. Relation of right ventricular ejection fraction to exercise capacity in chronic left ventricular failure. *Am J Cardiol*. 1984;54:596–599.
- Guazzi M, Villani S, Generati G, Ferraro OE, Pellegrino M, Alfonzetti E, Labate V, Gaeta M, Sugimoto T, Bandera F. Right ventricular contractile

reserve and pulmonary circulation uncoupling during exercise challenge in heart failure: pathophysiology and clinical phenotypes. *JACC Heart Fail*. 2016;4:625–635. doi: 10.1016/j.jchf.2016.03.007.

47. Gorter TM, Hoendermis ES, van Veldhuisen DJ, Voors AA, Lam CS, Geelhoed B, Willems TP, van Melle JP. Right ventricular dysfunction in heart failure with preserved ejection fraction: a systematic review and meta-analysis. *Eur J Heart Fail*. 2016;18:1472–1487. doi: 10.1002/ehf.630.
48. Melenovsky V, Hwang SJ, Lin G, Redfield MM, Borlaug BA. Right heart dysfunction in heart failure with preserved ejection fraction. *Eur Heart J*. 2014;35:3452–3462. doi: 10.1093/eurheartj/ehu193.
49. Puwanant S, Priester TC, Mookadam F, Bruce CJ, Redfield MM, Chandrasekaran K. Right ventricular function in patients with preserved and reduced ejection fraction heart failure. *Eur J Echocardiogr*. 2009;10:733–737. doi: 10.1093/ejchocard/jep052.
50. Mohammed SF, Hussain I, AbouEzzeddine OF, Abou Ezzeddine OF, Takahama H, Kwon SH, Forfia P, Roger VL, Redfield MM. Right ventricular function in heart failure with preserved ejection fraction: a community-based study. *Circulation*. 2014;130:2310–2320. doi: 10.1161/CIRCULATIONAHA.113.008461.
51. Morris DA, Gailani M, Vaz Pérez A, Blaschke F, Dietz R, Haverkamp W, Özcelik C. Right ventricular myocardial systolic and diastolic dysfunction in heart failure with normal left ventricular ejection fraction. *J Am Soc Echocardiogr*. 2011;24:886–897. doi: 10.1016/j.echo.2011.04.005.
52. Borlaug BA, Kane GC, Melenovsky V, Olson TP. Abnormal right ventricular-pulmonary artery coupling with exercise in heart failure with preserved ejection fraction. *Eur Heart J*. 2016;37:3293–3302. doi: 10.1093/eurheartj/ehw241.
53. Caforio AL, Calabrese F, Angelini A, Tona F, Vinci A, Bottaro S, Ramondo A, Caturan E, Illiceto S, Thiene G, Daliento L. A prospective study of biopsy-proven myocarditis: prognostic relevance of clinical and aetiopathogenetic features at diagnosis. *Eur Heart J*. 2007;28:1326–1333. doi: 10.1093/eurheartj/ehm076.
54. Kakouros N, Cokkinos DV. Right ventricular myocardial infarction: pathophysiology, diagnosis, and management. *Postgrad Med J*. 2010;86:719–728. doi: 10.1136/pgmj.2010.103887.
55. Ondrus T, Kanovsky J, Novotny T, Androsova I, Spinar J, Kala P. Right ventricular myocardial infarction: from pathophysiology to prognosis. *Exp Clin Cardiol*. 2013;18:27–30.
56. Assali AR, Teplitsky I, Ben-Dor I, Solodky A, Brosh D, Battler A, Fuchs S, Kornowski R. Prognostic importance of right ventricular infarction in an acute myocardial infarction cohort referred for contemporary percutaneous reperfusion therapy. *Am Heart J*. 2007;153:231–237. doi: 10.1016/j.ahj.2006.10.038.
57. Zehender M, Kasper W, Kauder E, Schönthal M, Geibel A, Olschewski M, Just H. Right ventricular infarction as an independent predictor of prognosis after acute inferior myocardial infarction. *N Engl J Med*. 1993;328:981–988. doi: 10.1056/NEJM199304083281401.
58. Goldstein JA. Right heart ischemia: pathophysiology, natural history, and clinical management. *Prog Cardiovasc Dis*. 1998;40:325–341.
59. Gumina RJ, Murphy JG, Rihal CS, Lennon RJ, Wright RS. Long-term survival after right ventricular infarction. *Am J Cardiol*. 2006;98:1571–1573. doi: 10.1016/j.amjcard.2006.07.033.
60. Lim ST, Goldstein JA. Right ventricular infarction. *Curr Treat Options Cardiovasc Med*. 2001;3:95–101.
61. Mehta SR, Eikelboom JW, Natarajan MK, Diaz R, Yi C, Gibbons RJ, Yusuf S. Impact of right ventricular involvement on mortality and morbidity in patients with inferior myocardial infarction. *J Am Coll Cardiol*. 2001;37:37–43.
62. Jacobs AK, Leopold JA, Bates E, Mendes LA, Sleeper LA, White H, Davidoff R, Boland J, Modur S, Forman R, Hochman JS. Cardiogenic shock caused by right ventricular infarction: a report from the SHOCK registry. *J Am Coll Cardiol*. 2003;41:1273–1279.
63. Harjola VP, Mebazaa A, Čelutkienė J, Bettex D, Bueno H, Chioncel O, Crespo-Leiro MG, Falk V, Filippatos G, Gibbs S, Leite-Moreira A, Lassus J, Masip J, Mueller C, Mullens W, Naeije R, Nordegraaf AV, Parissis J, Riley JP, Ristic A, Rosano G, Rudiger A, Ruschitzka F, Seferovic P, Sztymf B, Vieillard-Baron A, Yilmaz MB, Konstantinides S. Contemporary management of acute right ventricular failure: a statement from the Heart Failure Association and the Working Group on Pulmonary Circulation and Right Ventricular Function of the European Society of Cardiology. *Eur J Heart Fail*. 2016;18:226–241. doi: 10.1002/ehf.478.
64. Haddad F, Couture P, Tousignant C, Denault AY. The right ventricle in cardiac surgery, a perioperative perspective, I: anatomy, physiology, and assessment. *Anesth Analg*. 2009;108:407–421. doi: 10.1213/ane.0b013e31818f8623.
65. Haddad F, Couture P, Tousignant C, Denault AY. The right ventricle in cardiac surgery, a perioperative perspective, II: pathophysiology, clinical importance, and management. *Anesth Analg*. 2009;108:422–433. doi: 10.1213/ane.0b013e31818f8b92.
66. Raina A, Vaidya A, Gertz ZM, Susan Chambers, Forfia PR. Marked changes in right ventricular contractile pattern after cardiothoracic surgery: implications for post-surgical assessment of right ventricular function. *J Heart Lung Transplant*. 2013;32:777–783. doi: 10.1016/j.healun.2013.05.004.
67. Brown SB, Raina A, Katz D, Szerlip M, Wiegers SE, Forfia PR. Longitudinal shortening accounts for the majority of right ventricular contraction and improves after pulmonary vasodilator therapy in normal subjects and patients with pulmonary arterial hypertension. *Chest*. 2011;140:27–33. doi: 10.1378/chest.10-1136.
68. Diller GP, Wasan BS, Kyriacou A, Patel N, Casula RP, Athanasios T, Francis DP, Mayet J. Effect of coronary artery bypass surgery on myocardial function as assessed by tissue Doppler echocardiography. *Eur J Cardiothorac Surg*. 2008;34:995–999. doi: 10.1016/j.ejcts.2008.08.008.
69. Denault AY, Pearl RG, Michler RE, Rao V, Tsui SS, Seitelberger R, Cromie M, Lindberg E, D'Armini AM. Tezosentan and right ventricular failure in patients with pulmonary hypertension undergoing cardiac surgery: the TACTICS trial. *J Cardiothorac Vasc Anesth*. 2013;27:1212–1217. doi: 10.1053/j.jvca.2013.01.023.
70. Rösner A, Avenarius D, Malm S, Iqbal A, Schirmer H, Bijnsens B, Myrmel T. Changes in right ventricular shape and deformation following coronary artery bypass surgery: insights from echocardiography with strain rate and magnetic resonance imaging. *Echocardiography*. 2015;32:1809–1820. doi: 10.1111/echo.12973.
71. Kobashigawa J, Zuckermann A, Macdonald P, Leprince P, Esmailian F, Luu E, Mancini D, Patel J, Razi R, Reichenspurner H, Russell S, Segovia J, Smedira N, Stehlik J, Wagner F. Report from a consensus conference on primary graft dysfunction after cardiac transplantation. *J Heart Lung Transplant*. 2014;33:327–340.
72. D'Alessandro C, Aubert S, Golmard JL, Praschker BL, Luyt CE, Pavie A, Gandjbakhch I, Leprince P. Extra-corporeal membrane oxygenation temporary support for early graft failure after cardiac transplantation. *Eur J Cardiothorac Surg*. 2010;37:343–349. doi: 10.1016/j.ejcts.2009.05.034.
73. Chen EP, Bittner HB, Davis RD, Van Trigt P. Right ventricular adaptation to increased afterload after orthotopic cardiac transplantation in the setting of recipient chronic pulmonary hypertension. *Circulation*. 1997;96(suppl):II-141–II-147.
74. Stobierska-Dzierzek B, Awad H, Michler RE. The evolving management of acute right-sided heart failure in cardiac transplant recipients. *J Am Coll Cardiol*. 2001;38:923–931.
75. Taghavi S, Zuckermann A, Ankersmit J, Wieselthaler G, Rajek A, Laufer G, Wolner E, Grimm M. Extracorporeal membrane oxygenation is superior to right ventricular assist device for acute right ventricular failure after heart transplantation. *Ann Thorac Surg*. 2004;78:1644–1649. doi: 10.1016/j.athoracsur.2004.04.059.
76. Kormos RL, Teuteberg JJ, Pagani FD, Russell SD, John R, Miller LW, Massey T, Milano CA, Moazami N, Sundareswaran KS, Farrar DJ, HeartMate II Clinical Investigators. Right ventricular failure in patients with the HeartMate II continuous-flow left ventricular assist device: incidence, risk factors, and effect on outcomes. *J Thorac Cardiovasc Surg*. 2010;139:1316–1324. doi: 10.1016/j.jtcvs.2009.11.020.
77. Lampert BC, Teuteberg JJ. Right ventricular failure after left ventricular assist devices. *J Heart Lung Transplant*. 2015;34:1123–1130. doi: 10.1016/j.healun.2015.06.015.
78. Soliman OI, Akin S, Muslem R, Boersma E, Manintveld OC, Krabatsch T, Gummert JF, de By T, Bogers A, Zijlstra F, Mohacs P, Caliskan K, EURO-MACS Investigators. Derivation and validation of a novel right-sided heart failure model after implantation of continuous flow left ventricular assist devices: the EUROMACS (European Registry for Patients With Mechanical Circulatory Support) Right-Sided Heart Failure Risk Score. *Circulation*. 2018;137:891–906. doi: 10.1161/CIRCULATIONAHA.117.030543.
79. Oliveira GH, Dupont M, Naftel D, Myers SL, Yuan Y, Tang WH, Gonzalez-Stawinski G, Young JB, Taylor DO, Starling RC. Increased need for right ventricular support in patients with chemotherapy-induced cardiomyopathy undergoing mechanical circulatory support: outcomes from the INTERMACS Registry (Interagency Registry for Mechanically Assisted Circulatory Support). *J Am Coll Cardiol*. 2014;63:240–248. doi: 10.1016/j.jacc.2013.09.040.
80. Farrar DJ, Compton PG, Hershon JJ, Fonger JD, Hill JD. Right heart interaction with the mechanically assisted left heart. *World J Surg*. 1985;9:89–102.
81. Farrar DJ, Compton PG, Hershon JJ, Hill JD. Right ventricular function in an operating room model of mechanical left ventricular assistance and its effects in patients with depressed left ventricular function. *Circulation*. 1985;72:1279–1285. doi: 10.1161/01.CIR.72.6.1279.
82. Lohmanpour NA, Kormos RL, Kanwar MK, Teuteberg JJ, Murali S, Antaki JF. A Bayesian model to predict right ventricular failure following left ventricular assist device therapy. *JACC Heart Fail*. 2016;4:711–721. doi: 10.1016/j.jchf.2016.04.004.
83. Wang Y, Simon MA, Bonde P, Harris BU, Teuteberg JJ, Kormos RL, Antaki JF. Decision tree for adjuvant right ventricular support in patients receiving a left ventricular assist device. *J Heart Lung Transplant*. 2012;31:140–149. doi: 10.1016/j.healun.2011.11.003.

84. Rich JD, Gosev I, Patel CB, Joseph S, Katz JN, Eckman PM, Lee S, Sundareswaran K, Kilic A, Bethea B, Soleimani B, Lima B, Uriel N, Kiernan M; Evolving Mechanical Support Research Group (EMERG) Investigators. The incidence, risk factors, and outcomes associated with late right-sided heart failure in patients supported with an axial-flow left ventricular assist device. *J Heart Lung Transplant*. 2017;36:50–58. doi: 10.1016/j.healun.2016.08.010.
85. Takeda K, Takayama H, Colombo PC, Yuzefpolskaya M, Fukuhara S, Han J, Kurlansky P, Mancini DM, Naka Y. Incidence and clinical significance of late right heart failure during continuous-flow left ventricular assist device support. *J Heart Lung Transplant*. 2015;34:1024–1032. doi: 10.1016/j.healun.2015.03.011.
86. Coutance G, Cauderlier E, Ehtisham J, Hamon M, Hamon M. The prognostic value of markers of right ventricular dysfunction in pulmonary embolism: a meta-analysis. *Crit Care*. 2011;15:R103. doi: 10.1186/cc10119.
87. Konstantinides SV, Torbicki A, Agnelli G, Danchin N, Fitzmaurice D, Galie N, Gibbs JS, Huisman MV, Humbert M, Kucher N, Lang I, Lankeit M, Lekakis J, Maack C, Mayer E, Meneveau N, Perrier A, Pruszczyk P, Rasmussen LH, Schindler TH, Svitil P, Vonk Noordegraaf A, Zamorano JL, Zompatori M; Task Force for the Diagnosis and Management of Acute Pulmonary Embolism of the European Society of Cardiology (ESC). 2014 ESC guidelines on the diagnosis and management of acute pulmonary embolism. *Eur Heart J*. 2014;35:3033–3069, 3069a. doi: 10.1093/eurheartj/ehu283.
88. Kline JA, Zeitouni R, Marchick MR, Hernandez-Nino J, Rose GA. Comparison of 8 biomarkers for prediction of right ventricular hypokinesis 6 months after submassive pulmonary embolism. *Am Heart J*. 2008;156:308–314. doi: 10.1016/j.ahj.2008.03.026.
89. Corrado D, Link MS, Calkins H. Arrhythmogenic right ventricular cardiomyopathy. *N Engl J Med*. 2017;376:61–72. doi: 10.1056/NEJMra1509267.
90. Sen-Chowdhry S, Syrris P, McKenna WJ. Genetics of right ventricular cardiomyopathy. *J Cardiovasc Electrophysiol*. 2005;16:927–935. doi: 10.1111/j.1540-8167.2005.40842.x.
91. Corrado D, Thiene G. Arrhythmogenic right ventricular cardiomyopathy/dysplasia: clinical impact of molecular genetic studies. *Circulation*. 2006;113:1634–1637. doi: 10.1161/CIRCULATIONAHA.105.616490.
92. Marcus FI, McKenna WJ, Sherrill D, Basso C, Baucé B, Bluemke DA, Calkins H, Corrado D, Cox MG, Daubert JP, Fontaine G, Gear K, Hauer R, Nava A, Picard MH, Protonotarios N, Saffitz JE, Sanborn DM, Steinberg JS, Tandri H, Thiene G, Towbin JA, Tsatsopoulou A, Wichter T, Zareba W. Diagnosis of arrhythmogenic right ventricular cardiomyopathy/dysplasia: proposed modification of the task force criteria. *Circulation*. 2010;121:1533–1541. doi: 10.1161/CIRCULATIONAHA.108.840827.
93. Marcus FI, McKenna WJ, Sherrill D, Basso C, Baucé B, Bluemke DA, Calkins H, Corrado D, Cox MG, Daubert JP, Fontaine G, Gear K, Hauer R, Nava A, Picard MH, Protonotarios N, Saffitz JE, Sanborn DM, Steinberg JS, Tandri H, Thiene G, Towbin JA, Tsatsopoulou A, Wichter T, Zareba W. Diagnosis of arrhythmogenic right ventricular cardiomyopathy/dysplasia: proposed modification of the Task Force Criteria. *Eur Heart J*. 2010;31:806–814. doi: 10.1093/eurheartj/ehq025.
94. Ackerman MJ, Priori SG, Willems S, Berul C, Brugada R, Calkins H, Camm AJ, Ellinor PT, Gollob M, Hamilton R, Hershberger RE, Judge DP, Le Marec H, McKenna WJ, Schulze-Bahr E, Semsarian C, Towbin JA, Watkins H, Wilde A, Wolpert C, Zipes DP. HRS/EHRA expert consensus statement on the state of genetic testing for the channelopathies and cardiomyopathies: this document was developed as a partnership between the Heart Rhythm Society (HRS) and the European Heart Rhythm Association (EHRA). *Heart Rhythm*. 2011;8:1308–1339. doi: 10.1016/j.hrthm.2011.05.020.
95. Corrado D, Basso C, Schiavon M, Thiene G. Screening for hypertrophic cardiomyopathy in young athletes. *N Engl J Med*. 1998;339:364–369. doi: 10.1056/NEJM199808063390602.
96. Finocchiaro G, Papadakis M, Robertus JL, Dhutia H, Steriotis AK, Tome M, Mellor G, Merghani A, Malhotra A, Behr E, Sharma S, Sheppard MN. Etiology of sudden death in sports: insights from a United Kingdom regional registry. *J Am Coll Cardiol*. 2016;67:2108–2115. doi: 10.1016/j.jacc.2016.02.062.
97. Dalal D, Nasir K, Bomma C, Prakasa K, Tandri H, Piccini J, Roguin A, Tichnell C, James C, Russell SD, Judge DP, Abraham T, Spevak PJ, Bluemke DA, Calkins H. Arrhythmogenic right ventricular dysplasia: a United States experience. *Circulation*. 2005;112:3823–3832. doi: 10.1161/CIRCULATIONAHA.105.542266.
98. Corrado D, Wichter T, Link MS, Hauer RN, Marchlinski FE, Anastakis A, Baucé B, Basso C, Bruckhorst C, Tsatsopoulou A, Tandri H, Paul M, Schmied C, Pelliccia A, Duro F, Protonotarios N, Estes NM 3rd, McKenna WJ, Thiene G, Marcus FI, Calkins H. Treatment of arrhythmogenic right ventricular cardiomyopathy/dysplasia: an International Task Force Consensus Statement. *Circulation*. 2015;132:441–453. doi: 10.1161/CIRCULATIONAHA.115.017944.
99. Tarassio M, Vanermen H, Maisano F, Guidotti A, La Canna G, Alfieri O. The growing clinical importance of secondary tricuspid regurgitation. *J Am Coll Cardiol*. 2012;59:703–710. doi: 10.1016/j.jacc.2011.09.069.
100. Bhavne NM, Ward RP. Echocardiographic assessment and clinical management of tricuspid regurgitation. *Curr Cardiol Rep*. 2011;13:258–264. doi: 10.1007/s11886-011-0180-7.
101. Nath J, Foster E, Heidenreich PA. Impact of tricuspid regurgitation on long-term survival. *J Am Coll Cardiol*. 2004;43:405–409. doi: 10.1016/j.jacc.2003.09.036.
102. Pradat P, Francannet C, Harris JA, Robert E. The epidemiology of cardiovascular defects, part I: a study based on data from three large registries of congenital malformations. *Pediatr Cardiol*. 2003;24:195–221. doi: 10.1007/s00246-002-9401-6.
103. Wald RM, Valente AM, Marelli A. Heart failure in adult congenital heart disease: Emerging concepts with a focus on tetralogy of Fallot. *Trends Cardiovasc Med*. 2015;25:422–432. doi: 10.1016/j.tcm.2014.11.011.
104. Elkayam U, Bitar F. Valvular heart disease and pregnancy, part I: native valves. *J Am Coll Cardiol*. 2005;46:223–230. doi: 10.1016/j.jacc.2005.02.085.
105. Nishimura RA, Otto C. 2014 ACC/AHA valve guidelines: earlier intervention for chronic mitral regurgitation. *Heart*. 2014;100:905–907. doi: 10.1136/heartjnl-2014-305834.
106. Hayes CJ, Gersony WM, Driscoll DJ, Keane JF, Kidd L, O'Fallon WM, Pieroni DR, Wolfe RR, Weidman WH. Second natural history study of congenital heart defects: results of treatment of patients with pulmonary valvar stenosis. *Circulation*. 1993;87(suppl):I28–I37.
107. Meijer JM, Pieper PG, Drenth W, Voors AA, Roos-Hesselink JW, van Dijk AP, Mulder BJ, Ebels T, van Veldhuisen DJ. Pregnancy, fertility, and recurrence risk in corrected tetralogy of Fallot. *Heart*. 2005;91:801–805. doi: 10.1136/hrt.2004.034108.
108. Babu-Narayan SV, Kilner PJ, Li W, Moon JC, Goktekin O, Davlouros PA, Khan M, Ho SY, Pennell DJ, Gatzoulis MA. Ventricular fibrosis suggested by cardiovascular magnetic resonance in adults with repaired tetralogy of Fallot and its relationship to adverse markers of clinical outcome. *Circulation*. 2006;113:405–413. doi: 10.1161/CIRCULATIONAHA.105.548727.
109. Galie N, Humbert M, Vachiery JL, Gibbs S, Lang I, Torbicki A, Simonneau G, Peacock A, Vonk Noordegraaf A, Beghetti M, Ghofrani A, Gomez Sanchez MA, Hansmann G, Klepetko W, Lancellotti P, Matucci M, McDonagh T, Pierard LA, Trindade PT, Zompatori M, Hoeper M, Aboyans V, Vaz Carneiro A, Achenbach S, Agewall S, Allanore Y, Asteggiano R, Paolo Badano L, Albert Barberà J, Bouvaist H, Bueno H, Byrne RA, Carerj S, Castro G, Erol C, Falk V, Funck-Brentano C, Gorenflo M, Granton J, Jung B, Kiely DG, Kirchhof P, Kjellström B, Landmesser U, Lekakis J, Lionis C, Lip GY, Orfanos SE, Park MH, Piepoli MF, Ponikowski P, Revel MP, Rigau D, Rosenkranz S, Völler H, Luis Zamorano J. 2015 ESC/ERS guidelines for the diagnosis and treatment of pulmonary hypertension: the Joint Task Force for the Diagnosis and Treatment of Pulmonary Hypertension of the European Society of Cardiology (ESC) and the European Respiratory Society (ERS). *Eur Heart J*. 2016;37:67–119. doi: 10.1093/eurheartj/ehv317.
110. McLaughlin VV, Archer SL, Badesch DB, Barst RJ, Farber HW, Lindner JR, Mathier MA, McGoon MD, Park MH, Rosenson RS, Rubin LJ, Tapson VF, Varga J, Harrington RA, Anderson JL, Bates ER, Bridges CR, Eisenberg MJ, Ferrari VA, Grines CL, Hlatky MA, Jacobs AK, Kaul S, Lichtenberg RC, Lindner JR, Moliterno DJ, Mukherjee D, Pohost GM, Rosenson RS, Schofield RS, Shubrooks SJ, Stein JH, Tracy CM, Weitz HH, Wesley DJ; ACCF/AHA. ACCF/AHA 2009 expert consensus document on pulmonary hypertension: a report of the American College of Cardiology Foundation Task Force on Expert Consensus Documents and the American Heart Association [published correction appears in *Circulation*. 2009;120:e13]. *Circulation*. 2009;119:2250–2294. doi: 10.1161/CIRCULATIONAHA.109.192230.
111. Frost AE, Badesch DB, Barst RJ, Benza RL, Elliott CG, Farber HW, Krichman A, Liou TG, Raskob GE, Wason P, Feldkircher K, Turner M, McGoon MD. The changing picture of patients with pulmonary arterial hypertension in the United States: how REVEAL differs from historic and non-US Contemporary Registries. *Chest*. 2011;139:128–137. doi: 10.1378/chest.10-0075.
112. Simonneau G, Gatzoulis MA, Adatia I, Celermajer D, Denton C, Ghofrani A, Gomez Sanchez MA, Krishna Kumar R, Landzberg M, Machado RF, Olschewski H, Robbins IM, Souza R. Updated clinical classification of pulmonary hypertension. *J Am Coll Cardiol*. 2013;62(suppl):D34–D41. doi: 10.1016/j.jacc.2013.10.029.
113. Benza RL, Miller DP, Barst RJ, Badesch DB, Frost AE, McGoon MD. An evaluation of long-term survival from time of diagnosis in pulmonary

- arterial hypertension from the REVEAL Registry. *Chest*. 2012;142:448–456. doi: 10.1378/chest.11-1460.
114. Chin KM, Kim NH, Rubin LJ. The right ventricle in pulmonary hypertension. *Coron Artery Dis*. 2005;16:13–18.
 115. Mahapatra S, Nishimura RA, Sorajja P, Cha S, McGoon MD. Relationship of pulmonary arterial capacitance and mortality in idiopathic pulmonary arterial hypertension. *J Am Coll Cardiol*. 2006;47:799–803. doi: 10.1016/j.jacc.2005.09.054.
 116. Fine NM, Chen L, Bastiansen PM, Frantz RP, Pellikka PA, Oh JK, Kane GC. Outcome prediction by quantitative right ventricular function assessment in 575 subjects evaluated for pulmonary hypertension. *Circ Cardiovasc Imaging*. 2013;6:711–721. doi: 10.1161/CIRCIMAGING.113.000640.
 117. Sachdev A, Villarraga HR, Frantz RP, McGoon MD, Hsiao JF, Maalouf JF, Ammash NM, McCully RB, Miller FA, Pellikka PA, Oh JK, Kane GC. Right ventricular strain for prediction of survival in patients with pulmonary arterial hypertension. *Chest*. 2011;139:1299–1309. doi: 10.1378/chest.10-2015.
 118. Voelkel NF, Quaife RA, Leinwand LA, Barst RJ, McGoon MD, Meldrum DR, Dupuis J, Long CS, Rubin LJ, Smart FW, Suzuki YJ, Gladwin M, Denholm EM, Gail DB; National Heart, Lung, and Blood Institute Working Group on Cellular and Molecular Mechanisms of Right Heart Failure. Right ventricular function and failure: report of a National Heart, Lung, and Blood Institute working group on cellular and molecular mechanisms of right heart failure. *Circulation*. 2006;114:1883–1891. doi: 10.1161/CIRCULATIONAHA.106.632208.
 119. Abraham WT, Raynolds MV, Badesch DB, Wynne KM, Groves BM, Roden RL, Robertson AD, Lowes BD, Zisman LS, Voelkel NF, Bristow MR, Peryman MB. Angiotensin-converting enzyme DD genotype in patients with primary pulmonary hypertension: increased frequency and association with preserved haemodynamics. *J Renin Angiotensin Aldosterone Syst*. 2003;4:27–30. doi: 10.3317/jraas.2003.003.
 120. Benza RL, Miller DP, Gomberg-Maitland M, Frantz RP, Foreman AJ, Coffey CS, Frost A, Barst RJ, Badesch DB, Elliott CG, Liou TG, McGoon MD. Predicting survival in pulmonary arterial hypertension: insights from the Registry to Evaluate Early and Long-Term Pulmonary Arterial Hypertension Disease Management (REVEAL). *Circulation*. 2010;122:164–172. doi: 10.1161/CIRCULATIONAHA.109.898122.
 121. Davlouros PA, Niwa K, Webb G, Gatzoulis MA. The right ventricle in congenital heart disease. *Heart*. 2006;92(suppl):i27–i38. doi: 10.1136/hrt.2005.077438.
 122. Hopkins WE, Waggoner AD. Severe pulmonary hypertension without right ventricular failure: the unique hearts of patients with Eisenmenger syndrome. *Am J Cardiol*. 2002;89:34–38.
 123. Hopkins WE, Ochoa LL, Richardson GW, Trulock EP. Comparison of the hemodynamics and survival of adults with severe primary pulmonary hypertension or Eisenmenger syndrome. *J Heart Lung Transplant*. 1996;15(pt 1):100–105.
 124. Montani D, Price LC, Dorfmueller P, Achouh L, Jaïs X, Yaïci A, Sitbon O, Musset D, Simonneau G, Humbert M. Pulmonary veno-occlusive disease. *Eur Respir J*. 2009;33:189–200. doi: 10.1183/09031936.00090608.
 125. Fang JC, DeMarco T, Givertz MM, Borlaug BA, Lewis GD, Rame JE, Gomberg-Maitland M, Murali S, Frantz RP, McGlothlin D, Horn EM, Benza RL. World Health Organization Pulmonary Hypertension Group 2: pulmonary hypertension due to left heart disease in the adult: a summary statement from the Pulmonary Hypertension Council of the International Society for Heart and Lung Transplantation. *J Heart Lung Transplant*. 2012;31:913–933. doi: 10.1016/j.healun.2012.06.002.
 126. Gerdes C, Gerdes M, Lang MB, Zhang Y, Jakowitsch J, Probst P, Maurer G, Lang IM. Diastolic pulmonary vascular pressure gradient: a predictor of prognosis in “out-of-proportion” pulmonary hypertension. *Chest*. 2013;143:758–766. doi: 10.1378/chest.12-1653.
 127. Butler J, Chomsky DB, Wilson JR. Pulmonary hypertension and exercise intolerance in patients with heart failure. *J Am Coll Cardiol*. 1999;34:1802–1806.
 128. Murali S, Kormos RL, Uretsky BF, Schechter D, Reddy PS, Denys BG, Armitage JM, Hardesty RL, Griffith BP. Preoperative pulmonary hemodynamics and early mortality after orthotopic cardiac transplantation: the Pittsburgh experience. *Am Heart J*. 1993;126:896–904.
 129. Hurdman J, Condliffe R, Elliot CA, Davies C, Hill C, Wild JM, Capener D, Sephton P, Hamilton N, Armstrong JJ, Billings C, Lawrie A, Sabroe I, Akil M, O’Toole L, Kiely DG. ASPIRE registry: Assessing the Spectrum of Pulmonary hypertension Identified at a REferral centre. *Eur Respir J*. 2012;39:945–955. doi: 10.1183/09031936.00078411.
 130. Minai OA, Ricaurte B, Kaw R, Hammel J, Mansour M, McCarthy K, Golish JA, Stoller JK. Frequency and impact of pulmonary hypertension in patients with obstructive sleep apnea syndrome. *Am J Cardiol*. 2009;104:1300–1306. doi: 10.1016/j.amjcard.2009.06.048.
 131. Ismail K, Roberts K, Manning P, Manley C, Hill NS. OSA and pulmonary hypertension: time for a new look. *Chest*. 2015;147:847–861. doi: 10.1378/chest.14-0614.
 132. Kessler R, Chaouat A, Schinkewitch P, Faller M, Casel S, Krieger J, Weitzenblum E. The obesity-hypoventilation syndrome revisited: a prospective study of 34 consecutive cases. *Chest*. 2001;120:369–376.
 133. Alawami M, Mustafa A, Whyte K, Alkhatir M, Bhikoo Z, Pemberton J. Echocardiographic and electrocardiographic findings in patients with obesity hypoventilation syndrome. *Intern Med J*. 2015;45:68–73. doi: 10.1111/imj.12620.
 134. Castro-Añón O, Golpe R, Pérez-de-Llano LA, López González MJ, Escalona Velasquez EJ, Pérez Fernández R, Testa Fernández A, González Quintela A. Haemodynamic effects of non-invasive ventilation in patients with obesity-hypoventilation syndrome. *Respirology*. 2012;17:1269–1274. doi: 10.1111/j.1440-1843.2012.02252.x.
 135. Cannon JE, Su L, Kiely DG, Page K, Toshner M, Swietlik E, Treacy C, Ponnabaranam A, Condliffe R, Sheares K, Taboada D, Dunning J, Tsui S, Ng C, Gopalan D, Screation N, Elliot C, Gibbs S, Howard L, Corris P, Lordan J, Johnson M, Peacock A, MacKenzie-Ross R, Schreiber B, Coghlan G, Dimopoulos K, Wort SJ, Gaine S, Moledina S, Jenkins DP, Pepke-Zaba J. Dynamic risk stratification of patient long-term outcome after pulmonary endarterectomy: results from the United Kingdom National Cohort. *Circulation*. 2016;133:1761–1771. doi: 10.1161/CIRCULATIONAHA.115.019470.
 136. Feinstein JA, Goldhaber SZ, Lock JE, Ferencik SD, Landberg MJ. Balloon pulmonary angioplasty for treatment of chronic thromboembolic pulmonary hypertension. *Circulation*. 2001;103:10–13. doi: 10.1161/01.CIR.103.1.10.
 137. Kataoka M, Inami T, Hayashida K, Shimura N, Ishiguro H, Abe T, Tamura Y, Ando M, Fukuda K, Yoshino H, Satoh T. Percutaneous transluminal pulmonary angioplasty for the treatment of chronic thromboembolic pulmonary hypertension. *Circ Cardiovasc Interv*. 2012;5:756–762. doi: 10.1161/CIRCINTERVENTIONS.112.971390.
 138. Mizoguchi H, Ogawa A, Munemasa M, Mikouchi H, Ito H, Matsubara H. Refined balloon pulmonary angioplasty for inoperable patients with chronic thromboembolic pulmonary hypertension. *Circ Cardiovasc Interv*. 2012;5:748–755. doi: 10.1161/CIRCINTERVENTIONS.112.971077.
 139. Huang SJ, Nalos M, McLean AS. Is early ventricular dysfunction or dilation associated with lower mortality rate in adult severe sepsis and septic shock? A meta-analysis. *Crit Care*. 2013;17:R96. doi: 10.1186/cc12741.
 140. Kimchi A, Ellrodt AG, Berman DS, Riedinger MS, Swan HJ, Murata GH. Right ventricular performance in septic shock: a combined radiocluid and hemodynamic study. *J Am Coll Cardiol*. 1984;4:945–951.
 141. Bird TM, Hobbs CA, Cleves MA, Tilford JM, Robbins JM. National rates of birth defects among hospitalized newborns. *Birth Defects Res A Clin Mol Teratol*. 2006;76:762–769. doi: 10.1002/bdra.20323.
 142. Canfield MA, Honein MA, Yuskiv N, Xing J, Mai CT, Collins JS, Devine O, Petrini J, Ramadhani TA, Hobbs CA, Kirby RS. National estimates and race/ethnic-specific variation of selected birth defects in the United States, 1999–2001. *Birth Defects Res A Clin Mol Teratol*. 2006;76:747–756. doi: 10.1002/bdra.20294.
 143. Mazor Dray E, Marelli AJ. Adult congenital heart disease: scope of the problem. *Cardiol Clin*. 2015;33:503–512. vii. doi: 10.1016/j.ccl.2015.07.001.
 144. Webb G, Gatzoulis MA. Atrial septal defects in the adult: recent progress and overview. *Circulation*. 2006;114:1645–1653. doi: 10.1161/CIRCULATIONAHA.105.592055.
 145. Walker RE, Moran AM, Gauvreau K, Colan SD. Evidence of adverse ventricular interdependence in patients with atrial septal defects. *Am J Cardiol*. 2004;93:1374–1377. A6. doi: 10.1016/j.amjcard.2004.02.033.
 146. Konstam MA, Idoine J, Wynne J, Grossman W, Cohn L, Beck JR, Kozlowski J, Holman BL. Right ventricular function in adults with pulmonary hypertension with and without atrial septal defect. *Am J Cardiol*. 1983;51:1144–1148.
 147. Graham TP Jr, Bernard YD, Mellen BG, Celermajer D, Baumgartner H, Cetta F, Connolly HM, Davidson WR, Dellborg M, Foster E, Gersony WM, Gessner IH, Hurwitz RA, Kaemmerer H, Kugler JD, Murphy DJ, Noonan JA, Morris C, Perloff JK, Sanders SP, Sutherland JL. Long-term outcome in congenitally corrected transposition of the great arteries: a multi-institutional study. *J Am Coll Cardiol*. 2000;36:255–261.
 148. Hutter PA, Kreb DL, Mantel SF, Hitchcock JF, Meijboom EJ, Bennink GB. Twenty-five years’ experience with the arterial switch operation. *J Thorac Cardiovasc Surg*. 2002;124:790–797.
 149. Julsrud PR, Weigel TJ, Van Son JA, Edwards WD, Mair DD, Driscoll DJ, Danielson GK, Puga FJ, Offord KP. Influence of ventricular morphology on outcome after the Fontan procedure. *Am J Cardiol*. 2000;86:319–323.
 150. Rathod RH, Prakash A, Powell AJ, Geva T. Myocardial fibrosis identified by cardiac magnetic resonance late gadolinium enhancement is associated with adverse ventricular mechanics and ventricular tachycardia late

- after Fontan operation. *J Am Coll Cardiol*. 2010;55:1721–1728. doi: 10.1016/j.jacc.2009.12.036.
151. Zochios V, Jones N. Acute right heart syndrome in the critically ill patient. *Heart Lung Vessel*. 2014;6:157–170.
 152. Tongers J, Schwerdtfeger B, Klein G, Kempf T, Schaefer A, Knapp JM, Niehaus M, Korte T, Hoepfer MM. Incidence and clinical relevance of supraventricular tachyarrhythmias in pulmonary hypertension. *Am Heart J*. 2007;153:127–132. doi: 10.1016/j.ahj.2006.09.008.
 153. D'Alonzo GE, Barst RJ, Ayres SM, Bergofsky EH, Brundage BH, Detre KM, Fishman AP, Goldring RM, Groves BM, Kernis JT. Survival in patients with primary pulmonary hypertension: results from a national prospective registry. *Ann Intern Med*. 1991;115:343–349.
 154. Sandek A, Bauditz J, Swidsinski A, Buhner S, Weber-Eibel J, von Haehling S, Schroedel W, Karhausen T, Doeber W, Rauchhaus M, Poole-Wilson P, Volk HD, Lochs H, Anker SD. Altered intestinal function in patients with chronic heart failure. *J Am Coll Cardiol*. 2007;50:1561–1569. doi: 10.1016/j.jacc.2007.07.016.
 155. Verbrugge FH, Dupont M, Steels P, Grieten L, Malbrain M, Tang WH, Mullens W. Abdominal contributions to cardiorenal dysfunction in congestive heart failure. *J Am Coll Cardiol*. 2013;62:485–495. doi: 10.1016/j.jacc.2013.04.070.
 156. Kiernan M, Udelson JE, Sarnak M, Konstam MA. Cardiorenal syndrome: definition, prevalence, diagnosis, and pathophysiology. In: Post TW, ed. *UpToDate*. Waltham, MA: UpToDate; 2017.
 157. Damman K, van Deursen VM, Navis G, Voors AA, van Veldhuisen DJ, Hillege HL. Increased central venous pressure is associated with impaired renal function and mortality in a broad spectrum of patients with cardiovascular disease. *J Am Coll Cardiol*. 2009;53:582–588. doi: 10.1016/j.jacc.2008.08.080.
 158. Testani JM, Chen J, McCauley BD, Kimmel SE, Shannon RP. Potential effects of aggressive decongestion during the treatment of decompensated heart failure on renal function and survival. *Circulation*. 2010;122:265–272. doi: 10.1161/CIRCULATIONAHA.109.933275.
 159. Felker GM, Lee KL, Bull DA, Redfield MM, Stevenson LW, Goldsmith SR, LeWinter MM, Deswal A, Rouleau JL, Ofili EO, Anstrom KJ, Hernandez AF, McNulty SE, Velazquez EJ, Kfoury AG, Chen HH, Givertz MM, Semigran MJ, Bart BA, Mascette AM, Braunwald E, O'Connor CM; NHLBI Heart Failure Clinical Research Network. Diuretic strategies in patients with acute decompensated heart failure. *N Engl J Med*. 2011;364:797–805. doi: 10.1056/NEJMoa1005419.
 160. Bart BA, Goldsmith SR, Lee KL, Givertz MM, O'Connor CM, Bull DA, Redfield MM, Deswal A, Rouleau JL, LeWinter MM, Ofili EO, Stevenson LW, Semigran MJ, Felker GM, Chen HH, Hernandez AF, Anstrom KJ, McNulty SE, Velazquez EJ, Ibarra JC, Mascette AM, Braunwald E; Heart Failure Clinical Research Network. Ultrafiltration in decompensated heart failure with cardiorenal syndrome. *N Engl J Med*. 2012;367:2296–2304. doi: 10.1056/NEJMoa1210357.
 161. Chen HH, Anstrom KJ, Givertz MM, Stevenson LW, Semigran MJ, Goldsmith SR, Bart BA, Bull DA, Stehlik J, LeWinter MM, Konstam MA, Huggins GS, Rouleau JL, O'Meara E, Tang WH, Starling RC, Butler J, Deswal A, Felker GM, O'Connor CM, Bonita RE, Margulies KB, Cappola TP, Ofili EO, Mann DL, Dávila-Román VG, McNulty SE, Borlaug BA, Velazquez EJ, Lee KL, Shah MR, Hernandez AF, Braunwald E, Redfield MM; NHLBI Heart Failure Clinical Research Network. Low-dose dopamine or low-dose nesiritide in acute heart failure with renal dysfunction: the ROSE acute heart failure randomized trial. *JAMA*. 2013;310:2533–2543. doi: 10.1001/jama.2013.282190.
 162. Wang Y, Attar BM, Gandhi S, Jaiswal P, Bedsore S, Paranjani N, Sharma S. Characterization of ascites in cardiac cirrhosis: the value of ascitic fluid protein to screen for concurrent cardiac cirrhosis. *Scand J Gastroenterol*. 2017;52:898–903. doi: 10.1080/00365521.2017.1323230.
 163. Poelzl G, Ess M, Mussner-Seebler C, Pachinger O, Frick M, Ulmer H. Liver dysfunction in chronic heart failure: prevalence, characteristics and prognostic significance. *Eur J Clin Invest*. 2012;42:153–163. doi: 10.1111/j.1365-2362.2011.02573.x.
 164. Allen LA, Felker GM, Pocock S, McMurray JJ, Pfeffer MA, Swedberg K, Wang D, Yusuf S, Michelson EL, Granger CB; CHARM Investigators. Liver function abnormalities and outcome in patients with chronic heart failure: data from the Candesartan in Heart Failure: Assessment of Reduction in Mortality and Morbidity (CHARM) program. *Eur J Heart Fail*. 2009;11:170–177. doi: 10.1093/eurjhf/hfn031.
 165. Lau GT, Tan HC, Kritharides L. Type of liver dysfunction in heart failure and its relation to the severity of tricuspid regurgitation. *Am J Cardiol*. 2002;90:1405–1409.
 166. Takeda Y, Takeda Y, Tomimoto S, Tani T, Narita H, Kimura G. Bilirubin as a prognostic marker in patients with pulmonary arterial hypertension. *BMC Pulm Med*. 2010;10:22. doi: 10.1186/1471-2466-10-22.
 167. Mehra MR, Canter CE, Hannan MM, Semigran MJ, Uber PA, Baran DA, Danziger-Isakov L, Kirklin JK, Kirk R, Kushwaha SS, Lund LH, Potena L, Ross HJ, Taylor DO, Verschuuren EA, Zuckermann A; International Society for Heart Lung Transplantation (ISHLT) Infectious Diseases Council; International Society for Heart Lung Transplantation (ISHLT) Pediatric Transplantation Council; International Society for Heart Lung Transplantation (ISHLT) Heart Failure and Transplantation Council. The 2016 International Society for Heart Lung Transplantation listing criteria for heart transplantation: a 10-year update. *J Heart Lung Transplant*. 2016;35:1–23. doi: 10.1016/j.healun.2015.10.023.
 168. Safdar Z, Bartolome S, Sussman N. Portopulmonary hypertension: an update. *Liver Transpl*. 2012;18:881–891. doi: 10.1002/lt.23485.
 169. Frea S, Bovolo V, Pidello S, Canavosio FG, Botta M, Bergerone S, Gaita F. Clinical and prognostic role of ammonia in advanced decompensated heart failure: the cardio-abdominal syndrome? *Int J Cardiol*. 2015;195:53–60. doi: 10.1016/j.ijcard.2015.05.061.
 170. Meadows J, Gauvreau K, Jenkins K. Lymphatic obstruction and protein-losing enteropathy in patients with congenital heart disease. *Congenit Heart Dis*. 2008;3:269–276. doi: 10.1111/j.1747-0803.2008.00201.x.
 171. Arutyunov GP, Kostyukovich OI, Serov RA, Rylova NV, Bylova NA. Collagen accumulation and dysfunctional mucosal barrier of the small intestine in patients with chronic heart failure. *Int J Cardiol*. 2008;125:240–245. doi: 10.1016/j.ijcard.2007.11.103.
 172. Hiew C, Collins N, Foy A, Thomson D, Bastian B. Successful surgical treatment of protein-losing enteropathy complicating rheumatic tricuspid regurgitation. *Heart Lung Circ*. 2008;17:73–75. doi: 10.1016/j.hlc.2006.11.004.
 173. Itkin M, Piccoli DA, Nadolski G, Rychik J, DeVitt A, Pinto E, Rome J, Dori Y. Protein-losing enteropathy in patients with congenital heart disease. *J Am Coll Cardiol*. 2017;69:2929–2937. doi: 10.1016/j.jacc.2017.04.023.
 174. Wiese J. The abdominojugular reflux sign. *Am J Med*. 2000;109:59–61.
 175. Kucher N, Walpoth N, Wustmann K, Noveanu M, Gertsch M. QR in V1: an ECG sign associated with right ventricular strain and adverse clinical outcome in pulmonary embolism. *Eur Heart J*. 2003;24:1113–1119.
 176. Murphy ML, Thenabadu PN, de Soya N, Doherty JE, Meade J, Baker BJ, Whittle JL. Reevaluation of electrocardiographic criteria for left, right and combined cardiac ventricular hypertrophy. *Am J Cardiol*. 1984;53:1140–1147.
 177. Samsky MD, Patel CB, DeWald TA, Smith AD, Felker GM, Rogers JG, Hernandez AF. Cardiohepatic interactions in heart failure: an overview and clinical implications. *J Am Coll Cardiol*. 2013;61:2397–2405. doi: 10.1016/j.jacc.2013.03.042.
 178. Rudski LG, Lai WW, Afila J, Hua L, Handschumacher MD, Chandrasekaran K, Solomon SD, Louie EK, Schiller NB. Guidelines for the echocardiographic assessment of the right heart in adults: a report from the American Society of Echocardiography. *J Am Soc Echocardiogr*. 2010;23:685–713; quiz 786. doi: 10.1016/j.echo.2010.05.010.
 179. Hayek S, Sims DB, Markham DW, Butler J, Kalogeropoulos AP. Assessment of right ventricular function in left ventricular assist device candidates. *Circ Cardiovasc Imaging*. 2014;7:379–389. doi: 10.1161/CIRCIMAGING.113.001127.
 180. Kato TS, Jiang J, Schulze PC, Jorde U, Uriel N, Kitada S, Takayama H, Naka Y, Mancini D, Gillam L, Homma S, Farr M. Serial echocardiography using tissue Doppler and speckle tracking imaging to monitor right ventricular failure before and after left ventricular assist device surgery. *JACC Heart Fail*. 2013;1:216–222. doi: 10.1016/j.jchf.2013.02.005.
 181. Lai WW, Gauvreau K, Rivera ES, Saleeb S, Powell AJ, Geva T. Accuracy of guideline recommendations for two-dimensional quantification of the right ventricle by echocardiography. *Int J Cardiovasc Imaging*. 2008;24:691–698. doi: 10.1007/s10554-008-9314-4.
 182. Lang RM, Badano LP, Tsang W, Adams DH, Agricola E, Buck T, Faletra FF, Franke A, Hung J, de Isla LP, Kamp O, Kasprzak JD, Lancellotti P, Marwick TH, McCulloch ML, Monaghan MJ, Nihoyannopoulos P, Pandian NG, Pellikka PA, Pepi M, Roberson DA, Shernan SK, Shirali GS, Sugeng L, Ten Cate FJ, Vannan MA, Zamorano JL, Zoghbi WA; American Society of Echocardiography; European Association of Echocardiography. EAE/ASE recommendations for image acquisition and display using three-dimensional echocardiography. *J Am Soc Echocardiogr*. 2012;25:3–46. doi: 10.1016/j.echo.2011.11.010.
 183. Di Bello V, Conte L, Delle Donne MG, Giannini C, Barletta V, Fabiani I, Palagi C, Nardi C, Dini FL, Marconi L, Paggiaro P, Palla A, Marzilli M. Advantages of real time three-dimensional echocardiography in the assessment of right ventricular volumes and function in patients with pulmonary hypertension compared with conventional two-dimensional echocardiography. *Echocardiography*. 2013;30:820–828. doi: 10.1111/echo.12137.
 184. Li Y, Wang Y, Zhai Z, Guo X, Yang Y, Lu X. Real-time three-dimensional echocardiography to assess right ventricle function in patients with

- pulmonary hypertension. *PLoS One*. 2015;10:e0129557. doi: 10.1371/journal.pone.0129557.
185. van der Zwaan HB, Helbing WA, McGhie JS, Geleijnse ML, Luijnenburg SE, Roos-Hesselink JW, Meijboom FJ. Clinical value of real-time three-dimensional echocardiography for right ventricular quantification in congenital heart disease: validation with cardiac magnetic resonance imaging. *J Am Soc Echocardiogr*. 2010;23:134–140. doi: 10.1016/j.echo.2009.12.001.
 186. Surie S, Bouma BJ, Bruin-Bon RA, Hardziyenka M, Kloeck JJ, Van der Plas MN, Reesink HJ, Bresser P. Time course of restoration of systolic and diastolic right ventricular function after pulmonary endarterectomy for chronic thromboembolic pulmonary hypertension. *Am Heart J*. 2011;161:1046–1052. doi: 10.1016/j.ahj.2011.03.001.
 187. Utsunomiya H, Nakatani S, Nishihira M, Kanzaki H, Kyotani S, Nakanishi N, Kihara Y, Kitakaze M. Value of estimated right ventricular filling pressure in predicting cardiac events in chronic pulmonary arterial hypertension. *J Am Soc Echocardiogr*. 2009;22:1368–1374. doi: 10.1016/j.echo.2009.08.023.
 188. Guazzi M, Bandera F, Pelissero G, Castelvécchio S, Menicanti L, Ghio S, Temporelli PL, Arena R. Tricuspid annular plane systolic excursion and pulmonary arterial systolic pressure relationship in heart failure: an index of right ventricular contractile function and prognosis. *Am J Physiol Heart Circ Physiol*. 2013;305:H1373–H1381. doi: 10.1152/ajpheart.00157.2013.
 189. Mackey ES, Sandler MP, Campbell RM, Graham TP Jr, Atkinson JB, Price R, Moreau GA. Right ventricular myocardial mass quantification with magnetic resonance imaging. *Am J Cardiol*. 1990;65:529–532.
 190. Pattynama PM, Lamb HJ, Van der Velde EA, Van der Geest RJ, Van der Wall EE, De Roos A. Reproducibility of MRI-derived measurements of right ventricular volumes and myocardial mass. *Magn Reson Imaging*. 1995;13:53–63.
 191. Katz J, Whang J, Boxt LM, Barst RJ. Estimation of right ventricular mass in normal subjects and in patients with primary pulmonary hypertension by nuclear magnetic resonance imaging. *J Am Coll Cardiol*. 1993;21:1475–1481.
 192. Geva T. Repaired tetralogy of Fallot: the roles of cardiovascular magnetic resonance in evaluating pathophysiology and for pulmonary valve replacement decision support. *J Cardiovasc Magn Reson*. 2011;13:9. doi: 10.1186/1532-429X-13-9.
 193. Wald RM, Valente AM, Gauvreau K, Babu-Narayan SV, Assenza GE, Schreier J, Gatzoulis MA, Kilner PJ, Koyak Z, Mulder B, Powell AJ, Geva T. Cardiac magnetic resonance markers of progressive RV dilation and dysfunction after tetralogy of Fallot repair. *Heart*. 2015;101:1724–1730. doi: 10.1136/heartjnl-2015-308014.
 194. Zhu Y, Liu J, Weinsaft J, Spincemaille P, Nguyen TD, Prince MR, Bao S, Xie Y, Wang Y. Free-breathing 3D imaging of right ventricular structure and function using respiratory and cardiac self-gated cine MRI. *Biomed Res Int*. 2015;2015:819102. doi: 10.1155/2015/819102.
 195. Gopalan D. Right heart on multidetector CT. *Br J Radiol*. 2011;84(Spec No 3):S306–S323. doi: 10.1259/bjir/59278996.
 196. Plümhans C, Mühlenthal G, Rapae A, Sim KH, Seyfarth T, Günther RW, Mahnen AH. Assessment of global right ventricular function on 64-MDCT compared with MRI. *AJR Am J Roentgenol*. 2008;190:1358–1361. doi: 10.2214/AJR.07.3022.
 197. Oikawa M, Kagaya Y, Otani H, Sakuma M, Demachi J, Suzuki J, Takahashi T, Nawata J, Ido T, Watanabe J, Shirato K. Increased [18F]fluorodeoxyglucose accumulation in right ventricular free wall in patients with pulmonary hypertension and the effect of epoprostenol. *J Am Coll Cardiol*. 2005;45:1849–1855. doi: 10.1016/j.jacc.2005.02.065.
 198. Piao L, Fang YH, Cadete VJ, Wietholt C, Urboniene D, Toth PT, Marsboom G, Zhang HJ, Haber I, Rehman J, Lopaschuk GD, Archer SL. The inhibition of pyruvate dehydrogenase kinase improves impaired cardiac function and electrical remodeling in two models of right ventricular hypertrophy: resuscitating the hibernating right ventricle. *J Mol Med (Berl)*. 2010;88:47–60. doi: 10.1007/s00109-009-0524-6.
 199. Lupi E, Dumont C, Tejada VM, Horwitz S, Galland F. A radiologic index of pulmonary arterial hypertension. *Chest*. 1975;68:28–31.
 200. Matthay RA, Schwarz MI, Ellis JH Jr, Steele PP, Siebert PE, Durrance JR, Levin DC. Pulmonary artery hypertension in chronic obstructive pulmonary disease: determination by chest radiography. *Invest Radiol*. 1981;16:95–100.
 201. Atluri P, Goldstone AB, Fairman AS, MacArthur JW, Shudo Y, Cohen JE, Acker AL, Hiesinger W, Howard JL, Acker MA, Woo YJ. Predicting right ventricular failure in the modern, continuous flow left ventricular assist device era. *Ann Thorac Surg*. 2013;96:857–863.
 202. Lopez-Sendon J, Coma-Canella I, Gamallo C. Sensitivity and specificity of hemodynamic criteria in the diagnosis of acute right ventricular infarction. *Circulation*. 1981;64:515–525. doi: 10.1161/01.CIR.64.3.515.
 203. Korabathina R, Heffernan KS, Paruchuri V, Patel AR, Mudd JO, Prutkin JM, Orr NM, Weintraub A, Kimmelstiel CD, Kapur NK. The pulmonary artery pulsatility index identifies severe right ventricular dysfunction in acute inferior myocardial infarction. *Catheter Cardiovasc Interv*. 2012;80:593–600. doi: 10.1002/ccd.23309.
 204. Morine KJ, Kiernan MS, Pham DT, Paruchuri V, Denofrio D, Kapur NK. Pulmonary artery pulsatility index is associated with right ventricular failure after left ventricular assist device surgery. *J Card Fail*. 2016;22:110–116. doi: 10.1016/j.cardfail.2015.10.019.
 205. Fitzpatrick JR 3rd, Frederick JR, Hsu VM, Kozin ED, O'Hara ML, Howell E, Dougherty D, McCormick RC, Laporte CA, Cohen JE, Southerland KW, Howard JL, Jessup ML, Morris RJ, Acker MA, Woo YJ. Risk score derived from pre-operative data analysis predicts the need for biventricular mechanical circulatory support. *J Heart Lung Transplant*. 2008;27:1286–1292.
 206. Fukamachi K, McCarthy PM, Smedira NG, Vargo RL, Starling RC, Young JB. Preoperative risk factors for right ventricular failure after implantable left ventricular assist device insertion. *Ann Thorac Surg*. 1999;68:2181–2184.
 207. Drakos SG, Janicki L, Horne BD, Kfoury AG, Reid BB, Clayson S, Horton K, Haddad F, Li DY, Renlund DG, Fisher PV. Risk factors predictive of right ventricular failure after left ventricular assist device implantation. *Am J Cardiol*. 2010;105:1030–1035. doi: 10.1016/j.amjcard.2009.11.026.
 208. Kapur NK, Esposito ML, Bader Y, Morine KJ, Kiernan MS, Pham DT, Burkhoff D. Mechanical circulatory support devices for acute right ventricular failure. *Circulation*. 2017;136:314–326. doi: 10.1161/CIRCULATIONAHA.116.025290.
 209. Drazner MH, Hamilton MA, Fonarow G, Creaser J, Flavell C, Stevenson LW. Relationship between right and left-sided filling pressures in 1000 patients with advanced heart failure. *J Heart Lung Transplant*. 1999;18:1126–1132.
 210. Campbell P, Drazner MH, Kato M, Lakdawala N, Palardy M, Nohria A, Stevenson LW. Mismatch of right- and left-sided filling pressures in chronic heart failure. *J Card Fail*. 2011;17:561–568. doi: 10.1016/j.cardfail.2011.02.013.
 211. Reed CE, Dorman BH, Spinale FG. Assessment of right ventricular contractile performance after pulmonary resection. *Ann Thorac Surg*. 1993;56:426–431.
 212. Grant AD, Smedira NG, Starling RC, Marwick TH. Independent and incremental role of quantitative right ventricular evaluation for the prediction of right ventricular failure after left ventricular assist device implantation. *J Am Coll Cardiol*. 2012;60:521–528. doi: 10.1016/j.jacc.2012.02.073.
 213. Ochiai Y, McCarthy PM, Smedira NG, Banbury MK, Navia JL, Feng J, Hsu AP, Yeager ML, Buda T, Hoercher KJ, Howard MW, Takagaki M, Doi K, Fukamachi K. Predictors of severe right ventricular failure after implantable left ventricular assist device insertion: analysis of 245 patients. *Circulation*. 2002;106(suppl 1):I198–I202.
 214. Kirklin JK, Naftel DC, Pagani FD, Kormos RL, Stevenson LW, Blume ED, Myers SL, Miller MA, Baldwin JT, Young JB. Seventh INTERMACS annual report: 15,000 patients and counting. *J Heart Lung Transplant*. 2015;34:1495–1504.
 215. Slaughter MS, Rogers JG, Milano CA, Russell SD, Conte JV, Feldman D, Sun B, Tatooles AJ, Delgado RM 3rd, Long JW, Wozniak TC, Ghumman W, Farrar DJ, Frazier OH; HeartMate II Investigators. Advanced heart failure treated with continuous-flow left ventricular assist device. *N Engl J Med*. 2009;361:2241–2251. doi: 10.1056/NEJMoa0909938.
 216. Matthews JC, Koelling TM, Pagani FD, Aaronson KD. The right ventricular failure risk score: a pre-operative tool for assessing the risk of right ventricular failure in left ventricular assist device candidates. *J Am Coll Cardiol*. 2008;51:2163–2172. doi: 10.1016/j.jacc.2008.03.009.
 217. Kalogeropoulos AP, Kelkar A, Weinberger JF, Morris AA, Georgiopoulos VV, Markham DW, Butler J, Vega JD, Smith AL. Validation of clinical scores for right ventricular failure prediction after implantation of continuous-flow left ventricular assist devices. *J Heart Lung Transplant*. 2015;34:1595–1603. doi: 10.1016/j.healun.2015.05.005.
 218. Kormos RL, Gasior TA, Kawai A, Pham SM, Murali S, Hattler BG, Griffith BP. Transplant candidate's clinical status rather than right ventricular function defines need for univentricular versus biventricular support. *J Thorac Cardiovasc Surg*. 1996;111:773–782.
 219. Pagani FD, Lynch W, Swaniker F, Dyke DB, Bartlett R, Koelling T, Moscucci M, Deeb GM, Bolling S, Monaghan H, Aaronson KD. Extracorporeal life support to left ventricular assist device bridge to heart transplant: a strategy to optimize survival and resource utilization. *Circulation*. 1999;100(suppl):II206–II210. doi: 10.1161/01.CIR.100.suppl_2.II-206.
 220. Braunwald E. Biomarkers in heart failure. *N Engl J Med*. 2008;358:2148–2159. doi: 10.1056/NEJMra0800239.
 221. Cepkova M, Kapur V, Ren X, Quinn T, Zhuo H, Foster E, Matthay MA, Liu KD. Clinical significance of elevated B-type natriuretic peptide in patients with acute lung injury with or without right ventricular dilatation:

- an observational cohort study. *Ann Intensive Care*. 2011;1:18. doi: 10.1186/2110-5820-1-18.
222. Troughton RW, Prior DL, Pereira JJ, Martin M, Fogarty A, Morehead A, Yandle TG, Richards AM, Starling RC, Young JB, Thomas JD, Klein AL. Plasma B-type natriuretic peptide levels in systolic heart failure: importance of left ventricular diastolic function and right ventricular systolic function. *J Am Coll Cardiol*. 2004;43:416–422. doi: 10.1016/j.jacc.2003.08.046.
 223. Mariano-Goulart D, Eberlé MC, Boudousq V, Hejazi-Moughari A, Piot C, Caderas de Kerleau C, Verdier R, Barge ML, Comte F, Bressot N, Rossi M, Kotzki PO. Major increase in brain natriuretic peptide indicates right ventricular systolic dysfunction in patients with heart failure. *Eur J Heart Fail*. 2003;5:481–488.
 224. Benza RL, Gombert-Maitland M, Miller DP, Frost A, Frantz RP, Foreman AJ, Badesch DB, McGoon MD. The REVEAL Registry risk score calculator in patients newly diagnosed with pulmonary arterial hypertension. *Chest*. 2012;141:354–362. doi: 10.1378/chest.11-0676.
 225. Mehta NJ, Jani K, Khan IA. Clinical usefulness and prognostic value of elevated cardiac troponin I levels in acute pulmonary embolism. *Am Heart J*. 2003;145:821–825. doi: 10.1016/S0002-8703(02)94704-6.
 226. Lim W, Cook DJ, Griffith LE, Crowther MA, Devereaux PJ. Elevated cardiac troponin levels in critically ill patients: prevalence, incidence, and outcomes. *Am J Crit Care*. 2006;15:280–8; quiz 289.
 227. Torbicki A, Kurzyńska M, Kuca P, Fijałkowska A, Sikora J, Florczyk M, Pruszczyk P, Burakowski J, Wawrzyńska L. Detectable serum cardiac troponin T as a marker of poor prognosis among patients with chronic precapillary pulmonary hypertension. *Circulation*. 2003;108:844–848. doi: 10.1161/01.CIR.0000084544.54513.E2.
 228. Cavallazzi R, Nair A, Vasu T, Marik PE. Natriuretic peptides in acute pulmonary embolism: a systematic review. *Intensive Care Med*. 2008;34:2147–2156. doi: 10.1007/s00134-008-1214-5.
 229. Becattini C, Casazza F, Forgiione C, Porro F, Fadin BM, Stucchi A, Lignani A, Conte L, Imperadore F, Bongarzone A, Agnelli G. Acute pulmonary embolism: external validation of an integrated risk stratification model. *Chest*. 2013;144:1539–1545. doi: 10.1378/chest.12-2938.
 230. Wang XM, Zhang K, Li Y, Shi K, Liu YL, Yang YF, Fang Y, Mao M. Screening miRNA and their target genes related to tetralogy of Fallot with microarray. *Cardiol Young*. 2014;24:442–446. doi: 10.1017/S104795111300053X.
 231. Li D, Ji L, Liu L, Liu Y, Hou H, Yu K, Sun Q, Zhao Z. Characterization of circulating microRNA expression in patients with a ventricular septal defect. *PLoS One*. 2014;9:e106318. doi: 10.1371/journal.pone.0106318.
 232. Lai CT, Ng EK, Chow PC, Kwong A, Cheung YF. Circulating microRNA expression profile and systemic right ventricular function in adults after atrial switch operation for complete transposition of the great arteries. *BMC Cardiovasc Disord*. 2013;13:73. doi: 10.1186/1471-2261-13-73.
 233. Lai CT, Chow PC, Wong SJ, Chan KW, Cheung YF. Circulating annexin A5 levels after atrial switch for transposition of the great arteries: relationship with ventricular deformation and geometry. *PLoS One*. 2012;7:e52125. doi: 10.1371/journal.pone.0052125.
 234. Lai CT, Chan KW, Wong SJ, Chow PC, Cheung YF. Circulating levels of biomarkers of collagen synthesis and ventricular function and dyssynchrony in adolescents and young adults after repair of tetralogy of Fallot. *Am Heart J*. 2011;162:467–473. doi: 10.1016/j.ahj.2011.05.027.
 235. Tutarel O, Röntgen P, Bode-Böger SM, Martens-Lobenhoffer J, Westhoff-Bleck M, Diller GP, Bauersachs J, Kielstein JT. Symmetrical dimethylarginine is superior to NT-proBNP for detecting systemic ventricular dysfunction in adults after atrial repair for transposition of the great arteries. *Int J Cardiol*. 2013;168:4415–4416. doi: 10.1016/j.ijcard.2013.05.030.
 236. Shah A, Feraco AM, Harmon C, Tacy T, Fineman JR, Bernstein HS. Usefulness of various plasma biomarkers for diagnosis of heart failure in children with single ventricle physiology. *Am J Cardiol*. 2009;104:1280–1284. doi: 10.1016/j.amjcard.2009.06.046.
 237. Nagendran J, Gurtu V, Fu DZ, Dyck JR, Haromy A, Ross DB, Rebeyka IM, Michelakis ED. A dynamic and chamber-specific mitochondrial remodeling in right ventricular hypertrophy can be therapeutically targeted. *J Thorac Cardiovasc Surg*. 2008;136:168–178. doi: 10.1016/j.jtcvs.2008.01.040.
 238. Reddy S, Bernstein D. Molecular mechanisms of right ventricular failure. *Circulation*. 2015;132:1734–1742. doi: 10.1161/CIRCULATIONAHA.114.012975.
 239. Di Salvo TG, Yang KC, Brittain E, Absi T, Maltas S, Hemnes A. Right ventricular myocardial biomarkers in human heart failure. *J Card Fail*. 2015;21:398–411. doi: 10.1016/j.cardfail.2015.02.005.
 240. Lewis GD, Ngo D, Hemnes AR, Farrell L, Doms C, Pappagianopoulos PP, Dhakal BP, Souza A, Shi X, Pugh ME, Beloiartsev A, Sinha S, Clish CB, Gerszten RE. Metabolic profiling of right ventricular-pulmonary vascular function reveals circulating biomarkers of pulmonary hypertension. *J Am Coll Cardiol*. 2016;67:174–189. doi: 10.1016/j.jacc.2015.10.072.
 241. Reddy S, Zhao M, Hu DQ, Fajardo G, Katznelson E, Punn R, Spin JM, Chan FP, Bernstein D. Physiologic and molecular characterization of a murine model of right ventricular volume overload. *Am J Physiol Heart Circ Physiol*. 2013;304:H1314–H1327. doi: 10.1152/ajpheart.00776.2012.
 242. Di Salvo TG. Evolving targeted therapies for right ventricular failure. *Expert Opin Biol Ther*. 2015;15:1263–1283.
 243. Piazza G, Goldhaber SZ. The acutely decompensated right ventricle: pathways for diagnosis and management. *Chest*. 2005;128:1836–1852. doi: 10.1378/chest.128.3.1836.
 244. Price LC, Wort SJ, Finney SJ, Marino PS, Brett SJ. Pulmonary vascular and right ventricular dysfunction in adult critical care: current and emerging options for management: a systematic literature review. *Crit Care*. 2010;14:R169. doi: 10.1186/cc9264.
 245. Yancy CW, Jessup M, Bozkurt B, Butler J, Casey DE Jr, Drazner MH, Fonarow GC, Geraci SA, Horwich T, Januzzi JL, Johnson MR, Kasper EK, Levy WC, Masoudi FA, McBride PE, McMurray JJV, Mitchell JE, Peterson PN, Riegel B, Sam F, Stevenson LW, Tang WHW, Tsai EJ, Wilkoff BL. 2013 ACCF/AHA guideline for the management of heart failure: a report of the American College of Cardiology Foundation/American Heart Association Task Force on Practice Guidelines. *Circulation*. 2013;128:e240–e327. doi: 10.1161/CIR.0b013e31829e8776.
 246. Vonk Noordegraaf A, Westerhof BE, Westerhof N. The relationship between the right ventricle and its load in pulmonary hypertension. *J Am Coll Cardiol*. 2017;69:236–243. doi: 10.1016/j.jacc.2016.10.047.
 247. Banerjee D, Haddad F, Zamanian RT, Nagendran J. Right ventricular failure: a novel era of targeted therapy. *Curr Heart Fail Rep*. 2010;7:202–211. doi: 10.1007/s11897-010-0031-7.
 248. Dell'Italia LJ, Starling MR, Blumhardt R, Lasher JC, O'Rourke RA. Comparative effects of volume loading, dobutamine, and nitroprusside in patients with predominant right ventricular infarction. *Circulation*. 1985;72:1327–1335. doi: 10.1161/01.CIR.72.6.1327.
 249. Marenzi G, Lauri G, Grazi M, Assanelli E, Campodonico J, Agostoni P. Circulatory response to fluid overload removal by extracorporeal ultrafiltration in refractory congestive heart failure. *J Am Coll Cardiol*. 2001;38:963–968.
 250. Dupont M, Mullens W, Tang WH. Impact of systemic venous congestion in heart failure. *Curr Heart Fail Rep*. 2011;8:233–241. doi: 10.1007/s11897-011-0071-7.
 251. Wencker D. Acute cardio-renal syndrome: progression from congestive heart failure to congestive kidney failure. *Curr Heart Fail Rep*. 2007;4:134–138.
 252. Ellison DH. Diuretic therapy and resistance in congestive heart failure. *Cardiology*. 2001;96:132–143.
 253. Bart BA, Goldsmith SR, Lee KL, Redfield MM, Felker GM, O'Connor CM, Chen HH, Rouleau JL, Givertz MM, Semigran MJ, Mann D, Deswal A, Bull DA, Lewinter MM, Braunwald E; Heart Failure Clinical Research Network. Cardiorenal rescue study in acute decompensated heart failure: rationale and design of CARRESS-HF. *J Card Fail*. 2012;18:176–182. doi: 10.1016/j.cardfail.2011.12.009.
 254. Boerrigter G, Burnett JC Jr. Cardiorenal syndrome in decompensated heart failure: prognostic and therapeutic implications. *Curr Heart Fail Rep*. 2004;1:113–120.
 255. Butler J, Hernandez AF, Anstrom KJ, Kalogeropoulos A, Redfield MM, Konstam MA, Tang WH, Felker GM, Shah MR, Braunwald E. Rationale and design of the ATHENA-HF Trial: Aldosterone Targeted Neurohormonal Combined With Natriuresis Therapy in Heart Failure. *JACC Heart Fail*. 2016;4:726–735. doi: 10.1016/j.jchf.2016.06.003.
 256. van der Meer P, Postmus D, Ponikowski P, Cleland JG, O'Connor CM, Cotter G, Metra M, Davison BA, Givertz MM, Mansoor GA, Teerlink JR, Massie BM, Hillege HL, Voors AA. The predictive value of short-term changes in hemoglobin concentration in patients presenting with acute decompensated heart failure. *J Am Coll Cardiol*. 2013;61:1973–1981. doi: 10.1016/j.jacc.2012.12.050.
 257. Costanzo MR, Saltzberg M, O'Sullivan J, Sobotka P. Early ultrafiltration in patients with decompensated heart failure and diuretic resistance. *J Am Coll Cardiol*. 2005;46:2047–2051. doi: 10.1016/j.jacc.2005.05.099.
 258. Costanzo MR, Negoianu D, Jaski BE, Bart BA, Heywood JT, Anand IS, Smelser JM, Kaneshige AM, Chomsky DB, Adler ED, Haas GJ, Watts JA, Nabut JL, Schollmeyer MP, Fonarow GC. Aquapheresis versus intravenous diuretics and hospitalizations for heart failure. *JACC Heart Fail*. 2016;4:95–105.

259. Morelli A, Teboul JL, Maggiore SM, Vieillard-Baron A, Rocco M, Conti G, De Gaetano A, Picchini U, Orecchioni A, Carbone I, Tritapepe L, Pietropaoli P, Westphal M. Effects of levosimendan on right ventricular afterload in patients with acute respiratory distress syndrome: a pilot study. *Crit Care Med*. 2006;34:2287–2293. doi: 10.1097/01.CCM.0000230244.17174.4F.
260. Inglese I, Shin JT, Lepore JJ, Palacios IF, Zapol WM, Bloch KD, Semigran MJ. Hemodynamic effects of inhaled nitric oxide in right ventricular myocardial infarction and cardiogenic shock. *J Am Coll Cardiol*. 2004;44:793–798. doi: 10.1016/j.jacc.2004.05.047.
261. Mullens W, Abrahams Z, Francis GS, Skouri HN, Starling RC, Young JB, Taylor DO, Tang WH. Sodium nitroprusside for advanced low-output heart failure. *J Am Coll Cardiol*. 2008;52:200–207. doi: 10.1016/j.jacc.2008.02.083.
262. Stevenson LW, Bellil D, Grover-McKay M, Brunken RC, Schwaiger M, Tillich JH, Schelbert HR. Effects of afterload reduction (diuretics and vasodilators) on left ventricular volume and mitral regurgitation in severe congestive heart failure secondary to ischemic or idiopathic dilated cardiomyopathy. *Am J Cardiol*. 1987;60:654–658.
263. Elkayam U, Kulick D, McIntosh N, Roth A, Hsueh W, Rahimtoola SH. Incidence of early tolerance to hemodynamic effects of continuous infusion of nitroglycerin in patients with coronary artery disease and heart failure. *Circulation*. 1987;76:577–584.
264. Califf RM, Adams KF, McKenna WJ, Gheorghiade M, Uretsky BF, McNulty SE, Darius H, Schulman K, Zannad F, Handberg-Thurmond E, Harrell FE Jr, Wheeler W, Soler-Soler J, Swedberg K. A randomized controlled trial of epoprostenol therapy for severe congestive heart failure: the Flolan International Randomized Survival Trial (FIRST). *Am Heart J*. 1997;134:44–54.
265. Cockrill BA, Kacmarek RM, Fifer MA, Bigatello LM, Ginns LC, Zapol WM, Semigran MJ. Comparison of the effects of nitric oxide, nitroprusside, and nifedipine on hemodynamics and right ventricular contractility in patients with chronic pulmonary hypertension. *Chest*. 2001;119:128–136.
266. Koelling TM, Kirmse M, Di Salvo TG, Dec GW, Zapol WM, Semigran MJ. Inhaled nitric oxide improves exercise capacity in patients with severe heart failure and right ventricular dysfunction. *Am J Cardiol*. 1998;81:1494–1497.
267. Pasero D, Rana NK, Bonato R, Ribezzo M, Ivaldi F, Ricci D, Grosso Marra W, Checco L, Lupo M, Boffini M, Rinaldi M. Inhaled nitric oxide versus sodium nitroprusside for preoperative evaluation of pulmonary hypertension in heart transplant candidates. *Transplant Proc*. 2013;45:2746–2749. doi: 10.1016/j.transproceed.2013.07.044.
268. Wasson S, Govindarajan G, Reddy HK, Flaker G. The role of nitric oxide and vasopressin in refractory right heart failure. *J Cardiovasc Pharmacol Ther*. 2004;9:9–11. doi: 10.1177/107424840400900102.
269. Trummer G, Berchtold-Herz M, Martin J, Beyersdorf F. Successful treatment of pulmonary hypertension with inhaled nitric oxide after pulmonary embolectomy. *Ann Thorac Surg*. 2002;73:1299–1301.
270. Argenziano M, Choudhri AF, Moazami N, Rose EA, Smith CR, Levin HR, Smerling AJ, Oz MC. Randomized, double-blind trial of inhaled nitric oxide in LVAD recipients with pulmonary hypertension. *Ann Thorac Surg*. 1998;65:340–345.
271. Kukucka M, Potapov E, Stepanenko A, Weller K, Mladenow A, Kuppe H, Habazettl H. Acute impact of left ventricular unloading by left ventricular assist device on the right ventricle geometry and function: effect of nitric oxide inhalation. *J Thorac Cardiovasc Surg*. 2011;141:1009–1014. doi: 10.1016/j.jtcvs.2010.08.010.
272. Lovich MA, Pezone MJ, Wakim MG, Denton RJ, Maslov MY, Murray MR, Tsukada H, Agnihotri AK, Roscigno RF, Gamero LG, Gilbert RJ. Inhaled nitric oxide augments left ventricular assist device capacity by ameliorating secondary right ventricular failure. *ASAIO J*. 2015;61:379–385. doi: 10.1097/MAT.0000000000000211.
273. Bocchi EA, Bacal F, Auler Júnior JO, Carmone MJ, Bellotti G, Pileggi F. Inhaled nitric oxide leading to pulmonary edema in stable severe heart failure. *Am J Cardiol*. 1994;74:70–72.
274. Baker WL, Radojevic J, Gluck JA. Systematic review of phosphodiesterase-5 inhibitor use in right ventricular failure following left ventricular assist device implantation. *Artif Organs*. 2016;40:123–128. doi: 10.1111/aor.12518.
275. Critoph C, Green G, Hayes H, Baumwöl J, Lam K, Larbalestier R, Chih S. Clinical outcomes of patients treated with pulmonary vasodilators early and in high dose after left ventricular assist device implantation. *Artif Organs*. 2016;40:106–114. doi: 10.1111/aor.12502.
276. Felker GM, Benza RL, Chandler AB, Leimberger JD, Cuffe MS, Califf RM, Gheorghiade M, O'Connor CM; OPTIME-CHF Investigators. Heart failure etiology and response to milrinone in decompensated heart failure: results from the OPTIME-CHF study. *J Am Coll Cardiol*. 2003;41:997–1003.
277. Sonnenblick EH, Frishman WH, Lejemtel TH. Dobutamine: a new synthetic cardioactive sympathetic amine. *N Engl J Med*. 1979;300:17–22. doi: 10.1056/NEJM197901043000105.
278. Ruffolo RR Jr. The pharmacology of dobutamine. *Am J Med Sci*. 1987;294:244–248.
279. Movsesian M, Stehlik J, Vandeput F, Bristow MR. Phosphodiesterase inhibition in heart failure. *Heart Fail Rev*. 2009;14:255–263. doi: 10.1007/s10741-008-9130-x.
280. Aranda JM Jr, Schofield RS, Pauly DF, Cleeton TS, Walker TC, Monroe VS Jr, Leach D, Lopez LM, Hill JA. Comparison of dobutamine versus milrinone therapy in hospitalized patients awaiting cardiac transplantation: a prospective, randomized trial. *Am Heart J*. 2003;145:324–329. doi: 10.1067/mhj.2003.50.
281. Mehra MR, Ventura HO, Kapoor C, Stapleton DD, Zimmerman D, Smart FW. Safety and clinical utility of long-term intravenous milrinone in advanced heart failure. *Am J Cardiol*. 1997;80:61–64.
282. Colucci WS, Wright RF, Jaski BE, Fifer MA, Braunwald E. Milrinone and dobutamine in severe heart failure: differing hemodynamic effects and individual patient responsiveness. *Circulation*. 1986;73(pt 2):III175–III183.
283. Monrad ES, Baim DS, Smith HS, Lanoue AS. Milrinone, dobutamine, and nitroprusside: comparative effects on hemodynamics and myocardial energetics in patients with severe congestive heart failure. *Circulation*. 1986;73:III168–III174.
284. Kanai-Yoshizawa S, Sugiyama Kato T, Mancini D, Marboe CC. Hypersensitivity myocarditis and outcome after heart transplantation. *J Heart Lung Transplant*. 2013;32:553–559. doi: 10.1016/j.healun.2013.01.1052.
285. Abraham WT, Adams KF, Fonarow GC, Costanzo MR, Berkowitz RL, Lejemtel TH, Cheng ML, Wynne J; ADHERE Scientific Advisory Committee and Investigators; ADHERE Study Group. In-hospital mortality in patients with acute decompensated heart failure requiring intravenous vasoactive medications: an analysis from the Acute Decompensated Heart Failure National Registry (ADHERE). *J Am Coll Cardiol*. 2005;46:57–64. doi: 10.1016/j.jacc.2005.03.051.
286. O'Connor CM, Gattis WA, Uretsky BF, Adams KF Jr, McNulty SE, Grossman SH, McKenna WJ, Zannad F, Swedberg K, Gheorghiade M, Califf RM. Continuous intravenous dobutamine is associated with an increased risk of death in patients with advanced heart failure: insights from the Flolan International Randomized Survival Trial (FIRST). *Am Heart J*. 1999;138(pt 1):78–86.
287. Felker GM, O'Connor CM. Inotropic therapy for heart failure: an evidence-based approach. *Am Heart J*. 2001;142:393–401. doi: 10.1067/mhj.2001.117606.
288. Packer M, Carver JR, Rodeheffer RJ, Ivanhoe RJ, DiBianco R, Zeldis SM, Hendrix GH, Bommer WJ, Elkayam U, Kukin ML. Effect of oral milrinone on mortality in severe chronic heart failure: the PROMISE Study Research Group. *N Engl J Med*. 1991;325:1468–1475. doi: 10.1056/NEJM199111213252103.
289. De Backer D, Biston P, Devriendt J, Madl C, Chochrad D, Aldecoa C, Brasseur A, Defrance P, Gottignies P, Vincent JL; SOAP II Investigators. Comparison of dopamine and norepinephrine in the treatment of shock. *N Engl J Med*. 2010;362:779–789. doi: 10.1056/NEJMoa0907118.
290. Murphy MB, Elliott WJ. Dopamine and dopamine receptor agonists in cardiovascular therapy. *Crit Care Med*. 1990;18(pt 2):S14–S18.
291. Løllgen H, Drexler H. Use of inotropes in the critical care setting. *Crit Care Med*. 1990;18(pt 2):S56–S60.
292. Holmes CL, Patel BM, Russell JA, Walley KR. Physiology of vasopressin relevant to management of septic shock. *Chest*. 2001;120:989–1002.
293. Edwards RM, Trizna W, Kinter LB. Renal microvascular effects of vasopressin and vasopressin antagonists. *Am J Physiol*. 1989;256(pt 2):F274–F278. doi: 10.1152/ajprenal.1989.256.2.F274.
294. Testani JM, Khera AV, St John Sutton MG, Keane MG, Wiegers SE, Shannon RP, Kirkpatrick JN. Effect of right ventricular function and venous congestion on cardiorenal interactions during the treatment of decompensated heart failure. *Am J Cardiol*. 2010;105:511–516. doi: 10.1016/j.amjcard.2009.10.020.
295. Vasko MR, Cartwright DB, Knoche JP, Nixon JV, Brater DC. Furosemide absorption altered in decompensated congestive heart failure. *Ann Intern Med*. 1985;102:314–318.

296. Cosin J, Díez J; TORIC Investigators. Torasemide in chronic heart failure: results of the TORIC study. *Eur J Heart Fail*. 2002;4:507–513.
297. Ponikowski P, Voors AA, Anker SD, Bueno H, Cleland JG, Coats AJ, Falk V, González-Juanatey JR, Harjola VP, Jankowska EA, Jessup M, Linde C, Nihoyannopoulos P, Parissis JT, Pieske B, Riley JP, Rosano GM, Ruilope LM, Ruschitzka F, Rutten FH, van der Meer P. 2016 ESC guidelines for the diagnosis and treatment of acute and chronic heart failure: the Task Force for the Diagnosis and Treatment of Acute and Chronic Heart Failure of the European Society of Cardiology (ESC). *Eur Heart J*. 2016;37:2129–2200. doi: 10.1093/eurheartj/ehw128.
298. Yancy CW, Jessup M, Bozkurt B, Butler J, Casey DE Jr, Colvin MM, Drazner MH, Filippatos G, Fonarow GC, Givertz MM, Hollenberg SM, Lindenfeld J, Masoudi FA, McBride PE, Peterson PN, Stevenson LW, Westlake C. 2016 ACC/AHA/HFSA focused update on new pharmacological therapy for heart failure: an update of the 2013 ACCF/AHA guideline for the management of heart failure: a report of the American College of Cardiology/American Heart Association Task Force on Clinical Practice Guidelines and the Heart Failure Society of America. *Circulation*. 2016;134:e282–e293. doi: 10.1161/CIR.0000000000000435.
299. Beck-da-Silva L, de Bold A, Davies R, Chow B, Ruddy T, Fraser M, Struthers C, Haddad H. Effect of bisoprolol on right ventricular function and brain natriuretic peptide in patients with heart failure. *Congest Heart Fail*. 2004;10:127–132.
300. Cho MJ, Lim RK, Jung Kwak M, Park KH, Kim HY, Kim YM, Lee HD. Effects of beta-blockers for congestive heart failure in pediatric and congenital heart disease patients: a meta-analysis of published studies. *Minerva Cardioangiol*. 2015;63:495–505.
301. Doughan AR, McConnell ME, Book WM. Effect of beta blockers (carvedilol or metoprolol XL) in patients with transposition of great arteries and dysfunction of the systemic right ventricle. *Am J Cardiol*. 2007;99:704–706. doi: 10.1016/j.amjcard.2006.10.025.
302. Giardini A, Lovato L, Donti A, Formigari R, Gargiulo G, Picchio FM, Fattori R. A pilot study on the effects of carvedilol on right ventricular remodelling and exercise tolerance in patients with systemic right ventricle. *Int J Cardiol*. 2007;114:241–246. doi: 10.1016/j.ijcard.2006.01.048.
303. Hiroi Y, Fujii K, Komatsu S, Sonoda M, Sakomura Y, Imai Y, Oishi Y, Nakamura F, Ajiki K, Hayami N, Murakawa Y, Ohno M, Hirata Y, Ohtomo K, Nagai R. Carvedilol therapy improved left ventricular function in a patient with arrhythmogenic right ventricular cardiomyopathy. *Jpn Heart J*. 2004;45:169–177.
304. Quaife RA, Christian PE, Gilbert EM, Datz FL, Volkman K, Bristow MR. Effects of carvedilol on right ventricular function in chronic heart failure. *Am J Cardiol*. 1998;81:247–250.
305. So PP, Davies RA, Chandy G, Stewart D, Beanlands RS, Haddad H, Pugliese C, Mielniczuk LM. Usefulness of beta-blocker therapy and outcomes in patients with pulmonary arterial hypertension. *Am J Cardiol*. 2012;109:1504–1509. doi: 10.1016/j.amjcard.2012.01.368.
306. Tatli E, Kurum T, Aktöz M, Buyuklu M. Effects of carvedilol on right ventricular ejection fraction and cytokines levels in patients with systolic heart failure. *Int J Cardiol*. 2008;125:273–276. doi: 10.1016/j.ijcard.2007.07.166.
307. Thenappan T, Roy SS, Duval S, Glassner-Kolmin C, Gombert-Maitland M. β -Blocker therapy is not associated with adverse outcomes in patients with pulmonary arterial hypertension: a propensity score analysis. *Circ Heart Fail*. 2014;7:903–910. doi: 10.1161/CIRCHEARTFAILURE.114.001429.
308. Butorov IV, Verbitskii ON, Butorov SI, Paraska VI. Efficacy of losartan treatment of right ventricular cardiac insufficiency in patients with chronic obstructive bronchitis [in Russian]. *Klin Med (Mosk)*. 2003;81:48–51.
309. Hechter SJ, Fredriksen PM, Liu P, Veldtman G, Merchant N, Freeman M, Therrien J, Benson L, Siu S, Webb G. Angiotensin-converting enzyme inhibitors in adults after the Mustard procedure. *Am J Cardiol*. 2001;87:660–663, A11.
310. Kiely DG, Cargill RI, Wheeldon NM, Coutie WJ, Lipworth BJ. Haemodynamic and endocrine effects of type 1 angiotensin II receptor blockade in patients with hypoxaemic cor pulmonale. *Cardiovasc Res*. 1997;33:201–208.
311. Lester SJ, McElhinney DB, Vilorio E, Reddy GP, Ryan E, Tworetzky W, Schiller NB, Foster E. Effects of losartan in patients with a systemically functioning morphologic right ventricle after atrial repair of transposition of the great arteries. *Am J Cardiol*. 2001;88:1314–1316.
312. Rubin LJ, Handel F, Peter RH. The effects of oral hydralazine on right ventricular end-diastolic pressure in patients with right ventricular failure. *Circulation*. 1982;65:1369–1373. doi: 10.1161/01.CIR.65.7.1369.
313. Dore A, Houde C, Chan KL, Ducharme A, Khairy P, Juneau M, Marcotte F, Mercier LA. Angiotensin receptor blockade and exercise capacity in adults with systemic right ventricles: a multicenter, randomized, placebo-controlled clinical trial. *Circulation*. 2005;112:2411–2416. doi: 10.1161/CIRCULATIONAHA.105.543470.
314. Morrell NW, Higham MA, Phillips PG, Shakur BH, Robinson PJ, Beddoes RJ. Pilot study of losartan for pulmonary hypertension in chronic obstructive pulmonary disease. *Respir Res*. 2005;6:88. doi: 10.1186/1465-9921-6-88.
315. Therrien J, Provost Y, Harrison J, Connelly M, Kaemmerer H, Webb GD. Effect of angiotensin receptor blockade on systemic right ventricular function and size: a small, randomized, placebo-controlled study. *Int J Cardiol*. 2008;129:187–192. doi: 10.1016/j.ijcard.2008.04.056.
316. Groves BM, Rubin LJ, Frosolono MF, Cato AE, Reeves JT. A comparison of the acute hemodynamic effects of prostacyclin and hydralazine in primary pulmonary hypertension. *Am Heart J*. 1985;110:1200–1204.
317. McGoon MD, Seward JB, Vlietstra RE, Choo MH, Moyer TP, Reeder GS. Haemodynamic response to intravenous hydralazine in patients with pulmonary hypertension. *Br Heart J*. 1983;50:579–585.
318. Fisher J, Borer JS, Moses JW, Goldberg HL, Niarchos AP, Whitman HH 3rd, Mermelstein M. Hemodynamic effects of nifedipine versus hydralazine in primary pulmonary hypertension. *Am J Cardiol*. 1984;54:646–650.
319. Packer M, Greenberg B, Massie B, Dash H. Deleterious effects of hydralazine in patients with pulmonary hypertension. *N Engl J Med*. 1982;306:1326–1331. doi: 10.1056/NEJM198206033062203.
320. Frapp RH, Gewirtz MH, Werner JC, Whitman V, Rashkind WJ. Oral hydralazine in patients with pulmonary vascular disease secondary to congenital heart disease. *Am J Cardiol*. 1981;48:380–382.
321. Maron BA, Waxman AB, Opatowsky AR, Gillies H, Blair C, Aghamohammadzadeh R, Loscalzo J, Leopold JA. Effectiveness of spironolactone plus ambrisentan for treatment of pulmonary arterial hypertension (from the [ARIES] study 1 and 2 trials). *Am J Cardiol*. 2013;112:720–725. doi: 10.1016/j.amjcard.2013.04.051.
322. Mathur PN, Powles P, Pugsley SO, McEwan MP, Campbell EJ. Effect of digoxin on right ventricular function in severe chronic airflow obstruction: a controlled clinical trial. *Ann Intern Med*. 1981;95:283–288.
323. Rich S, Seiditz M, Dodin E, Osmani D, Judd D, Genthner D, McLaughlin V, Francis G. The short-term effects of digoxin in patients with right ventricular dysfunction from pulmonary hypertension. *Chest*. 1998;114:787–792.
324. Smith DE, Bissett JK, Phillips JR, Doherty JE, Murphy ML. Improved right ventricular systolic time intervals after digitalis in patients with cor pulmonale and chronic obstructive pulmonary disease. *Am J Cardiol*. 1978;41:1299–1304.
325. Brown SE, Pakron FJ, Milne N, Linden GS, Stansbury DW, Fischer CE, Light RW. Effects of digoxin on exercise capacity and right ventricular function during exercise in chronic airflow obstruction. *Chest*. 1984;85:187–191.
326. Alajaji W, Baydoun A, Al-Kindi SG, Henry L, Hanna MA, Oliveira GH. Digoxin therapy for cor pulmonale: a systematic review. *Int J Cardiol*. 2016;223:320–324. doi: 10.1016/j.ijcard.2016.08.018.
327. Skhiri M, Hunt SA, Denault AY, Haddad F. Evidence-based management of right heart failure: a systematic review of an empiric field [in Spanish]. *Rev Esp Cardiol*. 2010;63:451–471.
328. Ghofrani HA, D'Armini AM, Grimminger F, Hoepfer MM, Jansa P, Kim NH, Mayer E, Simonneau G, Wilkins MR, Fritsch A, Neuser D, Weimann G, Wang C; CHEST-1 Study Group. Riociguat for the treatment of chronic thromboembolic pulmonary hypertension. *N Engl J Med*. 2013;369:319–329. doi: 10.1056/NEJMoa1209657.
329. Barst RJ, Rubin LJ, Long WA, McGoon MD, Rich S, Badesch DB, Groves BM, Tapson VF, Bourge RC, Brundage BH, Koerner SK, Langleben D, Keller CA, Murali S, Uretsky BF, Clayton LM, Jöbsis MM, Blackburn SD, Shortino D, Crow JW; Primary Pulmonary Hypertension Study Group. A comparison of continuous intravenous epoprostenol (prostacyclin) with conventional therapy for primary pulmonary hypertension. *N Engl J Med*. 1996;334:296–301. doi: 10.1056/NEJM199602013340504.
330. McLaughlin VV, Genthner DE, Panella MM, Rich S. Reduction in pulmonary vascular resistance with long-term epoprostenol (prostacyclin) therapy in primary pulmonary hypertension. *N Engl J Med*. 1998;338:273–277. doi: 10.1056/NEJM199801293380501.

331. McLaughlin VV, Benza RL, Rubin LJ, Channick RN, Voswinckel R, Tapson VF, Robbins IM, Olschewski H, Rubenfire M, Seeger W. Addition of inhaled treprostinil to oral therapy for pulmonary arterial hypertension: a randomized controlled clinical trial. *J Am Coll Cardiol*. 2010;55:1915–1922. doi: 10.1016/j.jacc.2010.01.027.
332. Skoro-Sajer N, Lang I. The role of treprostinil in the management of pulmonary hypertension. *Am J Cardiovasc Drugs*. 2008;8:213–217.
333. Skoro-Sajer N, Lang I. Treprostinil for the treatment of pulmonary hypertension. *Expert Opin Pharmacother*. 2008;9:1415–1420. doi: 10.1517/14656566.9.8.1415.
334. Channick RN, Voswinckel R, Rubin LJ. Inhaled treprostinil: a therapeutic review. *Drug Des Devel Ther*. 2012;6:19–28. doi: 10.2147/DDDT.S19281.
335. Hooper MM, Schwarze M, Ehlerding S, Adler-Schuermeier A, Spiekerkoetter E, Niedermeyer J, Hamm M, Fabel H. Long-term treatment of primary pulmonary hypertension with aerosolized iloprost, a prostacyclin analogue. *N Engl J Med*. 2000;342:1866–1870. doi: 10.1056/NEJM200006223422503.
336. Olschewski H, Simonneau G, Galiè N, Higenbottam T, Naeije R, Rubin LJ, Nikkho S, Speich R, Hooper MM, Behr J, Winkler J, Sitbon O, Popov W, Ghofrani HA, Manes A, Kiely DG, Ewert R, Meyer A, Corris PA, Delcroix M, Gomez-Sanchez M, Siedentop H, Seeger W; Aerosolized Iloprost Randomized Study Group. Inhaled iloprost for severe pulmonary hypertension. *N Engl J Med*. 2002;347:322–329. doi: 10.1056/NEJMoa020204.
337. Frey MK, Lang I. Tadalafil for the treatment of pulmonary arterial hypertension. *Expert Opin Pharmacother*. 2012;13:747–755. doi: 10.1517/14656566.2012.662220.
338. Galiè N, Barberà JA, Frost AE, Ghofrani HA, Hooper MM, McLaughlin VV, Peacock AJ, Simonneau G, Vachiery JL, Grünig E, Oudiz RJ, Vonk-Noordegraaf A, White RJ, Blair C, Gillies H, Miller KL, Harris JH, Langley J, Rubin LJ; AMBITION Investigators. Initial use of ambrisentan plus tadalafil in pulmonary arterial hypertension. *N Engl J Med*. 2015;373:834–844. doi: 10.1056/NEJMoa1413687.
339. Prasad S, Wilkinson J, Gatzoulis MA. Sildenafil in primary pulmonary hypertension. *N Engl J Med*. 2000;343:1342. doi: 10.1056/NEJM200011023431814.
340. Samaržija M, Zuljević E, Jakopović M, Sever B, Knezević A, Dumija Z, Vidjak V, Samija M. One year efficacy and safety of oral sildenafil treatment in severe pulmonary hypertension. *Coll Antropol*. 2009;33:799–803.
341. Galiè N, Ghofrani HA, Torbicki A, Barst RJ, Rubin LJ, Badesch D, Fleming T, Parpia T, Burgess G, Branzi A, Grimminger F, Kurzya M, Simonneau G; Sildenafil Use in Pulmonary Arterial Hypertension (SUPER) Study Group. Sildenafil citrate therapy for pulmonary arterial hypertension. *N Engl J Med*. 2005;353:2148–2157. doi: 10.1056/NEJMoa050010.
342. Sastry BK, Narasimhan C, Reddy NK, Raju BS. Clinical efficacy of sildenafil in primary pulmonary hypertension: a randomized, placebo-controlled, double-blind, crossover study. *J Am Coll Cardiol*. 2004;43:1149–1153. doi: 10.1016/j.jacc.2003.10.056.
343. De Santo LS, Buonocore M, Agrusta F, Bancone C, Galdieri N, Romano G, Maiello C, Amarelli C. Pattern of resolution of pulmonary hypertension, long-term allograft right ventricular function, and exercise capacity in high-risk heart transplant recipients listed under oral sildenafil. *Clin Transplant*. 2014;28:837–843. doi: 10.1111/ctr.12387.
344. Galiè N, Brundage BH, Ghofrani HA, Oudiz RJ, Simonneau G, Safdar Z, Shapiro S, White RJ, Chan M, Beardsworth A, Frumkin L, Barst RJ; Pulmonary Arterial Hypertension and Response to Tadalafil (PHIRST) Study Group. Tadalafil therapy for pulmonary arterial hypertension. *Circulation*. 2009;119:2894–2903. doi: 10.1161/CIRCULATIONAHA.108.839274.
345. Simonneau G, Rubin LJ, Galiè N, Barst RJ, Fleming TR, Frost AE, Engel PJ, Kramer MR, Burgess G, Collings L, Cossons N, Sitbon O, Badesch DB; PACES Study Group. Addition of sildenafil to long-term intravenous epoprostenol therapy in patients with pulmonary arterial hypertension: a randomized trial. *Ann Intern Med*. 2008;149:521–530.
346. Guazzi M, Vicenzi M, Arena R. Phosphodiesterase 5 inhibition with sildenafil reverses exercise oscillatory breathing in chronic heart failure: a long-term cardiopulmonary exercise testing placebo-controlled study. *Eur J Heart Fail*. 2012;14:82–90. doi: 10.1093/eurjhf/hfr147.
347. Guazzi M, Vicenzi M, Arena R, Guazzi MD. PDE5 inhibition with sildenafil improves left ventricular diastolic function, cardiac geometry, and clinical status in patients with stable systolic heart failure: results of a 1-year, prospective, randomized, placebo-controlled study. *Circ Heart Fail*. 2011;4:8–17. doi: 10.1161/CIRCHEARTFAILURE.110.944694.
348. Lewis GD, Lachmann J, Camuso J, Lepore JJ, Shin J, Martinovic ME, Systrom DM, Bloch KD, Semigran MJ. Sildenafil improves exercise hemodynamics and oxygen uptake in patients with systolic heart failure. *Circulation*. 2007;115:59–66. doi: 10.1161/CIRCULATIONAHA.106.626226.
349. Lewis GD, Shah R, Shahzad K, Camuso JM, Pappagianopoulos PP, Hung J, Tawakol A, Gerszten RE, Systrom DM, Bloch KD, Semigran MJ. Sildenafil improves exercise capacity and quality of life in patients with systolic heart failure and secondary pulmonary hypertension. *Circulation*. 2007;116:1555–1562. doi: 10.1161/CIRCULATIONAHA.107.716373.
350. Redfield MM, Chen HH, Borlaug BA, Semigran MJ, Lee KL, Lewis G, LeWinter MM, Rouleau JL, Bull DA, Mann DL, Deswal A, Stevenson LW, Givertz MM, Ofili EO, O'Connor CM, Felker GM, Goldsmith SR, Bart BA, McNulty SE, Ibarra JC, Lin G, Oh JK, Patel MR, Kim RJ, Tracy RP, Velazquez EJ, Anstrom KJ, Hernandez AF, Mascette AM, Braunwald E; RELAX Trial. Effect of phosphodiesterase-5 inhibition on exercise capacity and clinical status in heart failure with preserved ejection fraction: a randomized clinical trial. *JAMA*. 2013;309:1268–1277. doi: 10.1001/jama.2013.2024.
351. Channick RN, Simonneau G, Sitbon O, Robbins IM, Frost A, Tapson VF, Badesch DB, Roux S, Rainisio M, Bodin F, Rubin LJ. Effects of the dual endothelin-receptor antagonist bosentan in patients with pulmonary hypertension: a randomised placebo-controlled study. *Lancet*. 2001;358:1119–1123. doi: 10.1016/S0140-6736(01)06250-X.
352. Galiè N, Badesch D, Oudiz R, Simonneau G, McGoon MD, Keogh AM, Frost AE, Zwicke D, Naeije R, Shapiro S, Olschewski H, Rubin LJ. Ambrisentan therapy for pulmonary arterial hypertension. *J Am Coll Cardiol*. 2005;46:529–535. doi: 10.1016/j.jacc.2005.04.050.
353. Galiè N, Olschewski H, Oudiz RJ, Torres F, Frost A, Ghofrani HA, Badesch DB, McGoon MD, McLaughlin VV, Roecker EB, Gerber MJ, Dufton C, Wiens BL, Rubin LJ; Ambrisentan in Pulmonary Arterial Hypertension, Randomized, Double-Blind, Placebo-Controlled, Multicenter, Efficacy Studies (ARIES) Group. Ambrisentan for the treatment of pulmonary arterial hypertension: results of the Ambrisentan in Pulmonary Arterial Hypertension, Randomized, Double-Blind, Placebo-Controlled, Multicenter, Efficacy (ARIES) study 1 and 2. *Circulation*. 2008;117:3010–3019. doi: 10.1161/CIRCULATIONAHA.107.742510.
354. Galiè N, Rubin LJ, Hooper M, Jansa P, Al-Hiti H, Meyer G, Chiossi E, Kusic-Pajic A, Simonneau G. Treatment of patients with mildly symptomatic pulmonary arterial hypertension with bosentan (EARLY study): a double-blind, randomised controlled trial. *Lancet*. 2008;371:2093–2100. doi: 10.1016/S0140-6736(08)60919-8.
355. McGoon MD, Frost AE, Oudiz RJ, Badesch DB, Galiè N, Olschewski H, McLaughlin VV, Gerber MJ, Dufton C, Despain DJ, Rubin LJ. Ambrisentan therapy in patients with pulmonary arterial hypertension who discontinued bosentan or sitaxsentan due to liver function test abnormalities. *Chest*. 2009;135:122–129. doi: 10.1378/chest.08-1028.
356. Pulido T, Adzerikho I, Channick RN, Delcroix M, Galiè N, Ghofrani HA, Jansa P, Jing ZC, Le Brun FO, Mehta S, Mittelholzer CM, Perchenet L, Sastry BK, Sitbon O, Souza R, Torbicki A, Zeng X, Rubin LJ, Simonneau G; SERAPHIN Investigators. Macitentan and morbidity and mortality in pulmonary arterial hypertension. *N Engl J Med*. 2013;369:809–818. doi: 10.1056/NEJMoa1213917.
357. Rubin LJ, Badesch DB, Barst RJ, Galiè N, Black CM, Keogh A, Pulido T, Frost A, Roux S, Leconte I, Landzberg M, Simonneau G. Bosentan therapy for pulmonary arterial hypertension. *N Engl J Med*. 2002;346:896–903. doi: 10.1056/NEJMoa012212.
358. Lüscher TF, Enseleit F, Pacher R, Mitrovic V, Schulze MR, Willenbrock R, Dietz R, Rousson V, Hürlimann D, Philipp S, Notter T, Noll G, Ruschitzka F; Heart Failure ET(A) Receptor Blockade Trial. Hemodynamic and neurohumoral effects of selective endothelin A (ET(A)) receptor blockade in chronic heart failure: the Heart Failure ET(A) Receptor Blockade Trial (HEAT). *Circulation*. 2002;106:2666–2672. doi: 10.1161/01.CIR.0000038497.80095.E1.
359. Torre-Amione G, Young JB, Durand J, Bozkurt B, Mann DL, Kobrin I, Pratt CM. Hemodynamic effects of tezosentan, an intravenous dual endothelin receptor antagonist, in patients with class III to IV congestive heart failure. *Circulation*. 2001;103:973–980. doi: 10.1161/01.CIR.103.7.973.
360. Kelland NF, Webb DJ. Clinical trials of endothelin antagonists in heart failure: publication is good for the public health. *Heart*. 2007;93:2–4. doi: 10.1136/hrt.2006.089250.
361. McMurray JJ, Teerlink JR, Cotter G, Bourge RC, Cleland JG, Jondeau G, Krum H, Metra M, O'Connor CM, Parker JD, Torre-Amione G, van Veldhuisen DJ, Lewsey J, Frey A, Rainisio M, Kobrin I; VERITAS Investigators. Effects of tezosentan on symptoms and clinical outcomes

- in patients with acute heart failure: the VERITAS randomized controlled trials. *JAMA*. 2007;298:2009–2019. doi: 10.1001/jama.298.17.2009.
362. Book WM, Shaddy RE. Medical therapy in adults with congenital heart disease. *Heart Fail Clin*. 2014;10:167–178. doi: 10.1016/j.hfc.2013.09.006.
 363. Warnes CA, Williams RG, Bashore TM, Child JS, Connolly HM, Dearani JA, del Nido P, Fasules JW, Graham TP Jr, Hijazi ZM, Hunt SA, King ME, Landzberg MJ, Miner PD, Radford MJ, Walsh EP, Webb GD. ACC/AHA 2008 guidelines for the management of adults with congenital heart disease: a report of the American College of Cardiology/American Heart Association Task Force on Practice Guidelines (Writing Committee to Develop Guidelines on the Management of Adults With Congenital Heart Disease). *Circulation*. 2008;118:e714–e833. doi: 10.1161/CIRCULATIONAHA.108.190690.
 364. Bhatt AB, Foster E, Kuehl K, Alpert J, Brabeck S, Crumb S, Davidson WR Jr, Earing MG, Ghoshhajra BB, Karamlou T, Mital S, Ting J, Tseng ZH; on behalf of the American Heart Association Council on Clinical Cardiology. Congenital heart disease in the older adult: a scientific statement from the American Heart Association. *Circulation*. 2015;131:1884–1931. doi: 10.1161/CIR.0000000000000204.
 365. Presbitero P, Somerville J, Rabajoli F, Stone S, Conte MR. Corrected transposition of the great arteries without associated defects in adult patients: clinical profile and follow up. *Br Heart J*. 1995;74:57–59.
 366. Acar P, Sidi D, Bonnet D, Aggoun Y, Bonhoeffer P, Kachaner J. Maintaining tricuspid valve competence in double discordance: a challenge for the paediatric cardiologist. *Heart*. 1998;80:479–483.
 367. van Son JA, Danielson GK, Huhta JC, Warnes CA, Edwards WD, Schaff HV, Puga FJ, Ilstrup DM. Late results of systemic atrioventricular valve replacement in corrected transposition. *J Thorac Cardiovasc Surg*. 1995;109:642–652.
 368. Scherptong RW, Vliegen HW, Winter MM, Holman ER, Mulder BJ, van der Wall EE, Hazekamp MG. Tricuspid valve surgery in adults with a dysfunctional systemic right ventricle: repair or replace? *Circulation*. 2009;119:1467–1472. doi: 10.1161/CIRCULATIONAHA.108.805135.
 369. Janousek J, Tomek V, Chaloupecký VA, Reich O, Gebauer RA, Kautzner J, Hucin B. Cardiac resynchronization therapy: a novel adjunct to the treatment and prevention of systemic right ventricular failure. *J Am Coll Cardiol*. 2004;44:1927–1931. doi: 10.1016/j.jacc.2004.08.044.
 370. Diller GP, Okonko D, Uebing A, Ho SY, Gatzoulis MA. Cardiac resynchronization therapy for adult congenital heart disease patients with a systemic right ventricle: analysis of feasibility and review of early experience. *Europace*. 2006;8:267–272. doi: 10.1093/europace/euj048.
 371. Dubin AM, Janousek J, Rhee E, Strieper MJ, Cecchin F, Law IH, Shannon KM, Temple J, Rosenthal E, Zimmerman FJ, Davis A, Karpawich PP, Al Ahmad A, Vetter VL, Kertesz NJ, Shah M, Snyder C, Stephenson E, Emmel M, Sanatani S, Kanter R, Batra A, Collins KK. Resynchronization therapy in pediatric and congenital heart disease patients: an international multicenter study. *J Am Coll Cardiol*. 2005;46:2277–2283. doi: 10.1016/j.jacc.2005.05.096.
 372. Lindenfeld J, Keller K, Campbell DN, Wolfe RR, Quaife RA. Improved systemic ventricular function after carvedilol administration in a patient with congenitally corrected transposition of the great arteries. *J Heart Lung Transplant*. 2003;22:198–201.
 373. Josephson CB, Howlett JG, Jackson SD, Finley J, Kells CM. A case series of systemic right ventricular dysfunction post atrial switch for simple D-transposition of the great arteries: the impact of beta-blockade. *Can J Cardiol*. 2006;22:769–772.
 374. Shaddy RE, Boucek MM, Hsu DT, Boucek RJ, Canter CE, Mahony L, Ross RD, Pahl E, Blume ED, Dodd DA, Rosenthal DN, Burr J, LaSalle B, Holubkov R, Lukas MA, Tani LY. Carvedilol for children and adolescents with heart failure: a randomized controlled trial. *JAMA*. 2007;298:1171–1179.
 375. Alabed S, Sabouni A, Al Dakhou S, Bdaiwi Y, Frobel-Mercier AK. Beta-blockers for congestive heart failure in children. *Cochrane Database Syst Rev*. 2016;CD007037.
 376. van der Bom T, Winter MM, Bouma BJ, Groenink M, Vliegen HW, Pieper PG, van Dijk AP, Sieswerda GT, Roos-Hesselink JW, Zwinderman AH, Mulder BJ. Effect of valsartan on systemic right ventricular function: a double-blind, randomized, placebo-controlled pilot trial. *Circulation*. 2013;127:322–330. doi: 10.1161/CIRCULATIONAHA.112.135392.
 377. Robinson B, Heise CT, Moore JW, Anella J, Sokoloski M, Eshaghpour E. Afterload reduction therapy in patients following intraatrial baffle operation for transposition of the great arteries. *Pediatr Cardiol*. 2002;23:618–623. doi: 10.1007/s00246-002-0046-2.
 378. Dos L, Pujadas S, Estruch M, Mas A, Ferreira-González I, Pijuan A, Serra R, Ordóñez-Llanos J, Subirana M, Pons-Lladó G, Marsal JR, García-Dorado D, Casaldàliga J. Eplerenone in systemic right ventricle: double blind randomized clinical trial: the EVEDES study. *Int J Cardiol*. 2013;168:5167–5173. doi: 10.1016/j.ijcard.2013.07.163.
 379. Gentles TL, Mayer JE Jr, Gauvreau K, Newburger JW, Lock JE, Kupferschmid JP, Burnett J, Jonas RA, Castañeda AR, Wernovsky G. Fontan operation in five hundred consecutive patients: factors influencing early and late outcome. *J Thorac Cardiovasc Surg*. 1997;114:376–391.
 380. Hsu DT, Zak V, Mahony L, Sleeper LA, Atz AM, Levine JC, Barker PC, Ravishanker C, McCrindle BW, Williams RV, Altmann K, Ghanayem NS, Margossian R, Chung WK, Border WL, Pearson GD, Stylianou MP, Mital S; Pediatric Heart Network Investigators. Enalapril in infants with single ventricle: results of a multicenter randomized trial. *Circulation*. 2010;122:333–340. doi: 10.1161/CIRCULATIONAHA.109.927988.
 381. Kouatli AA, Garcia JA, Zellers TM, Weinstein EM, Mahony L. Enalapril does not enhance exercise capacity in patients after Fontan procedure. *Circulation*. 1997;96:1507–1512.
 382. Goldberg DJ, French B, McBride MG, Marino BS, Mirarchi N, Hanna BD, Wernovsky G, Paridon SM, Rychik J. Impact of oral sildenafil on exercise performance in children and young adults after the Fontan operation: a randomized, double-blind, placebo-controlled, crossover trial. *Circulation*. 2011;123:1185–1193. doi: 10.1161/CIRCULATIONAHA.110.981746.
 383. Grattan MJ, McCrindle BW. Recurrent exacerbations of protein-losing enteropathy after initiation of growth hormone therapy in a Fontan patient controlled with spironolactone. *Congenit Heart Dis*. 2010;5:165–167. doi: 10.1111/j.1747-0803.2009.00320.x.
 384. Ringel RE, Peddy SB. Effect of high-dose spironolactone on protein-losing enteropathy in patients with Fontan palliation of complex congenital heart disease. *Am J Cardiol*. 2003;91:1031–1032, A9.
 385. Mahle WT, Wang A, Quyyumi AA, McConnell ME, Book WM. Impact of spironolactone on endothelial function in patients with single ventricle heart. *Congenit Heart Dis*. 2009;4:12–16. doi: 10.1111/j.1747-0803.2008.00240.x.
 386. Norozi K, Buchhorn R, Wessel A, Bahlmann J, Raab B, Geyer S, Kuehne T, Beibei L, Werdan K, Loppnow H. Beta-blockade does not alter plasma cytokine concentrations and ventricular function in young adults with right ventricular dysfunction secondary to operated congenital heart disease. *Circ J*. 2008;72:747–752.
 387. Babu-Narayan SV, Uebing A, Davlouros PA, Kemp M, Davidson S, Dimopoulos K, Bayne S, Pennell DJ, Gibson DG, Flather M, Kilner PJ, Li W, Gatzoulis MA. Randomised trial of ramipril in repaired tetralogy of Fallot and pulmonary regurgitation: the APPROPRIATE study (Ace inhibitors for Potential PREvention Of the deleterious effects of Pulmonary Regurgitation In Adults with repaired Tetralogy of Fallot). *Int J Cardiol*. 2012;154:299–305. doi: 10.1016/j.ijcard.2010.09.057.
 388. Feinstein JA, Benson DW, Dubin AM, Cohen MS, Maxey DM, Mahle WT, Pahl E, Villafañe J, Bhatt AB, Peng LF, Johnson BA, Marsden AL, Daniels CJ, Ruddy NA, Caldarone CA, Mussatto KA, Morales DL, Ivy DD, Gaynor JW, Tweddell JS, Deal BJ, Furck AK, Rosenthal GL, Ohye RG, Ghanayem NS, Cheatham JP, Tworetzky W, Martin GR. Hypoplastic left heart syndrome: current considerations and expectations. *J Am Coll Cardiol*. 2012;59(suppl):S1–S42. doi: 10.1016/j.jacc.2011.09.022.
 389. Rossano JW, Shaddy RE. Update on pharmacological heart failure therapies in children: do adult medications work in children and if not, why not? *Circulation*. 2014;129:607–612. doi: 10.1161/CIRCULATIONAHA.113.003615.
 390. Cheung AW, White CW, Davis MK, Freed DH. Short-term mechanical circulatory support for recovery from acute right ventricular failure: clinical outcomes. *J Heart Lung Transplant*. 2014;33:794–799. doi: 10.1016/j.healun.2014.02.028.
 391. Morgan JA, John R, Lee BJ, Oz MC, Naka Y. Is severe right ventricular failure in left ventricular assist device recipients a risk factor for unsuccessful bridging to transplant and post-transplant mortality. *Ann Thorac Surg*. 2004;77:859–863. doi: 10.1016/j.athoracsurg.2003.09.048.
 392. John R, Long JW, Massey HT, Griffith BP, Sun BC, Tector AJ, Frazier OH, Joyce LD. Outcomes of a multicenter trial of the Levitronix CentriMag ventricular assist system for short-term circulatory support. *J Thorac Cardiovasc Surg*. 2011;141:932–939. doi: 10.1016/j.jtcvs.2010.03.046.
 393. Verbelen T, Verhoeven J, Goda M, Burkhoff D, Delcroix M, Rega F, Meyns B. Mechanical support of the pressure overloaded right ventricle: an acute feasibility study comparing low and high flow support. *Am J Physiol Heart Circ Physiol*. 2015;309:H615–H624. doi: 10.1152/ajpheart.00246.2015.

394. Anderson MB, Goldstein J, Milano C, Morris LD, Kormos RL, Bhama J, Kapur NK, Bansal A, Garcia J, Baker JN, Silvestry S, Holman WL, Douglas PS, O'Neill W. Benefits of a novel percutaneous ventricular assist device for right heart failure: the prospective RECOVER RIGHT study of the Impella RP device. *J Heart Lung Transplant*. 2015;34:1549–1560. doi: 10.1016/j.healun.2015.08.018.
395. Kar B, Adkins LE, Civitello AB, Loyalka P, Palanichamy N, Gemmato CJ, Myers TJ, Gregoric ID, Delgado RM 3rd. Clinical experience with the TandemHeart percutaneous ventricular assist device. *Tex Heart Inst J*. 2006;33:111–115.
396. Kapur NK, Paruchuri V, Korabathina R, Al-Mohammadi R, Mudd JO, Prutkin J, Esposito M, Shah A, Kiernan MS, Sech C, Pham DT, Konstam MA, Denofrio D. Effects of a percutaneous mechanical circulatory support device for medically refractory right ventricular failure. *J Heart Lung Transplant*. 2011;30:1360–1367. doi: 10.1016/j.healun.2011.07.005.
397. Kiernan MS, Krishnamurthy B, Kapur NK. Percutaneous right ventricular assist via the internal jugular vein in cardiogenic shock complicating an acute inferior myocardial infarction. *J Invasive Cardiol*. 2010;22:E23–E26.
398. Aggarwal V, Einhorn BN, Cohen HA. Current status of percutaneous right ventricular assist devices: first-in-man use of a novel dual lumen cannula. *Catheter Cardiovasc Interv*. 2016;88:390–396. doi: 10.1002/ccd.26348.
399. Aghili N, Bader Y, Vest AR, Kiernan MS, Kimmelstiel C, DeNofrio D, Kapur NK. Biventricular circulatory support using 2 axial flow catheters for cardiogenic shock without the need for surgical vascular access. *Circ Cardiovasc Interv*. 2016;9:e003636.
400. Kapur NK, Jumean M, Ghuloom A, Aghili N, Vassallo C, Kiernan MS, DeNofrio D, Pham DT. First successful use of 2 axial flow catheters for percutaneous biventricular circulatory support as a bridge to a durable left ventricular assist device. *Circ Heart Fail*. 2015;8:1006–1008. doi: 10.1161/CIRCHEARTFAILURE.115.002374.
401. Makdisi G, Wang IW. Extra corporeal membrane oxygenation (ECMO): review of a lifesaving technology. *J Thorac Dis*. 2015;7:E166–E176. doi: 10.3978/j.issn.2072-1439.2015.07.17.
402. Stretch R, Sauer CM, Yuh DD, Bonde P. National trends in the utilization of short-term mechanical circulatory support: incidence, outcomes, and cost analysis. *J Am Coll Cardiol*. 2014;64:1407–1415. doi: 10.1016/j.jacc.2014.07.958.
403. Smedira NG, Blackstone EH. Postcardiotomy mechanical support: risk factors and outcomes. *Ann Thorac Surg*. 2001;71(suppl):S60–S66.
404. Dang NC, Topkara VK, Mercado M, Kay J, Kruger KH, Aboodi MS, Oz MC, Naka Y. Right heart failure after left ventricular assist device implantation in patients with chronic congestive heart failure. *J Heart Lung Transplant*. 2006;25:1–6. doi: 10.1016/j.healun.2005.07.008.
405. Kaul TK, Fields BL. Postoperative acute refractory right ventricular failure: incidence, pathogenesis, management and prognosis. *Cardiovasc Surg*. 2000;8:1–9.
406. Bhama JK, Kormos RL, Toyoda Y, Teuteberg JJ, McCurry KR, Siegenthaler MP. Clinical experience using the Levitronix CentriMag system for temporary right ventricular mechanical circulatory support. *J Heart Lung Transplant*. 2009;28:971–976. doi: 10.1016/j.healun.2009.04.015.
407. Bernhardt AM, De By TM, Reichenspurner H, Deuse T. Isolated permanent right ventricular assist device implantation with the HeartWare continuous-flow ventricular assist device: first results from the European Registry for Patients with Mechanical Circulatory Support. *Eur J Cardiothorac Surg*. 2015;48:158–162. doi: 10.1093/ejcts/ezu406.
408. Cook JA, Shah KB, Quader MA, Cooke RH, Kasirajan V, Rao KK, Smallfield MC, Tchoukina I, Tang DG. The total artificial heart. *J Thorac Dis*. 2015;7:2172–2180. doi: 10.3978/j.issn.2072-1439.2015.10.70.
409. Copeland JG, Smith RG, Arabia FA, Nolan PE, Sethi GK, Tsau PH, McClellan D, Slepian MJ; CardioWest Total Artificial Heart Investigators. Cardiac replacement with a total artificial heart as a bridge to transplantation. *N Engl J Med*. 2004;351:859–867. doi: 10.1056/NEJMoa040186.
410. Lund LH, Edwards LB, Kucheryavaya AY, Benden C, Dipchand AI, Goldfarb S, Levvey BJ, Meiser B, Rossano JW, Yusen RD, Stehlik J. The Registry of the International Society for Heart and Lung Transplantation: thirty-second official adult heart transplantation report—2015; focus theme: early graft failure. *J Heart Lung Transplant*. 2015;34:1244–1254. doi: 10.1016/j.healun.2015.08.003.
411. Yusen RD, Edwards LB, Kucheryavaya AY, Benden C, Dipchand AI, Goldfarb SB, Levvey BJ, Lund LH, Meiser B, Rossano JW, Stehlik J. The Registry of the International Society for Heart and Lung Transplantation: thirty-second official adult lung and heart-lung transplantation report—2015; focus theme: early graft failure. *J Heart Lung Transplant*. 2015;34:1264–1277. doi: 10.1016/j.healun.2015.08.014.
412. Colvin M, Smith JM, Skeans MA, Edwards LB, Uccellini K, Snyder JJ, Israni AK, Kasiske BL. OPTN/SRTR 2015 annual data report: heart. *Am J Transplant*. 2017;17(suppl 1):286–356.
413. Sandoval J, Gaspar J, Pulido T, Bautista E, Martínez-Guerra ML, Zeballos M, Palomar A, Gómez A. Graded balloon dilation atrial septostomy in severe primary pulmonary hypertension: a therapeutic alternative for patients non-responsive to vasodilator treatment. *J Am Coll Cardiol*. 1998;32:297–304.
414. Esch JJ, Shah PB, Cockrill BA, Farber HW, Landzberg MJ, Mehra MR, Mullen MP, Opatowsky AR, Waxman AB, Lock JE, Marshall AC. Transcatheter Potts shunt creation in patients with severe pulmonary arterial hypertension: initial clinical experience. *J Heart Lung Transplant*. 2013;32:381–387. doi: 10.1016/j.healun.2013.01.1049.
415. Nishimura RA, Otto CM, Bonow RO, Carabello BA, Erwin JP 3rd, Guyton RA, O'Gara PT, Ruiz CE, Skubas NJ, Sorajja P, Sundt TM 3rd, Thomas JD. 2014 AHA/ACC guideline for the management of patients with valvular heart disease: a report of the American College of Cardiology/American Heart Association Task Force on Practice Guidelines [published corrections appear in *Circulation*. 2014;129:e651 and *Circulation*. 2014;130:e120]. *Circulation*. 2014;129:e521–e643. doi: 10.1161/CIR.0000000000000031.
416. Topilsky Y, Nkomo VT, Vatury O, Michelen H, Letourneau T, Suri RM, Pislaru S, Park S, Mahoney DW, Biner S, Enriquez-Sarano M. Clinical outcome of isolated tricuspid regurgitation. *JACC Cardiovasc Imaging*. 2014;7:1185–1194. doi: 10.1016/j.jcmg.2014.07.018.
417. Kim YJ, Kwon DA, Kim HK, Park JS, Hahn S, Kim KH, Kim KB, Sohn DW, Ahn H, Oh BH, Park YB. Determinants of surgical outcome in patients with isolated tricuspid regurgitation. *Circulation*. 2009;120:1672–1678. doi: 10.1161/CIRCULATIONAHA.109.849448.
418. Lin G, Nishimura RA, Connolly HM, Dearani JA, Sundt TM 3rd, Hayes DL. Severe symptomatic tricuspid valve regurgitation due to permanent pacemaker or implantable cardioverter-defibrillator leads. *J Am Coll Cardiol*. 2005;45:1672–1675. doi: 10.1016/j.jacc.2005.02.037.
419. Fukuda S, Gillinov AM, McCarthy PM, Stewart WJ, Song JM, Kihara T, Daimon M, Shin MS, Thomas JD, Shiota T. Determinants of recurrent or residual functional tricuspid regurgitation after tricuspid annuloplasty. *Circulation*. 2006;114(suppl):I582–I587. doi: 10.1161/CIRCULATIONAHA.105.001305.
420. Singh SK, Tang GH, Maganti MD, Armstrong S, Williams WG, David TE, Borger MA. Midterm outcomes of tricuspid valve repair versus replacement for organic tricuspid disease. *Ann Thorac Surg*. 2006;82:1735–1741. doi: 10.1016/j.athoracur.2006.06.016.
421. McCarthy PM, Bhudia SK, Rajeswaran J, Hoercher KJ, Lytle BW, Cosgrove DM, Blackstone EH. Tricuspid valve repair: durability and risk factors for failure. *J Thorac Cardiovasc Surg*. 2004;127:674–685. doi: 10.1016/j.jtcvs.2003.11.019.
422. Dreyfus GD, Martin RP, Chan KM, Dulguerov F, Alexandrescu C. Functional tricuspid regurgitation: a need to revise our understanding. *J Am Coll Cardiol*. 2015;65:2331–2336. doi: 10.1016/j.jacc.2015.04.011.
423. John R, Naka Y, Park SJ, Sai-Sudhakar C, Salerno C, Sundareswaran KS, Farrar DJ, Milano CA. Impact of concurrent surgical valve procedures in patients receiving continuous-flow devices. *J Thorac Cardiovasc Surg*. 2014;147:581–589. doi: 10.1016/j.jtcvs.2013.10.024.
424. Robertson JO, Grau-Sepulveda MV, Okada S, O'Brien SM, Matthew Brennan J, Shah AS, Itoh A, Damiano RJ, Prasad S, Silvestry SC. Concomitant tricuspid valve surgery during implantation of continuous-flow left ventricular assist devices: a Society of Thoracic Surgeons database analysis. *J Heart Lung Transplant*. 2014;33:609–617. doi: 10.1016/j.healun.2014.01.861.
425. Piacentino V 3rd, Ganapathi AM, Stafford-Smith M, Hsieh MK, Patel CB, Simeone AA, Rogers JG, Milano CA. Utility of concomitant tricuspid valve procedures for patients undergoing implantation of a continuous-flow left ventricular device. *J Thorac Cardiovasc Surg*. 2012;144:1217–1221. doi: 10.1016/j.jtcvs.2012.07.064.
426. Hoof van Huysduynen B, Henkens IR, Swenne CA, Oosterhof T, Draisma HH, Maan AC, Hazekamp MG, de Roos A, Schali MJ, van der Wall EE, Vliegen HW. Pulmonary valve replacement in tetralogy of Fallot improves the repolarization. *Int J Cardiol*. 2008;124:301–306. doi: 10.1016/j.ijcard.2007.02.006.
427. Oosterhof T, van Straten A, Vliegen HW, Meijboom FJ, van Dijk AP, Spijkerboer AM, Bouma BJ, Zwinderman AH, Hazekamp MG, de Roos A, Mulder BJ. Preoperative thresholds for pulmonary valve replacement in patients with corrected tetralogy of Fallot using cardiovascular magnetic resonance. *Circulation*. 2007;116:545–551. doi: 10.1161/CIRCULATIONAHA.106.659664.
428. Jones TK, Rome JJ, Armstrong AK, Berger F, Hellenbrand WE, Cabalka AK, Benson LN, Balzer DT, Cheatham JP, Eicken A, McElhinney DB. Transcatheter pulmonary valve replacement reduces tricuspid regurgitation in patients with right ventricular volume/pressure overload. *J Am Coll Cardiol*. 2016;68:1525–1535. doi: 10.1016/j.jacc.2016.07.734.