

STRUCTURAL

Transcatheter Laceration of Aortic Leaflets to Prevent Coronary Obstruction During Transcatheter Aortic Valve Replacement

Concept to First-in-Human



Jaffar M. Khan, BM BCh,^a Danny Dvir, MD,^b Adam B. Greenbaum, MD,^c Vasilis C. Babaliaros, MD,^d Toby Rogers, PhD, BM BCh,^a Gabriel Aldea, MD,^b Mark Reisman, MD,^b G. Burkhard Mackensen, MD,^b Marvin H.K. Eng, MD,^c Gaetano Paone, MD,^c Dee Dee Wang, MD,^c Robert A. Guyton, MD,^d Chandan M. Devireddy, MD,^d William H. Schenke, BS,^a Robert J. Lederman, MD^a

ABSTRACT

OBJECTIVES This study sought to develop a novel technique called bioprosthetic or native aortic scallop intentional laceration to prevent coronary artery obstruction (BASILICA).

BACKGROUND Coronary artery obstruction is a rare but fatal complication of transcatheter aortic valve replacement (TAVR).

METHODS We lacerated pericardial leaflets in vitro using catheter electrosurgery, and tested leaflet splaying after benchtop TAVR. The procedure was tested in swine. BASILICA was then offered to patients at high risk of coronary obstruction from TAVR and ineligible for surgical aortic valve replacement. BASILICA used marketed devices. Catheters directed an electrified guidewire to traverse and lacerate the aortic leaflet down the center line. TAVR was performed as usual.

RESULTS TAVR splayed lacerated bovine pericardial leaflets. BASILICA was successful in pigs, both to left and right cusps. Necropsy revealed full length lacerations with no collateral thermal injury. Seven patients underwent BASILICA on a compassionate basis. Six had failed bioprosthetic valves, both stented and stent-less. Two had severe aortic stenosis, including 1 patient with native disease, 3 had severe aortic regurgitation, and 2 had mixed aortic valve disease. One patient required laceration of both left and right coronary cusps. There was no hemodynamic compromise in any patient following BASILICA. All patients had successful TAVR, with no coronary obstruction, stroke, or any major complications. All patients survived to 30 days.

CONCLUSIONS BASILICA may durably prevent coronary obstruction from TAVR. The procedure was successful across a range of presentations, and requires further evaluation in a prospective trial. Its role in treatment of degenerated TAVR devices remains untested. (J Am Coll Cardiol Intv 2018;11:677-89) Published by Elsevier on behalf of the American College of Cardiology Foundation.

From the ^aCardiovascular Branch, Division of Intramural Research, National Heart, Lung, and Blood Institute, National Institutes of Health, Bethesda, Maryland; ^bUniversity of Washington, Seattle, Washington; ^cCenter for Structural Heart Disease, Division of Cardiology, and Division of Cardiac Surgery, Henry Ford Health System, Detroit, Michigan; and the ^dStructural Heart and Valve Center, Emory University Hospital, Atlanta, Georgia. Supported by the National Heart, Lung, and Blood Institute, National Institutes of Health (Z01-HL006040-7), and by the intramural programs of the participating centers. National Heart, Lung, and Blood Institute has a collaborative research and development agreement with Edwards Lifesciences on transcatheter modification

ABBREVIATIONS AND ACRONYMS

BASILICA = bioprosthetic or native aortic scallop intentional laceration to prevent iatrogenic coronary artery obstruction

CT = computed tomography

TAVR = transcatheter aortic valve replacement

Transcatheter aortic valve replacement (TAVR) is an effective alternative to surgical aortic valve replacement in intermediate- and high-risk patients with native aortic stenosis (1,2). TAVR is also an effective treatment for failure of bioprosthetic surgical aortic valves, a treatment known as valve-in-valve TAVR (3,4). Coronary artery obstruction is a devastating complication of TAVR, with a >50% mortality (5). Coronary artery obstruction occurs when the transcatheter heart valve displaces the underlying surgical or native aortic valve leaflets outward and obstructs the coronary artery ostia, either by sealing the sinus of Valsalva at the sinotubular junction or by the leaflet itself covering the coronary ostia because of low-lying coronary ostia and inadequate sinus width (Figure 1). Coronary artery obstruction is 4 times as common during valve-in-valve TAVR as during TAVR for native aortic stenosis (6),

SEE PAGE 690

likely because most surgical prostheses are supra-annular in design, lowering coronary heights relative to the valve leaflets, and because valve suturing draws the coronaries closer, decreasing sinus width. The risk of coronary obstruction is highest during TAVR for surgical bioprosthesis designs intended to maximize effective aortic orifice area (“stented” bioprostheses that have externally mounted leaflets, and “stent-less” surgical bioprostheses) (5). Treatment requires bail-out percutaneous coronary intervention, which may not be possible with a valve leaflet obstructing the coronary artery, or emergency bypass surgery. Pre-emptive coronary protection with a guidewire, with or without a coronary balloon or stent prepositioned down the coronary artery, is variably successful (7,8) in the short and intermediate term. One-third of coronary obstruction events may manifest after the TAVR is concluded (5).

We propose a solution based on the LAMPOON procedure (9,10), which uses catheters to split the

mitral valve leaflet and prevent obstruction of the left ventricular outflow tract during transcatheter mitral valve replacement. Here we report a technique to split aortic valve leaflets, whether bioprosthetic or native, to prevent coronary artery obstruction after TAVR. The new technique is called bioprosthetic or native aortic scallop intentional laceration to prevent coronary artery obstruction (BASILICA).

We developed the technique in vitro and in animals, and then offered the procedure to patients experiencing aortic valve failure who were ineligible for conventional surgical aortic valve replacement, and high or prohibitive risk of coronary artery obstruction from TAVR.

METHODS

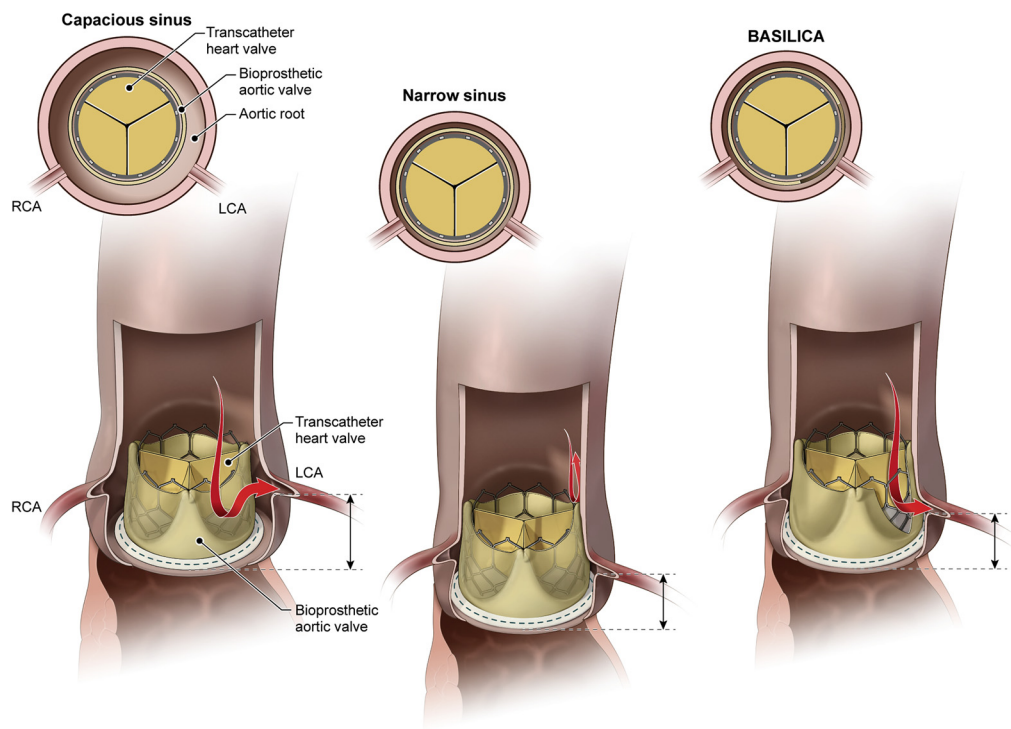
We set out to demonstrate several key technical principles. First, that an aortic leaflet scallop can be traversed in situ by an electrified guidewire between the sinus of Valsalva and the left ventricular outflow tract. Second, that the traversed leaflet, whether native or bioprosthetic, can be lacerated in situ by the mid-shaft of an electrified guidewire. Third, that the lacerated leaflets splay after TAVR to allow blood flow across them toward otherwise obstructed coronary ostia. Fourth, whether partial (mid-scallop vs. basal leaflet) lacerations extend lengthwise when stretched by an implanted valve, which may influence the required spatial precision of the procedure. Fifth, that both left and right coronary cusps can be lacerated simultaneously in vivo.

IN VITRO. We tested radiofrequency-assisted transcatheter perforation and laceration of exterior-mounted bovine pericardial leaflets on a representative bioprosthetic heart valve (19-mm Trifecta valve, Abbott St. Jude Medical, St. Paul, Minnesota) submerged in a 0.9% saline bath with a remote dispersive electrode (Online Figure 1). Two lacerations were attempted on the bioprosthetic heart valve. One leaflet was lacerated from base to tip and the second from

of the mitral valve. Dr. Dvir is a consultant for Edwards Lifesciences, Medtronic, and St. Jude Medical. Dr. Greenbaum is a proctor for Edwards Lifesciences and Abbott St. Jude Medical. Dr. Babaliaros is a consultant for Edwards Lifesciences and Abbott Vascular; and his employer has research contracts for clinical investigation of transcatheter aortic and mitral devices from Edwards Lifesciences, Abbott Vascular, Medtronic, St. Jude Medical, and Boston Scientific. Dr. Eng is a proctor for Edwards Lifesciences. Dr. Paone is a proctor for Edwards Lifesciences. Dr. Wang is a consultant for Edwards Lifesciences. Dr. Guyton's employer has research contracts for clinical investigation of aortic and mitral devices from Edwards Lifesciences, Abbott Vascular, Medtronic, and Boston Scientific. Dr. Devireddy is a consultant for Medtronic; and his employer has research contracts for clinical investigation of transcatheter aortic and mitral devices from Edwards Lifesciences, Abbott Vascular, Medtronic, St. Jude Medical, and Boston Scientific. All other authors have reported that they have no relationships relevant to the contents of this paper to disclose. Drs. Khan and Dvir contributed equally to this work.

Manuscript received October 20, 2017; revised manuscript received December 19, 2017, accepted January 1, 2018.

FIGURE 1 Illustrations of Coronary Obstruction and Prevention by BASILICA



In normal transcatheter aortic valve replacement performed in a capacious aortic root, blood flows unrestricted around valve leaflets into coronary arteries. In patients with a crowded sinus and low-lying coronary arteries, coronary blood flow is obstructed by the bioprosthetic valve leaflets after transcatheter aortic valve replacement. After BASILICA, blood flows through the open cells of the transcatheter heart valve unimpeded into the coronary artery. BASILICA = bioprosthetic or native aortic scallop intentional laceration to prevent iatrogenic coronary artery obstruction; LCA = left coronary artery; RCA = right coronary artery.

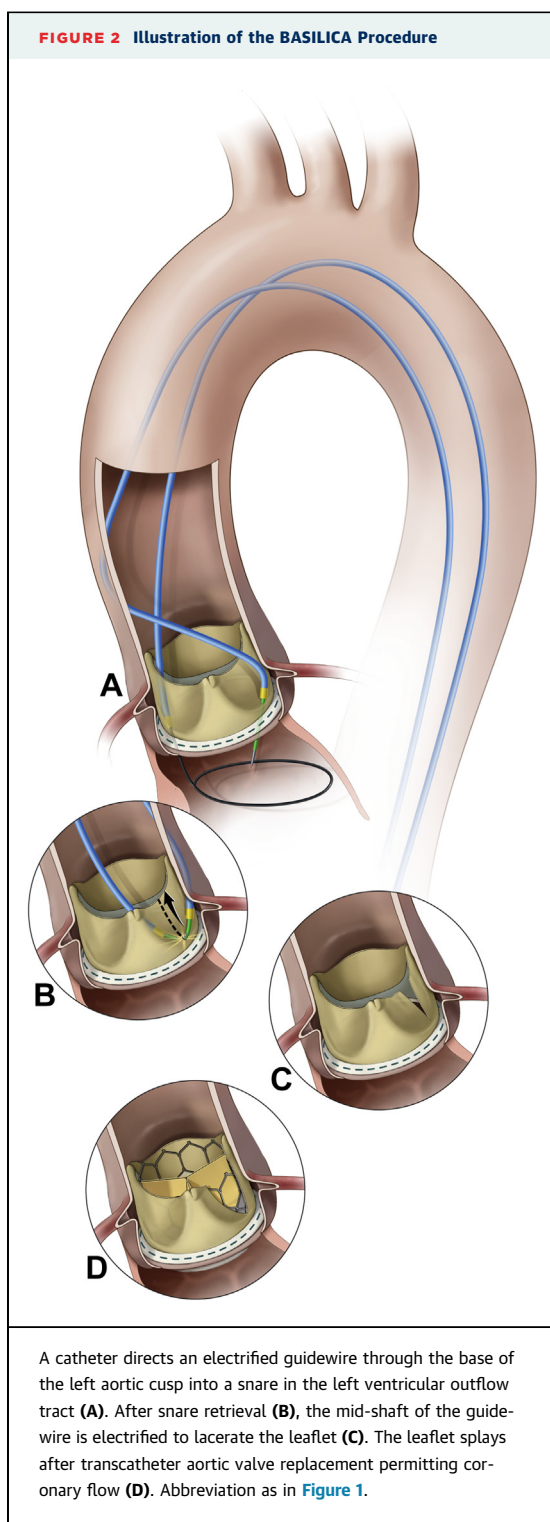
mid-point to tip. A third scallop was left intact and served as a control.

Balloon expandable (20-mm Sapien 3, Edwards Lifesciences, Irvine, California) and self-expanding valves (23-mm Evolut Pro, Medtronic, Minneapolis, Minnesota) were deployed in the bioprosthetic valve to test splaying of split leaflet around the open cells of the transcatheter heart valve and propagation of the split in the leaflet. A second valve (25-mm Mitroflow, Sorin Livanova, London, England) was cut with a scalpel and leaflet splaying was also tested with appropriately sized balloon expanding and self-expanding valves.

ANIMALS. Animal experiments on naive Yorkshire and Yucatan pigs were approved by the institutional animal care and use committee and conducted per contemporary National Institutes of Health guidelines. Anesthesia was induced and maintained with mechanical ventilation and inhaled isoflurane, 2 femoral arterial sheaths of 6-F catheter and a 9-F catheter femoral venous sheath were placed

percutaneously, and heparin and amiodarone were administered. The BASILICA procedure without TAVR was performed using catheters directed under biplane x-ray fluoroscopy and intracardiac echocardiography guidance. Pre-procedural cardiac magnetic resonance imaging was performed at 1.5-T (Aera, Siemens, Erlangen, Germany) to plan fluoroscopy projection angles. Hemodynamics were recorded for 1 h after laceration until euthanasia. The length of scallop laceration relative to the overall length of the scallop was measured using calipers at necropsy. The heart was carefully inspected for evidence of bystander electrical or mechanical injury.

CLINICAL. Patients. Patients with high or prohibitive risk for surgical aortic valve replacement and high risk of coronary artery obstruction with TAVR underwent TAVR with BASILICA at 3 medical centers (University of Washington, Henry Ford, and Emory University Hospitals). All consented to clinical treatment on a compassionate basis, despite explicitly high risk, after consensus from the local



multidisciplinary heart teams. The institutional ethics review boards of all participating institutions approved this retrospective report.

The local heart teams determined coronary obstruction risk based on manufacturer-described

geometry of the specific implanted bioprosthetic valve; and computed tomography (CT) and angiographic measurements of the coronary ostia heights, sinus of Valsalva width, presence and type of bioprosthetic valve, and virtual transcatheter heart valve to coronary distance (Figure 1) (5).

BASILICA procedure. The procedure was planned using electrocardiogram-gated contrast-enhanced CT, performed under general anesthesia, and guided by fluoroscopy and transesophageal echocardiography. Catheter access was obtained typically via 3 femoral arterial (2 typically ipsilateral for BASILICA, and 1 for TAVR) and at least 1 venous (for temporary transvenous pacing) introducer sheaths. Heparin anticoagulation achieved an activated clotting time >300 s.


A pair of coaxial catheters (typically a 5-F mammary diagnostic catheter inside a 6-F extra backup shape-guiding catheter) was positioned in the targeted aortic leaflet scallop to direct a guidewire across it, near the scallop hinge point, by echocardiographic and angiographic guidance. These aimed at a snare positioned immediately below the leaflet using a separate retrograde catheter (Figure 2, Online Video 1).

To traverse the aortic leaflet scallop, a 0.014-inch guidewire (Astato XS 20, Asahi-Intecc, Santa Ana, California) sheathed in an insulated polymer jacket (Piggyback Wire Convertor, Vascular Solutions Teleflex, Minneapolis, Minnesota) was electrified, advanced, and snare-retrieved. The wire was electrified using a short burst of “cutting” radiofrequency energy (~30 W) by clamping to an electrosurgery pencil (Valleylab FX, Covidien Medtronic, Minneapolis, Minnesota).

After externalization of the free guidewire end, the guidewire straddles across the leaflet scallop between 2 catheters. The scallop was lacerated by applying radiofrequency energy at approximately 70 W while tensioning both free ends of the guidewire. A pigtail catheter was pre-positioned in the left ventricle to allow TAVR to be performed immediately afterward.

TAVR was performed using established techniques. Coronary artery stent systems were positioned prophylactically at the discretion of the operator. Cracking of a failed bioprosthetic heart valve frame, using a high-pressure balloon (11), was performed at operator discretion to achieve an optimum hemodynamic result. Coronary artery patency was assessed using angiography and post-TAVR CT. Antiplatelet and anticoagulation therapy were prescribed at operator discretion. Complications were assessed according to the Valve Academic Research Consortium-2 Consensus Document (12).

FIGURE 3 Benchtop Simulation of BASILICA



Two different transcatheter heart valves (23-mm Sapien 3, **A, B**; 26-mm Evolut Pro, **C, D**) implanted in 25-mm Mitroflow before (**A, C**) and after (**B, D**) the leaflet is cut with a scalpel.

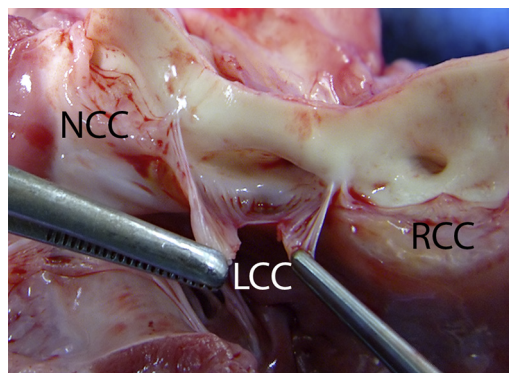
STATISTICAL ANALYSIS. In this small clinical series, we express continuous variables as median and interquartile range. We express categorical variables as counts and percentages. We made no statistical comparisons because of the small sample size.

RESULTS

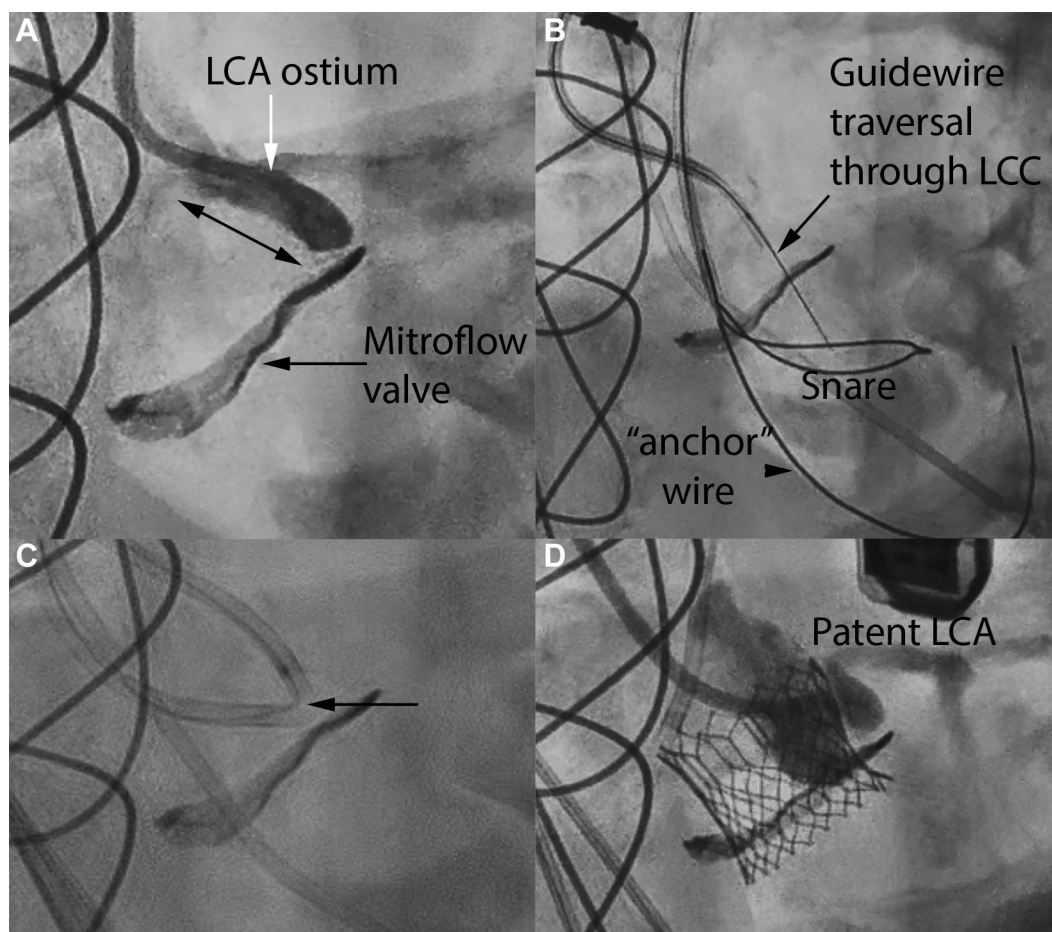
IN VITRO. A guidewire (Astato XS 20, Asahi) perforated a bioprosthetic bovine pericardial valve leaflet (Trifecta, Abbott St. Jude Medical) using a <1-s burst of radiofrequency energy at 20 W in a saline bath. Laceration with a continuous nonionic (5% dextrose) flush through 2 guiding catheters required 5 s (half leaflet) and 18 s (full leaflet) of radiofrequency energy at 20 W. Laceration using mechanical force without electrification was not possible in this valve.

A 20-mm Sapien 3 valve (Edwards Lifesciences) was deployed on the benchtop inside the lacerated Trifecta valve. The laceration mid-way down the

FIGURE 4 Necropsy After BASILICA in an Animal



Animal necropsy viewed from the aorta showing a split left coronary cusp in line with the left coronary artery ostium. LCC = left coronary cusp; NCC = noncoronary cusp; RCC = right coronary cusp.

FIGURE 5 BASILICA for Transcatheter Aortic Valve Replacement With Sapien 3 in Failed Mitroflow Valve

(A) Left coronary injection demonstrates a high risk of left coronary obstruction from the Mitroflow leaflet (double headed arrow). (B) Coaxial catheters direct an electrified guidewire through the left coronary leaflet of the Mitroflow valve into the left ventricular outflow tract snare. (C) Laceration with radiofrequency concentrated at the kinked mid-shaft of the Astato guidewire (arrow). (D) Left cusp injection with flow through split leaflet and patent left coronary artery that would otherwise have been obstructed. Abbreviations as in Figures 1 and 4.

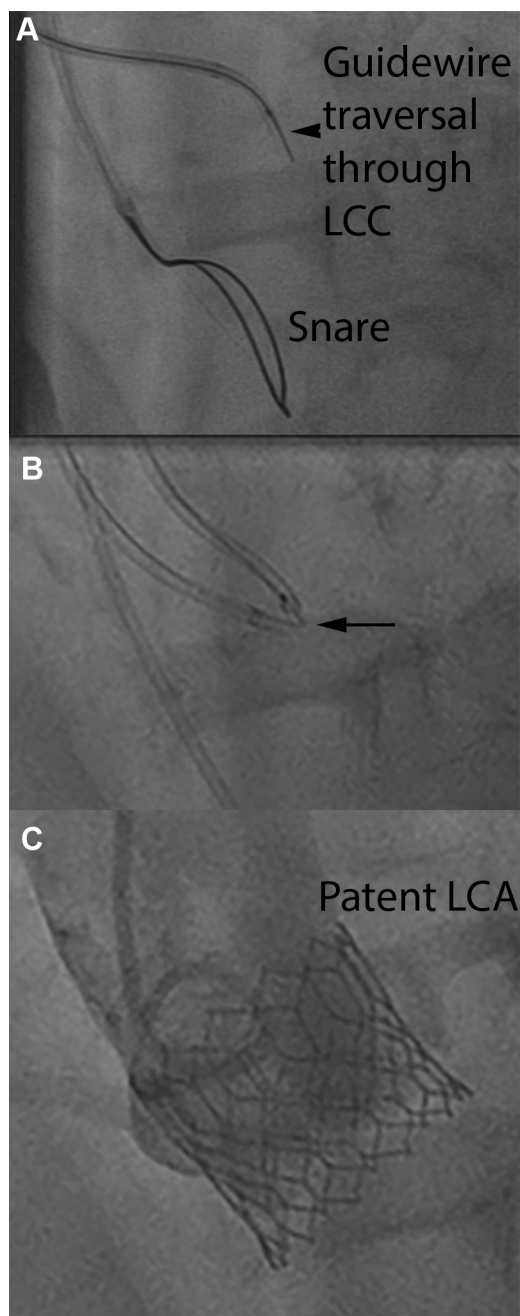
bioprosthetic scallop did not propagate, nor did it result in satisfactory parting of the leaflet. The full-length laceration did not propagate further and resulted in satisfactory parting of the leaflet. The intact leaflet completely draped the Sapien 3 stent cells. The results with the cut Mitroflow valve were similar (Figure 3). Flaring of the bioprosthetic stent posts increased splaying of the split leaflet.

ANIMALS. Five consecutive pigs (38 to 47 kg) underwent attempted BASILICA, 3 on the left coronary cusp and 2 on both left and right coronary cusps (Online Table S1). The procedure time reduced with further experience, despite the increased complexity of double BASILICA. BASILICA resulted in severe aortic

regurgitation with a reduction in diastolic blood pressure in all pigs. Two pigs required euthanasia before 1 h was complete because of poor hemodynamics, the first after inadvertent mitral chordal laceration, and the other following double BASILICA.

Guidewire traversal required <1 s of radiofrequency energy at 20 to 30 W for all 5 animals. Guidewire laceration required 2 to 3 s of radiofrequency energy at 30 W and <1 s at 70 W. Minimal subjective mechanical force was required for both traversal and laceration. Laceration was central and extended from base to tip in all animals (mean laceration length was 12 mm and mean cusp length 14 mm for the left, and 12 mm and 12.5 mm, respectively, for the right) (Figure 4).

FIGURE 6 BASILICA and Transcatheter Aortic Valve Replacement With Sapien 3 for Native Aortic Stenosis



(A) An electrified guidewire traverses native left coronary cusp leaflet into the left ventricular outflow tract snare. (B) Leaflet laceration through exposed kinked guidewire shaft (arrow). (C) Aortic root angiography showing coronary flow in a low-lying coronary artery that may have been obstructed without BASILICA. Abbreviations as in Figures 1 and 4.

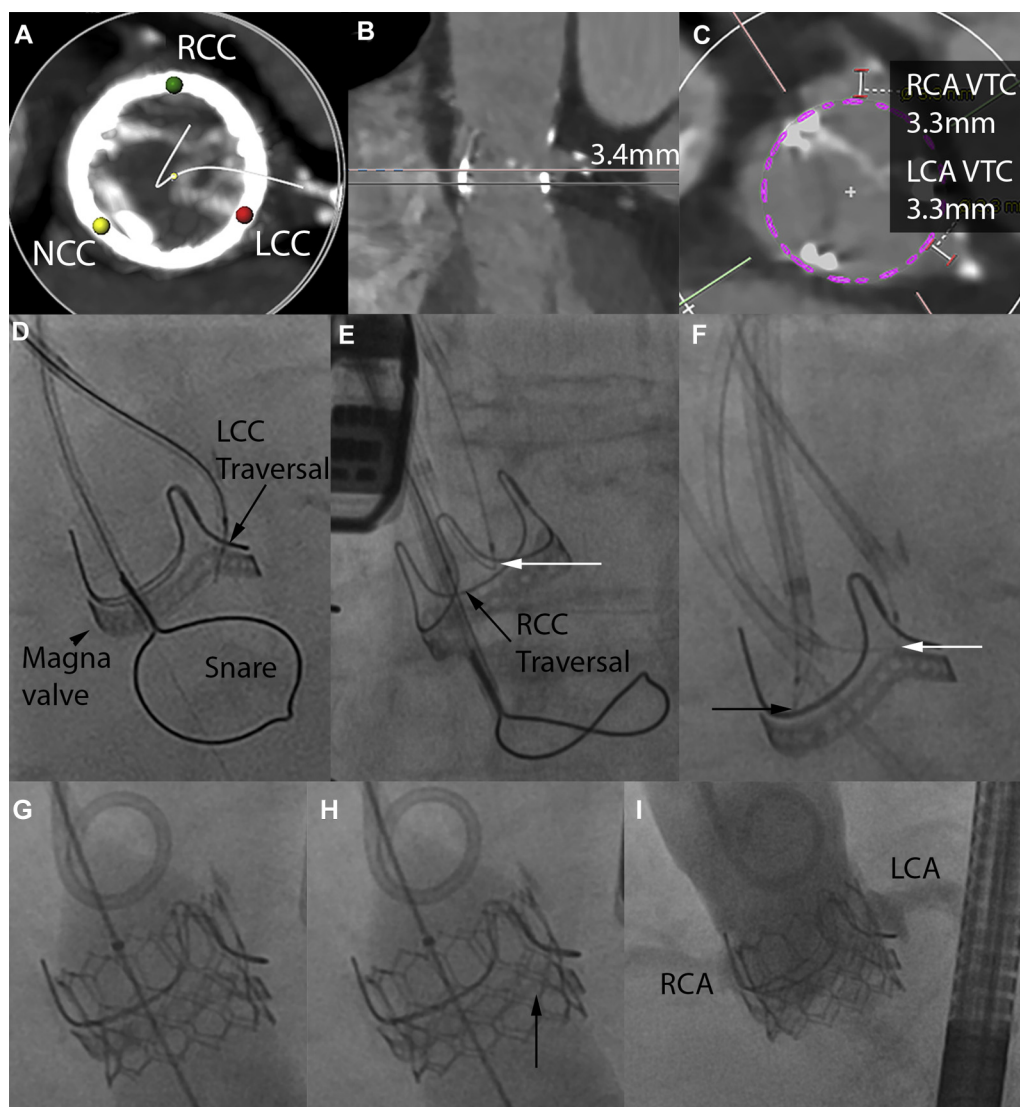
Major complications occurred in the first attempted animal BASILICA for left and right coronary cusps, respectively. These included mitral chord entrapment and laceration resulting in severe mitral regurgitation; misdirected wire traversal into the left atrium or interventricular septum, the latter causing ventricular fibrillation requiring defibrillation; and partial annular laceration without pericardial effusion from annulus rather than leaflet traversal. Thereafter we refined the BASILICA technique (assiduous positioning of the traversal wire and of the snare catheter in the distal left ventricular outflow tract) and observed no important complications. There was no macroscopic evidence of collateral thermal damage in benchtop or in vivo necropsy specimens.

CLINICAL. Seven patients underwent TAVR with BASILICA (Figures 5 to 9). There were a range of diseased aortic valve substrates: 1 had a porcine aortic stent-less bioprosthesis valve, 1 had a stent-less bovine pericardial valve, 4 had stented bovine pericardial valves, and 1 had native aortic valve stenosis. One of the 7 required laceration of 2 aortic leaflet scallops and the rest of only the left.

Table 1 shows their clinical characteristics. All were believed to be unsuitable for surgery by the multidisciplinary heart teams. Five had prior coronary artery bypass grafts that were believed not to protect threatened vessels. Six had failed bioprosthetic aortic valves and 1 had native aortic stenosis. All were believed to be at high risk of left coronary obstruction with median coronary height of 6.8 mm, left sinus of Valsalva width of 24.3 mm, and virtual transcatheter valve to coronary distance of 2.8 mm (Online Figure 2). One patient also had a threatened right coronary artery (Online Table S2).

Table 2 details the procedure. All attempted leaflets were successfully traversed and lacerated. The laceration was central and along most of the leaflet length as depicted on transesophageal echocardiography (Figure 8B). All patients had severe aortic regurgitation after laceration. Heart rate and systolic blood pressures were unchanged in all cases, and no patient required pharmacologic or mechanical hemodynamic support in the 8 to 30 min between laceration and valve deployment, nor afterward.

No patient had coronary obstruction evident on coronary and aortic root angiography, nor echocardiographic regional wall motion assessment. One of the pre-positioned stents was entrapped by the transcatheter heart valve and so was deployed in the left main coronary artery in the absence of coronary obstruction, otherwise all others were removed from

FIGURE 7 Double BASILICA and Transcatheter Aortic Valve Replacement With Sapien 3 for Failed Magna Valve

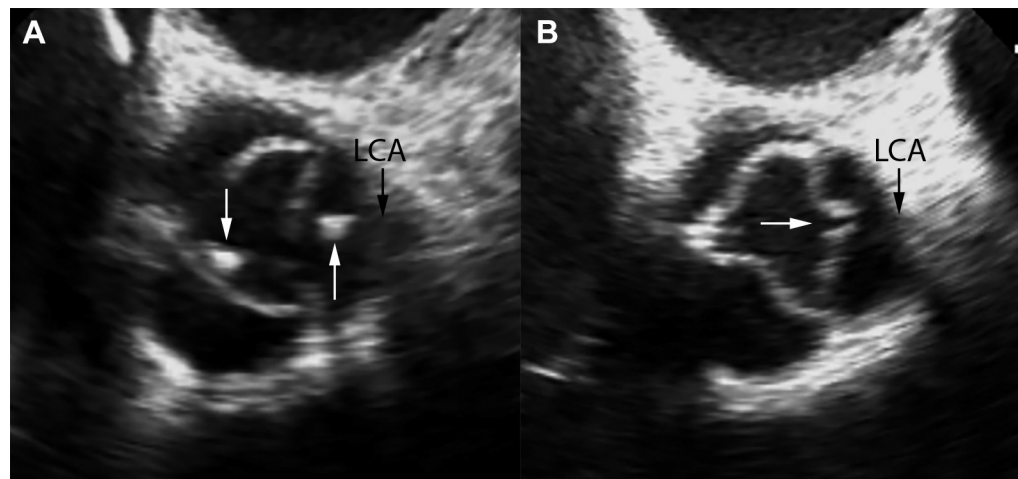
(A) Heavily calcified leaflets, especially the left coronary cusp. (B) Left coronary height is low at 3.4 mm. (C) Both left and right VTC are low at 3.3 mm. (D) An electrified guidewire traverses the left coronary leaflet of a Magna valve. (E) The left coronary leaflet guidewire has been externalized to form a loop and a second electrified guidewire traverses the right coronary leaflet. (F) Loops formed around both left (white arrow) and right (black arrow) coronary cusps, ready for sequential laceration. (G) After transcatheter aortic valve replacement a high-pressure balloon is inflated to crack the bioprosthetic valve to improve hemodynamics. (H) The bioprosthetic valve has been fractured at the site of the black arrow. (I) Angiography demonstrates good flow to both coronary arteries that may otherwise have been completely obstructed. VTC = virtual transcatheter valve to coronary distance; other abbreviations as in Figures 1 and 4.

the body undeployed. Procedural hemodynamics confirmed satisfactory valve gradients and no patient with more than mild paravalvular leak. Three patients had follow-up CT scans confirming good flow in the coronary arteries.

Clinical outcomes and standardized TAVR endpoints are shown in Table 3 and Online Table S3 (12).

One patient had transient sinus bradycardia requiring temporary transvenous pacing. There were no other complications. Four patients underwent precautionary intensive care unit observation overnight; the remainder were transferred directly to ward beds. The median length of stay was 4 days. All patients survived beyond 30 days.

FIGURE 8 Transesophageal Echocardiography During BASILICA and Transcatheter Aortic Valve Replacement With Sapien 3 for Failed Sorin Solo Freedom Valve



(A) Echocardiography view showing the traversal catheter is aligned at the base of the left coronary cusp (upward white arrow). A snare catheter is positioned across the valve (downward white arrow). (B) The laceration in the left coronary cusp is seen (white arrow), adjacent to the left coronary artery ostium. Abbreviation as in Figure 1.

DISCUSSION

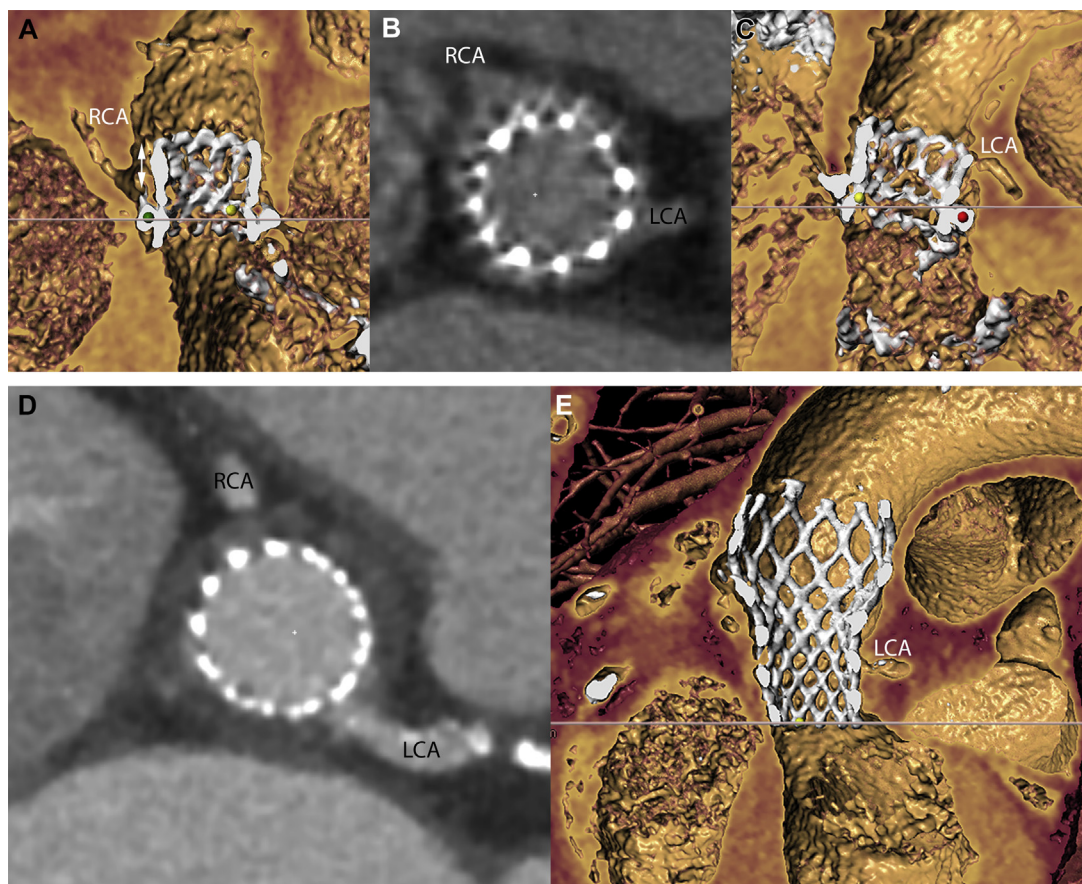
We describe a new technique that allows transcatheter heart valve treatment in patients otherwise ineligible for any therapy because of a high risk of valve leaflet-induced coronary artery obstruction. We have demonstrated through benchtop testing, animal experiments, and experience from 7 patients that: 1) BASILICA seems technically feasible in all valve types and valve conditions, including single and double leaflet laceration, porcine and bovine pericardial bioprostheses, stented and stent-less bioprostheses, and in 1 case of native aortic leaflet disease; 2) there was no hemodynamic collapse after laceration regardless of baseline aortic regurgitation ($n = 5$) or aortic stenosis ($n = 2$); and 3) there was uniform success in preserving coronary blood flow.

The current strategy of ad hoc percutaneous intervention or up-front coronary protection using a pre-positioned wire, with or without balloon or stent, is problematic. Coronary obstruction may be delayed despite normal flow at the end of the TAVR procedure (13). There are few data to support the longevity of a “chimney” coronary stent extending beyond the coronary ostium with a valve leaflet draped across it. The ostial left main stent is at risk of fatal restenosis and thrombosis (14). Re-engaging a coronary artery is challenging after TAVR, and becomes almost impossible with an ostial “chimney” stent (14,15). As seen in Patient #7, the stent can be entrapped and then

requires unnecessary deployment. Applying caution in this initial human experience, the threatened coronaries were still protected by wiring and placing a stent mid-vessel after BASILICA. Although the 1 entrapped stent confirmed the preprocedural concern for coronary obstruction and need for intervention to allow safe TAVR, the inability to remove the stent necessitated deployment despite otherwise successful BASILICA. It is difficult to know at this early stage whether pre-positioning a stent after successful BASILICA is mandated or whether the harm outweighs the benefits. As experience with BASILICA and its success increases, we would predict a transition to no prophylactic coronary stent protection.

One application of BASILICA not yet performed but worth considering is to treat failed TAVR devices, which are likely to become more common as TAVR is applied to lower-risk patients who are expected to live longer. The risk of coronary obstruction in patients with previous TAVR may be elevated in patients with high implantation and supra-annular TAVR devices engineered to have longer leaflets (such as Medtronic Corevalve). Several transcatheter heart valves are implanted with the top of the valve at the sinotubular junction where coronary filling is dependent on diastolic valve-leaflet closure. We speculate that BASILICA may be helpful in this setting.

In this small series, we observed that split leaflets continued to appose during diastole, and caused incremental but not catastrophic aortic regurgitation.

FIGURE 9 Computed Tomography Images Following BASILICA and Transcatheter Aortic Valve Replacement With Sapien 3 and Evolut Pro

(Top) Sapien 3; (Bottom) Corevalve Evolut Pro. (A and B) A narrow neosinus (double-headed arrow) maintains flow to the right coronary artery but the left sinus (B and C) is completely effaced. (D and E) The left coronary artery was at risk of occlusion but there is adequate filling following BASILICA. Abbreviations as in Figure 1.

Patients did not require pharmacologic or mechanical support during the short period before TAVR.

STUDY LIMITATIONS. Our experience remains limited, and confined to the specific bioprosthetic devices and single native valve described. The leaflets may splay variably depending on the type of bioprosthetic and transcatheter heart valve combination used, as may flow through the open cells of the transcatheter heart valve. Despite successful BASILICA, TAVR device commissures may limit flow to the coronary arteries by accidentally unfavorable rotational orientation.

We observed no hemodynamic deterioration between BASILICA laceration and TAVR in this small series. Our patients had relatively preserved left ventricular systolic function (Table 1). Although 2 of 7

had primarily stenotic lesions and 3 of 7 primarily mixed stenotic and regurgitant, the applicability to patients with more profound ventricular dysfunction requires further investigation. Likewise, despite operator precautions, BASILICA may injure mitral valvular structures.

The role of BASILICA combined with intentional balloon fracture to expand the valve frame (11), remains uncertain. Double-leaflet BASILICA poses extra challenges particularly with vascular access. Heavily calcified leaflets are probably unsuited to BASILICA, as evidenced by the prolonged procedure time because of difficulty traversing in Patient #4.

Although there were no evident strokes in this initial series, lacerating a heavily calcified leaflet may generate embolic debris that cause stroke and in this setting, judicious use of cerebral embolic protection

TABLE 1 Clinical Characteristics

	All	Patient #						
		1	2	3	4	5	6	7
Age, yrs	74 (70-76)	87	74	74	67	78	68	71
Female, %	86	1	1	1	0	1	1	1
STS PROM aortic replacement, %	12.7 (6.3-14.1)	13.4	4.6	19.5	2.0	12.7	8.0	14.7
Frailty, %	67	1	1	1	0	1	0	NA
Coronary artery disease, binary, %	71	1	1	0	1	0	1	1
Prior CABG, %	71	1	1	0	1	0	1	1
Prior stroke, %	14	0	0	0	0	0	0	1
Atrial fibrillation, %	57	1	0	1	0	1	0	1
eGFR, ml/min/1.73 m ²	53 (41-61)	60	31	12	62	51	65	53
NT-proBNP baseline, pg/ml	517 (289-709)	701	332	712	2,145	262	275	NA
NYHA CHF functional class	3 (3-4)	4	3	4	3	3	3	3
Severe pulmonary disease, %	29	0	0	0	0	1	1	0
LV ejection fraction, %	0.58 (0.45-0.60)	65	58	45	45	60	60	40
RV dysfunction, %	14	0	0	0	0	1	0	0
Porcelain aorta, %	14	0	0	0	0	0	1	0
TAVR setting (native or valve-in-valve)	Valve-in-valve, 86%	Valve-in-valve	Valve-in-valve	Valve-in-valve	Valve-in-valve	Native	Valve-in-valve	Valve-in-valve
Bioprosthetic valve nominal diameter, mm	21 (21-23)	19	21	21	23	NA	21	23
Bioprosthetic valve type		Trifecta	Toronto SPV	Mitroflow	Mitroflow	NA	Magna	Sorin Solo Freedom SMT
Bioprosthetic implant age, yrs	5 (3-11)	6	14	4	3	NA	13	2
Primary lesion	Regurgitation, 3; Regurgitation stenosis, 2; mixed, 2	Regurgitation	Regurgitation	Mixed	Mixed	Stenosis	Stenosis	Regurgitation
Suitability for cardiac surgery		Inoperable because of advanced age, marked frailty, and prospect of repeat cardiac surgery	Inoperable because of grafts threatened by repeat surgery, marked frailty, and renal dysfunction	Inoperable because of functional class IV symptoms, prospect of combined mitral and aortic surgery after prior AVR, worsening kidney disease with creatinine >300 μmol/L, recent cardiopulmonary arrest	Prolonged recovery after prior MVR/AVR/CABG believed by surgical team better treated by catheter; patient declined repeat surgery	Inoperable because of very poor functional status and ongoing radiation therapy for thoracic malignancy Long aortic leaflets obstruct coronaries during test balloon inflation and aortography	Prohibitively high operative risk with porcelain aorta, mitral annular calcification, prospect of ascending and root aorta repair along with AVR and MVR	Inoperable because of NYHA functional class IV symptoms, radiotherapy for malignancy, moderate left ventricular dysfunction, prior stroke, prior AVR + MVR + atrial ablation + LAA ligation

AVR = aortic valve replacement; CABG = coronary artery bypass grafting; CHF = congestive heart failure; eGFR = estimated glomerular filtration rate; LAA = left atrial appendage; LV = left ventricle; MVR = mitral valve replacement; NA = not applicable; NT-proBNP = N-terminal pro-B-type natriuretic peptide; NYHA = New York Heart Association; RV = right ventricle; STS PROM = Society of Thoracic Surgery predicted risk of mortality; TAVR = transcatheter aortic valve replacement.

strategies, and brain magnetic resonance imaging, may be appropriate. Protracted radiofrequency ablation is widely used in the left atrium and left ventricle with a low risk of coronary and cerebral thromboembolism. By comparison we use shorter bursts of vaporizing high duty-cycle “cutting mode” electrosurgery, also with full anticoagulation. Human

cadaver experiments may shed light on the potential for embolization during bioprosthetic and native aortic valve manipulation.

Coronary flow was assessed angiographically by assessing echocardiographic left ventricular wall motion but a pressure wire or other intracoronary imaging was not used.

TABLE 2 Procedure Characteristics and Hemodynamics

	All	Patient #						
		1	2	3	4	5	6	7
Transcatheter heart valve	Sapien 3, 6; Evolut Pro, 1	Sapien 3	Evolut Pro	Sapien 3	Sapien 3	Sapien 3	Sapien 3	Sapien 3
Transcatheter heart valve size, mm	23 (22–23)	20	23	23	23	26	20	23
Transcatheter heart valve post-dilatation	14%	0	0	0	0	0	1	0
Invasive hemodynamics baseline								
Aortic regurgitation severity (0 = none, 1 = trace, 2 = mild, 3 = moderate, 4 = severe)	4 (3–4)	4	4	4	3	2	2	4
Aortic valve peak-to-peak gradient, mm Hg	43 (14–64)	12	8	43	72	56	135	15
HR	75 (71–80)	84	72	67	77	69	83	75
SBP	126 (96–148)	151	126	93	95	166	145	97
DBP	44 (39–50)	32	47	35	53	73	42	44
LVEDP	31 (22–34)	23	21	35	36	31	32	16
Invasive hemodynamics completion								
Aortic regurgitation severity (0 = none, 1 = trace, 2 = mild, 3 = moderate, 4 = severe)	0 (0–1)	0	0	1	0	0	1	2
Aortic valve peak-to-peak gradient, mm Hg	1 (1–7)	1	10	1	12	0	0	3
HR	81 (79–84)	80	82	85	79	62	87	40 (sinus brady, paced at 80)
SBP	175 (151–179)	177	151	175	120	181	197	150
DBP	68 (64–72)	64	63	79	68	72	57	71
LVEDP	27 (26–30)	34	28	26	26	27	18	31
Echocardiography, baseline								
Aortic regurgitation severity (0 = none, 1 = trace, 2 = mild, 3 = moderate, 4 = severe)	4 (3–4)	4	4	3.5	4	3	2	4
Aortic valve peak velocity, m/s	3.4 (3.2–4.6)	3.3	3.1	5.6	4.1	3.4	5.0	1.6
Aortic valve mean gradient, mm Hg	24 (22–48)	24.0	22.0	67.0	22.6	45.4	51.0	4.8
Indexed effective orifice area, m ² /m ²	0.62 (0.49–1.00)	1.0	1.6	0.48	0.31	0.49	0.62	1.0
LVEF, %	58 (45–60)	65	58	45	45	60	60	35
Echocardiography, pre-discharge								
Aortic regurgitation severity (0 = none, 1 = trace, 2 = mild, 3 = moderate, 4 = severe)	0 (0–0)	0	0	1	0	0	0	0
Aortic valve peak velocity, m/s	2.9 (2.7–3.2)	3.3	2.7	3.6	2.6	3.1	2.9	1.6
Aortic valve mean gradient, mm Hg	18 (17–21)	17.0	16.0	28.2	17.6	21.0	20.0	4.8
LVEF, %	61 (56–65)	71	64	61	51	60	65	35

DBP = diastolic blood pressure; HR = heart rate; LVEDP = left ventricular end diastolic pressure; LVEF = left ventricular ejection fraction; SBP = systolic blood pressure.

TABLE 3 Clinical Outcomes

	All	Patient #						
		1	2	3	4	5	6	7
Length of stay after TAVR, days	4 (4–5)	4	4	6	1	5	5	3
ICU stay, days	1 (0–2)	2	2	0	0	1	1	0
Survival to hospital discharge	100%	1	1	1	1	1	1	1
Survival 30 days	100%	1	1	1	1	1	1	1
Survival ascertainment, days	116 (109–153)	154	154	151	116	109	109	95
NYHA functional class at latest follow-up	2.0 (1.5–2.0)	2	2	1	2	1	2	2

Values are median (interquartile range) or %. ICU = intensive care unit; other abbreviations as in Table 1.

Finally, there was no comparator and so coronary artery obstruction was not certain but predicted using prevailing standards, which have their limitations. The potential risk and benefit of BASILICA should be weighed before applying it to any patient, including the risk of embolization and, in patients with severe ventricular dysfunction, the risk of acute severe aortic regurgitation.

We believe technical descriptions are no substitute for live observation, and we recommend BASILICA only be undertaken with appropriate training.

CONCLUSIONS

Bioprosthetic and native aortic leaflet laceration seems feasible and may reduce the risk of coronary artery obstruction following TAVR in patients at high risk. No patient had a drop in blood pressure following BASILICA. The technique offers a promising alternative to “chimney” stenting to provide durable prevention against coronary obstruction from TAVR. BASILICA needs careful prospective investigation, which begins with a Food and Drug Administration-approved trial in early 2018.

ACKNOWLEDGMENTS The authors thank Alan Hoofring for medical illustrations; Katherine Lucas for animal care; Daniel Herzka, Merdim Sonmez, and Dmitri Levin for technical assistance; Norihiko Kamioka, Lauren Wheeler, and Patricia Keegan for data assistance; and Elena Grant and James McCabe for thoughtful advice. They thank Richard Olson of Abbott for supplying a sample Trifecta valve in anticipation of helping the first patient.

ADDRESS FOR CORRESPONDENCE: Dr. Robert J. Lederman, Cardiovascular Branch, Division of

Intramural Research, National Heart, Lung, and Blood Institute, National Institutes of Health, Building 10, Room 2C713, MSC 1538, Bethesda, Maryland 20892-1538. E-mail: lederman@nih.gov.

PERSPECTIVES

WHAT IS KNOWN? Coronary obstruction following TAVR carries up to 50% mortality, and CT-predicted coronary obstruction may deprive patients of TAVR as a therapeutic option. Current methods of pre-emptive or bail-out coronary stenting are suboptimal.

WHAT IS NEW? We describe a catheter technique (BASILICA) to lacerate aortic leaflets that otherwise threaten to obstruct a coronary artery during TAVR. After TAVR, which is performed immediately after BASILICA, blood is able to flow across the lacerated aortic leaflets into the coronary arteries.

WHAT IS NEXT? BASILICA may have value in the future as more patients have bioprosthetic surgical and even transcatheter aortic valves likely to degenerate. BASILICA warrants further prospective evaluation in a larger number of patients.

REFERENCES

1. Leon MB, Smith CR, Mack MJ, et al. Transcatheter or surgical aortic-valve replacement in intermediate-risk patients. *N Engl J Med* 2016; 374:1609–20.
2. Reardon MJ, Van Mieghem NM, Popma JJ, et al. Surgical or transcatheter aortic-valve replacement in intermediate-risk patients. *N Engl J Med* 2017; 376:1321–31.
3. Dvir D, Webb JG, Bleiziffer S, et al. Transcatheter aortic valve implantation in failed bioprosthetic surgical valves. *JAMA* 2014;312:162–70.
4. Webb JG, Mack MJ, White JM, et al. Transcatheter aortic valve implantation within degenerated aortic surgical bioprostheses: PARTNER 2 Valve-in-Valve Registry. *J Am Coll Cardiol* 2017; 69:2253–62.
5. Ribeiro HB, Rodés-Cabau J, Blanke P, et al. Incidence, predictors and clinical outcomes of coronary obstruction following transcatheter aortic valve replacement for degenerative bioprosthetic surgical valves: insights from the VIVID Registry. *Eur Heart J* 2018;39:687–95.
6. Ribeiro HB, Webb JG, Makkar RR, et al. Predictive factors, management, and clinical outcomes of coronary obstruction following transcatheter aortic valve implantation: insights from a large multicenter registry. *J Am Coll Cardiol* 2013;62:1552–62.
7. Yamamoto M, Shimura T, Kano S, et al. Impact of preparatory coronary protection in patients at high anatomical risk of acute coronary obstruction during transcatheter aortic valve implantation. *Int J Cardiol* 2016;217:58–63.
8. Abramowitz Y, Chakravarty T, Jilaihawi H, et al. Clinical impact of coronary protection during transcatheter aortic valve implantation: first reported series of patients. *EuroIntervention* 2015; 11:572–81.
9. Khan JM, Rogers T, Schenke WH, et al. Intentional laceration of the anterior mitral valve leaflet to prevent left ventricular outflow tract obstruction during transcatheter mitral valve replacement: pre-clinical findings. *J Am Coll Cardiol Intv* 2016;9:1835–43.
10. Babaliaros VC, Greenbaum AB, Khan JM, et al. Intentional percutaneous laceration of the anterior mitral leaflet to prevent outflow obstruction during transcatheter mitral valve replacement: first-in-human experience. *J Am Coll Cardiol Intv* 2017;10:798–809.
11. Chhatrivala AK, Allen KB, Saxon JT, et al. Bioprosthetic valve fracture improves the hemodynamic results of valve-in-valve transcatheter aortic valve replacement. *Circ Cardiovasc Interv* 2017;10.
12. Kappetein AP, Head SJ, Genereux P, et al. Updated standardized endpoint definitions for transcatheter aortic valve implantation: the Valve Academic Research Consortium-2 consensus document. *J Am Coll Cardiol* 2012;60:1438–54.
13. Dvir D, Webb J, Brecker S, et al. Transcatheter aortic valve replacement for degenerative bioprosthetic surgical valves: results from the global valve-in-valve registry. *Circulation* 2012;126: 2335–44.
14. Dvir D. Transcatheter aortic valve-in-valve implantations: lessons from bench to bedside [oral presentation]. Presented at: Transcatheter Valve Therapies; June 14 to 17, 2017; Chicago, IL.
15. Valsecchi O, Vassileva A. The chimney technique during valve in valve TAVR in stentless freestyle [oral presentation]. Presented at: Joint Interventional Meeting Milan (JIM); February 9 to 11, 2017; Milan, Italy.

KEY WORDS bioprosthetic heart valve failure, coronary artery obstruction, structural heart disease, transcatheter aortic valve replacement, transcatheter electrosurgery

APPENDIX For supplemental tables, figures, and a video, please see the online version of this paper.