

Transcatheter Aortic Valve Replacement During Pregnancy

Robert Hodson, Eric Kirker, Jeffrey Swanson, Craig Walsh, Ethan C. Korngold, and Sarah Ramelli

2016, 9 (10), • DOI: 10.1161/CIRCINTERVENTIONS.116.004006 • Publication Date (Web): 12 Oct 2016

Downloaded from www.ahajournals.org on May 20, 2020

More About This Article

Additional resources and features associated with this article are available within the HTML version:

- Supporting Information
- Access to high resolution figures
- Links to articles and content related to this article
- Copyright permission to reproduce figures and/or text from this article

Transcatheter Aortic Valve Replacement During Pregnancy

Robert Hodson, MD; Eric Kirker, MD; Jeffrey Swanson, MD; Craig Walsh, MD, MPH;
Ethan C. Korngold, MD; Sarah Ramelli, MS

Transcatheter aortic valve replacement (TAVR) is an approved and widely accepted standard treatment for severe symptomatic aortic stenosis (AS) in high-risk surgical candidates.¹ Severe symptomatic AS during pregnancy presents a difficult clinical challenge.² A 22-year-old female patient presented to our service at 15 weeks' gestation with congenital symptomatic AS. After a thoughtful heart team evaluation, TAVR was recommended to the patient and performed at 22 weeks' gestation. The authors further explore and discuss the preprocedure planning and treatment decisions of this case. The heart team focused on the timing and special considerations needed to ensure the health and safety of the patient and fetus. With careful preprocedural planning, TAVR can be a low-risk treatment option during pregnancy and provide a reliable bridge to a healthy, term delivery.

Case Presentation

A 22-year-old pregnant female patient presented with severe symptomatic AS at 15 weeks' gestation. The patient was 165 cm tall, weighed 74 kg with a body mass index of 27 kg/m² and body surface area of 1.84 m² at the time of presentation. The patient's clinical history includes congenital bicuspid aortic valve disease, which required balloon aortic valvuloplasty (BAV) at the age of 9 years. Throughout young adulthood, she had been asymptomatic with high levels of activity. Her chief complaints on presentation were increased dizziness, dyspnea on exertion, and chest discomfort. Echocardiography demonstrated a normal ejection fraction, an aortic peak flow velocity of 4.04 m/s, an aortic valve mean gradient of 38.22 mmHg, an aortic valve area of 1.0 cm², and mild-to-moderate aortic insufficiency (AI). The ascending aorta was mildly enlarged (3.9 cm). There was mild narrowing of periductal isthmus with no Doppler gradient (Figure 1; Table 1). Stress echocardiography testing showed moderate AI and below-average exercise capacity. The patient completed 8 to 9 metabolic equivalents of exercise. Echocardiography documented a mean resting aortic valve gradient of 56 mmHg and a postexercise mean gradient of 78 mmHg (Table 2). The difference in aortic valve mean gradients between the routine and stress echocardiographs can be attributed to the difference in time and location of the 2 tests.

Discussion

Treatment Options

Dr Hodson: Symptomatic valvular disease during pregnancy is an uncommon clinical dilemma in North America.

Cardiovascular diseases affect 0.2% to 4% of all pregnancies,³ and untreated cardiac disease during pregnancy accounts for 10% to 15% of maternal mortalities.^{4,5} Congenital bicuspid aortic valve disease, one of the more common congenital heart defects, is known to affect 2% of the general population.^{6,7} Bicuspid aortic valve disease was initially considered a relative contraindication to TAVR procedures, but TAVR procedures are increasingly being performed successfully to treat this condition.⁸ Current guidelines are specific for the treatment of valvular heart disease before pregnancy, including counseling and medical management.⁹⁻¹¹ However, in a pregnancy with class IIb cardiovascular disease with symptomatic AS where surgical intervention is recommended, little direction outside of monitoring and echocardiography examination requirements is provided.^{9,12}

Bicuspid aortic valve disease is often associated with dilation of the ascending aorta. The current evidence supports that hemodynamic wall stress in combination with an underlying connective tissue disorder or genetic abnormality of the ascending aortic media leads to bicuspid aortopathy.¹³ The expected pregnancy-related increase in heart rate, blood pressure, and stroke volume increases aortic wall stress leading to an increased risk of aortic dissection.¹⁴ Careful assessment of the ascending aorta is required in all patients with bicuspid disease because aortic dilation may dictate surgical treatment. Aortic root enlargement >40 mm or an increase in aortic root size during pregnancy seem to be risk factors for type A dissection.¹⁴

Dr Walsh, you first saw this patient and ultimately referred her to the heart team. Can you share your thoughts about treatment options and the discussion with the patient, family, and the patient's perinatologists?

Dr Walsh: Yes, the patient's presentation highlights several important issues about management. Conservative medical management is the first-line therapy in asymptomatic patients.¹² However, the benefits of medical management are limited for symptomatic patients and consist primarily of diuretic treatment.¹⁵ It is well validated that symptomatic stenotic valvular lesions are poorly tolerated during pregnancy and are associated with a high risk of complications and death during delivery.¹⁶⁻¹⁹ Table 3 shows the classification for maternal and fetal risks according to valvular heart lesions as outlined by Reimold and Rutherford.¹⁶ Severe AS with or without symptoms is classified as high risk for both the mother and the fetus.¹⁶ The World Health Organization classifications for maternal cardiovascular risk, first reported by Thorne et al,^{12,20}

From the Providence Heart and Vascular Institute, Providence Structural Heart and Valve Center, Providence St. Vincent Medical Center, Portland, OR. Correspondence to Robert Hodson, MD, Providence Heart and Vascular Institute, Providence Structural Heart and Valve Center, Providence St. Vincent Medical Center, 9205 SW Barnes Rd, Portland, OR 97225. E-mail robert.hodson@providence.org

(*Circ Cardiovasc Interv.* 2016;9:e004006. DOI: 10.1161/CIRCINTERVENTIONS.116.004006.)

© 2016 American Heart Association, Inc.

Circ Cardiovasc Interv is available at <http://circinterventions.ahajournals.org>

DOI: 10.1161/CIRCINTERVENTIONS.116.004006

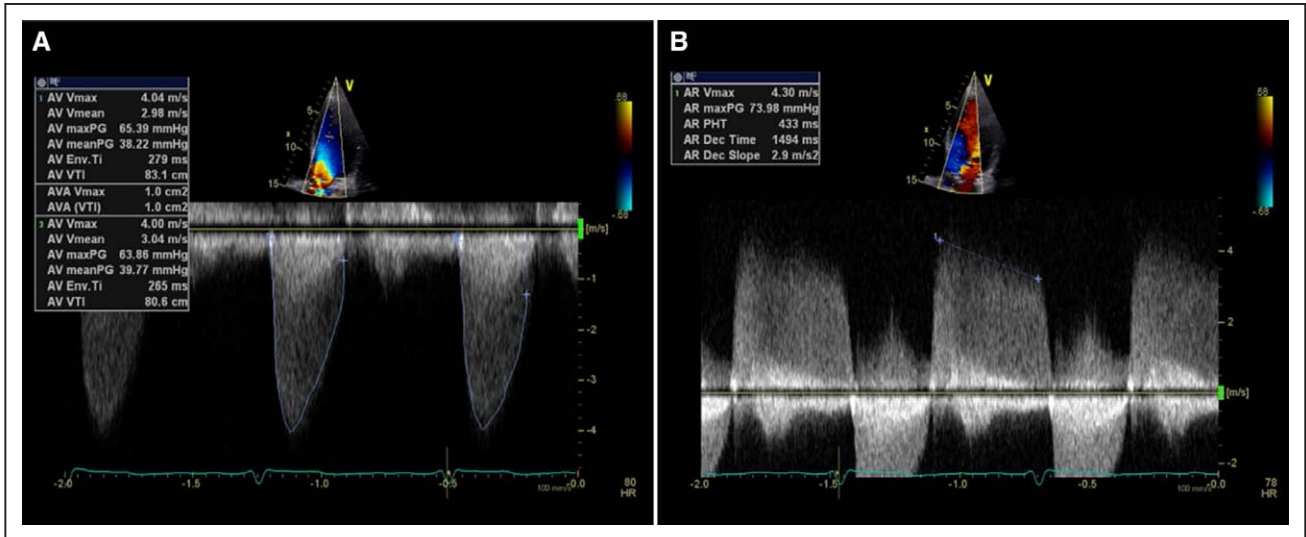


Figure 1. Transthoracic echo images were taken at the time of the patient's presentation to measure and assess. **A**, aortic stenosis and **(B)** aortic regurgitation. AR indicates aortic regurgitation; AV, aortic valve; PG, pressure gradient; PHT, pressure half-time; and VTI, velocity time integral.

are shown in Table 4. Additionally, Thorne et al^{12,20} was the first to apply symptoms to the World Health Organization risk classifications (Table 5) and state that AS (asymptomatic or symptomatic) is a class IV maternal risk with pregnancy being contraindicated.

Because of our patient's symptoms, echocardiographic findings, and stress test results, a conservative management strategy was deemed high risk for both the mother and fetus,²¹ and surgical interventions were recommended as a lower risk treatment strategy compared with medical management.^{22,23}

Dr Hodson: Dr Swanson, what are the surgical considerations for an aortic valve replacement during pregnancy?

Dr Swanson: Surgical aortic valve replacement (SAVR) during pregnancy does pose an increased but acceptable risk to the mother. However, SAVR presents a much higher risk to the fetus. The estimated risk of fetal demise during SAVR is $\approx 20\%$.²⁴ The surgical literature is sparse, with more reported cases from developing countries, in the arena of cardiopulmonary bypass surgery during pregnancy. A literature review of 69 published reports between 1958 and 1992 of cardiopulmonary bypass surgery during pregnancy reported an overall maternal mortality rate of 2.9% and embryo-fetal mortality rate of 20.2% with the mortality and morbidity being lower in the later cases.²⁵ The neonatal-fetal mortality rate was later reported at 29% when cardiopulmonary bypass surgery was performed during pregnancy,³ whereas a 2014 review of 23 emergency or urgent cardiopulmonary bypass surgery during pregnancy in Cairo report 14 fetus losses.²⁶

After discussion with the patient and family, SAVR was not selected because of the unacceptably high risk to the fetus.

Dr Hodson: Dr Korngold, please summarize the team discussion about treatment with BAV.

Dr Korngold: We considered repeating BAV as it is a viable treatment option for AS in pregnant women.^{27,28} BAV has an overall lower associated risk of complication compared with TAVR procedures.²⁹ Serial BAV procedures have been

reported to increase AI in 2.1% of patients in one study.³⁰ In our patient's case, we were concerned about several issues, including the uncertain reduction in AS gradient, the existing degree of moderate AI, and the uncertain duration of BAV benefit. For these reasons and importantly because of the patient's existing AI, BAV was deemed by the heart team as an unreliable treatment option. Although TAVR during pregnancy has not been studied, the existing data suggested that TAVR performed during pregnancy would likely be successful with a lower risk to the fetus and acceptable maternal risk compared with SAVR.³¹ The risk associated with TAVR are well studied in high-risk, inoperable,¹ and intermediate-risk groups.³² We do not know the risk of TAVR in young healthy populations with bicuspid disease.

Procedural Considerations and Planning

Dr Kirker: When our patient first presented, we searched the literature for guidance and found no published TAVR during pregnancy cases. Therefore, a heart team evaluation was critical. The heart team included perinatologists, radiation experts, and other experts to assist with the evaluation, planning, and execution of this procedure. A successful procedure was defined preoperatively as a valve implantation that adequately bridged the patient and fetus to a healthy delivery.

Dr Walsh: In our discussions with the perinatologist, it was emphasized that timing was critical to the success of the

Table 1. Summary of Presentation Transthoracic Echo Data

Ejection fraction	65% to 70%
Aortic peak flow velocity	4.04 m/s
Aortic valve peak gradient	65.39 mmHg
Aortic valve mean gradient	38.22 mmHg
Aortic valve area	1.0 cm ²
Aortic regurgitation, pressure half-time	433 ms

Table 2. Summary of Presentation Stress Echocardiogram Data

Modified Bruce protocol	8–9 METS
Resting aortic valve peak/mean gradient	110/56 mm Hg
Postexercise aortic valve peak/mean gradient	136/78 mm Hg

METS indicates metabolic equivalents.

procedure and the health of the mother and fetus. Consideration was given to fetal viability in the event of premature delivery. Delaying treatment until after 28 weeks' gestation when survival of the fetus would be possible was discussed. The perinatology experts recommended prompt treatment to decrease risks of complications caused by delay. The optimal time for a cardiac procedure during pregnancy is considered to be early in the second trimester.¹² Therefore, the procedure was scheduled for 22 weeks' gestation.

Dr Hodson: Management of radiation exposure to the fetus and mother were of prime concern.¹² Fetal exposure to radiation can cause miscarriage, growth retardation, mental retardation, major malformations, and IQ reduction.³³ At 22 weeks' gestation, acute radiation doses of ≤ 500 mGy are not associated with noncancerous health effects for the pregnancy or the fetus.³³ Radiation doses of < 500 mGy have an estimated childhood cancer incidence rate of $\leq 6\%$ for all gestational ages.³³ Computed tomographic angiography (CTA) is the gold standard for pre-TAVR imaging,³⁴ but CTA is not recommended during pregnancy.³⁵ There is an increased awareness and concern about radiation exposure and lifetime breast cancer risk in women with metabolically active breast tissue during and after pregnancy.^{36,37} Parker et al³⁸ has shown that computed tomographic pulmonary angiography exposes the breasts of an average-sized woman to a radiation dose of 2.0 to 5.0 rad (20–50 mGy), which is roughly equivalent to 10 to 25 two-view mammograms and up to as many as 100 to 400 chest radiographs. If CTA is performed during pregnancy, radiation exposure should be kept to a minimum with high-speed scanning and performed with appropriate shielding.¹²

Dr Korngold, what additional options are there for imaging during pregnancy?

Dr Korngold: Transesophageal echocardiogram (TEE) is an alternative evaluation of the aortic annulus and aortic complex,³⁵ and intravascular ultrasound (IVUS) can be used to visualize the vascular access.³⁹ Three-dimensional (3D) TEE compared with CTA is well validated in the evaluation of the aortic complex and aortic annulus.^{40,41} Sagittal annulus diameters, coronal diameter, and annulus area in TAVR patients were seen to have a 77% agreement between 3D TEE and CTA measurements.⁴⁰ We were able to obtain high-quality TEE images of the patient. Recommendations also state that fluoroscopy and cineangiography should be kept as brief as possible.¹² After consulting with a radiation physicist and radiologists, IVUS, TEE, and fluoroscopy with fluoro saves only were planned as the imaging modalities to reduce radiation exposure. Radiation exposure would occur with fluoroscopy only during the TAVR procedure, and a dose well below 500 mGy was expected. Radiation exposure was not assigned a maximum amount as the patient and family's main concern was for fetus survival.

Dr Walsh: Contrast administration is not approved during pregnancy.¹² Contrast exposure to the fetus has not been researched sufficiently to confirm its effects on fetal abnormalities. However, gadolinium and iodinated contrast mediums have not been found to cause any mutagenic or teratogenic side effects.⁴² There is a theoretical concern that iodine may alter the development of the fetal thyroid if given to a pregnant woman.⁴² The contrast media safety committee of European Society of Urogenital Radiology has approved the use of both iodinated and gadolinium contrast media for use during pregnancy.⁴² To minimize the risk, contrast administration was planned to be used only for aortic root angiography during the TAVR procedure.

Heparin is safe during pregnancy because it does not cross the placenta and is used during pregnancy when anticoagulation is required.⁴³ Heparin would be administered during and after the procedure for prevention of thromboembolism. Low-dose aspirin (80–100 mg/d) is considered safe during pregnancy⁴³ and would be administered postoperatively. High-dose aspirin is not recommended because of risk of fetal bleeding, congenital defects, and loss of pregnancy.⁴³

Table 3. Valvular Heart Lesion Classifications by Maternal and Fetal Risks

Low Maternal and Fetal Risks	High Maternal and Fetal Risks	High Maternal Risks
Asymptomatic AS with a low mean outflow gradient (< 50 mm Hg); normal LV systolic function	Severe AS with or without symptoms	Ejection fraction $< 40\%$
Aortic regurgitation, NYHA class I or II with normal LV function	Aortic regurgitation, NYHA class II, III, or IV	Previous heart failure
Mitral regurgitation, NYHA class I or II, with normal LV function	Mitral stenosis, NYHA class II, III, or IV	Previous stroke or transient ischemic attack
Mitral valve prolapse with none to moderate mitral regurgitation, normal LV function	Mitral regurgitation, NYHA class III or IV	
Mild-to-moderate mitral stenosis, no pulmonary hypertension	Aortic or mitral valve disease with pulmonary hypertension	
Mild-to-moderate pulmonary valve stenosis	Aortic or mitral valve disease with LV dysfunction	
	Maternal cyanosis	
	Reduced functional status, NYHA class III or IV	

AS indicates aortic stenosis; LV, left ventricular; and NYHA, New York Heart Association. Reprinted from Reimold and Rutherford¹⁶ with permission of the publisher. Copyright ©2003, Massachusetts Medical Society.

Table 4. WHO Classification of Maternal Cardiovascular Risk: Definitions

Risk Class	Risk of Pregnancy by Medical Condition
I	No detectable increased risk of maternal mortality and no/mild increase in morbidity.
II	Small increased risk of maternal mortality or moderate increase in morbidity.
III	Significantly increased risk of maternal mortality or severe morbidity. Expert counseling required. If pregnancy is decided upon, intensive specialist cardiac and obstetric monitoring needed throughout pregnancy, childbirth, and the puerperium.
IV	Extremely high risk of maternal mortality or severe morbidity; pregnancy contraindicated. If pregnancy continues, care as for class III.

WHO indicates World Health Organization. Reprinted from Regitz-Zagrosek et al¹² with permission of the publisher. Copyright ©2011, the European Society of Cardiology. Originally adapted from Thorne et al²⁰ with permission of the publisher. Copyright ©2006, BMJ. Authorization for this adaptation has been obtained both from the owner of the copyright in the original work and from the owner of copyright in the translation or adaptation.

Dual-antiplatelet therapy with low-dose aspirin and P2Y12 inhibitor such as clopidogrel is considered standard therapy after TAVR.⁴⁴ There are no adequately controlled trials that have studied P2Y12 inhibitors during pregnancy or breast feeding, and hence, are not recommended.⁴⁵

Dr Kirker: TAVR procedures are performed using several different arterial access approaches⁴⁶ with percutaneous transfemoral access being the preferred approach. In a young healthy female patient, the iliofemoral anatomy was expected to be >6.0 mm and therefore able to accommodate the delivery sheaths and catheters. If the IVUS displayed a <6.0 mm iliofemoral access, the subclavian artery was planned as a backup access approach.

Dr Hodson: Annulus sizing was determined using the preoperative 3D TEE images shown in Figure 2. The aortic valve annulus diameter was measured to be 23.2×22.5 mm (Figure 2). After review of the case and TEE images with national and international experts, a plan was devised for a high implant to ensure sealing within the bicuspid anatomy.

Dr Kirker: The available valves at the time of the procedure were the Sapien XT (Edwards Life Sciences) and the CoreValve (Medtronic). The Sapien XT valve has the advantage of carrying a low risk of heart block and bradyarrhythmias necessitating a permanent pacer (5.3%) within 30 days postoperatively⁴⁷ but presents a few limitations including a minimum access artery dimension of 6.5 mm and not being able to be repositioned.⁴⁷ If the Sapien XT was used, the treatment team would require accurate dimensions of the aortic complex with a high confidence in the imaging modality used to obtain those dimensions. Our practice has been to rely primarily on gated CTA for accurate assessment of the aortic complex. Utilizing the Sapien XT would mean the team would only have one chance to choose the correct valve size. The CoreValve carries a higher risk of conduction abnormalities and higher risk (33.3%) of requiring a permanent pacer within 30 days postoperatively.^{48,49} The

Table 5. WHO Classification of Maternal Cardiovascular Risk by Cardiac Conditions

Risk Class	Cardiac Conditions	
I	Uncomplicated, small, or mild	
	Pulmonary stenosis	
	Patent ductus arteriosus	
	Mitral valve prolapse	
II	Successfully repaired simple lesions (arterial or ventricular septal defect, patent ductus arteriosus, anomalous pulmonary venous drainage)	
	Atrial or ventricular ectopic beats, isolated	
	Unoperated atrial or ventricular septal defect	
	Repaired Tetralogy of Fallot	
	Most arrhythmias	
	II–III (depending on individual)	Mild left ventricular impairment
		Hypertrophic cardiomyopathy
	III	Native or tissue valvular heart disease not considered WHO I or IV
		Marfan syndrome without aortic dilation
		Aorta <45 mm in aortic disease associated with bicuspid aortic valve
Repaired coarctation		
Mechanical valve		
Systemic right ventricle		
Fontan circulation		
Cyanotic heart disease (unrepaired)		
Other complex congenital heart disease		
Aortic dilatation 40–45 mm in Marfan syndrome		
Aortic dilatation 45–50 mm in aortic disease associated with bicuspid aortic valve		
IV (pregnancy contraindicated)	Pulmonary arterial hypertension of any cause	
	Severe systemic ventricular dysfunction (LVEF <30%, NYHA class III–IV)	
	Previous peripartum cardiomyopathy with any residual impairment of left ventricular function	
	Severe mitral stenosis, severe symptomatic aortic stenosis	
	Marfan syndrome with aorta dilated >45 mm	
	Aortic dilatation >50 mm in aortic disease associated with bicuspid aortic valve	
	Native severe coarctation	

LVEF indicates left ventricular ejection fraction; NYHA, New York Heart Association; and WHO, World Health Organization. Reprinted from Regitz-Zagrosek et al¹² with permission of the publisher. Copyright ©2011, the European Society of Cardiology. Originally adapted from Thorne et al²⁰ with permission of the publisher. Copyright ©2006, BMJ. Authorization for this adaptation has been obtained both from the owner of the copyright in the original work and from the owner of copyright in the translation or adaptation.

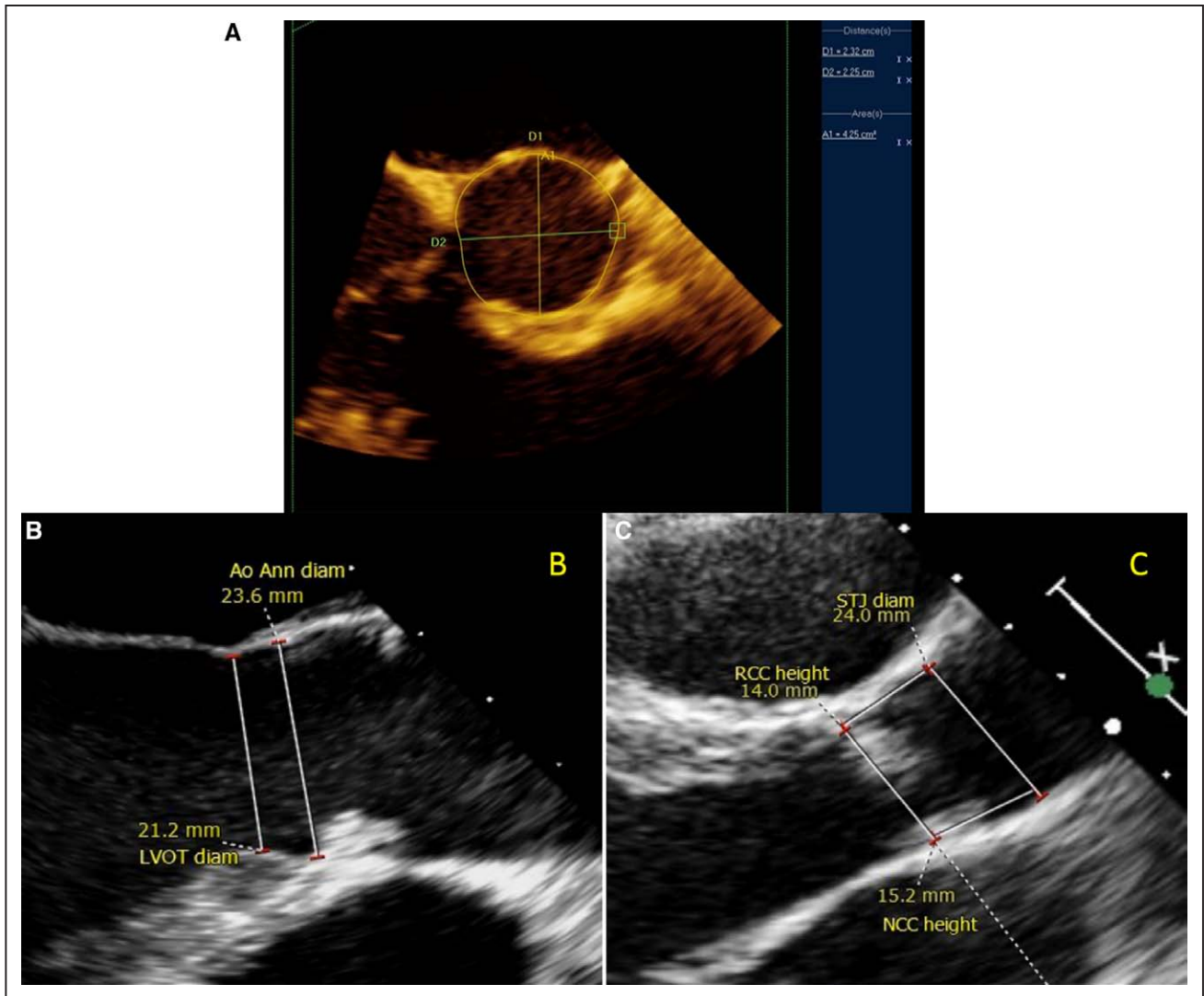


Figure 2. Preoperative 3D transesophageal echocardiogram images. **A**, Aortic annulus diameter (Ao Ann diam; 23.2×22.5 mm) and annulus area (425 mm²). **B**, Aortic annulus diameter (23.6 mm) and left ventricular outflow tract diameter (LVOT; 21.2 mm). **C**, Sinotubular junction diameter (STJ diam; 24 mm). NCC indicates noncoronary cusp; and RCC, right-coronary cusp.

long-term durability of both of these valves are not fully known. For this case, the CoreValve seemed preferable to the Sapien XT because of the minimum requirement of a 6.0 mm access artery dimension for all valve sizes and the potential to be repositioned or removed if a different size was required.⁵⁰ A self-expanding platform leads to more room for error in valve sizing. The long-term effects on the annulus and aortic root because of a younger patient's more flexible, less calcified annulus and aortic root were considered. A 26-mm CoreValve was selected for this procedure because of the smaller sheath size requirement and the flexibility of valve sizing and positioning.

Dr Swanson: Even with the above planning and considerations, there were still several features about this procedure that were unknown, including the amount of calcification, tissue holding forces, long-term effects on soft aortic tissue, oversizing risks, need for a pacemaker, and fetal thyroid development. It is recognized that failure of the procedure, major injury to the thoracic aorta, abdominal aorta, or iliac

arteries could potentially result in fetal demise. The uterine artery is a major sub-branch of the internal iliac artery. Vascular complications that would require rescue with an aortic occlusion balloon and no blood flow to the placenta, even transiently, would result in almost certain injury or death of the fetus. Occlusion of an internal iliac artery is generally well tolerated because of contralateral iliac collateral circulation. The TAVR delivery sheath may occlude the iliac artery during TAVR procedures, depending on sheath size and patient anatomy. Transient occlusion of one of the common iliac arteries during pregnancy could theoretically be tolerated without fetal injury. However, there is no extensive experience regarding fetal health with acute internal iliac occlusion. Because of ethical concerns, randomized trials will likely never be available to guide management of iliac injury during pregnancy. Emergency surgical rescue for aortic valve replacement, aortic root repair, and repair of aortic dissection was also discussed and would be executed as a last option to save the mother, with the understanding that fetal loss was likely.

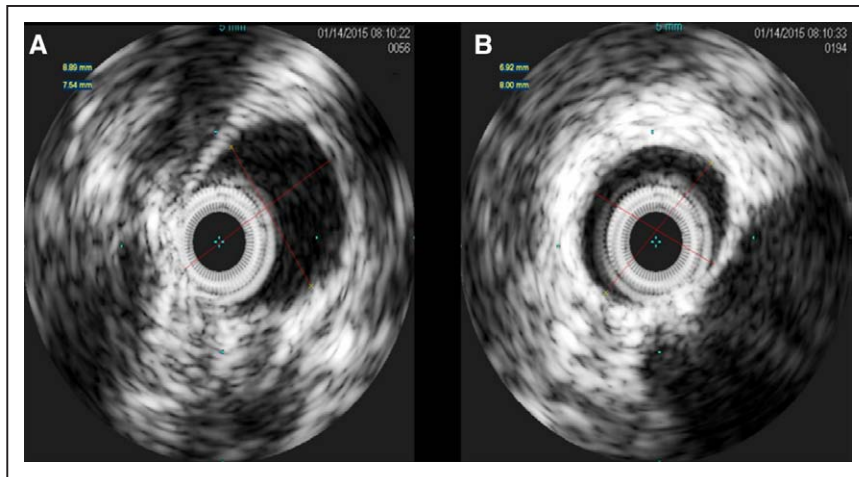


Figure 3. Intraoperative intravascular ultrasound images were taken of the right common femoral artery (A) and the right external iliac artery (B). The iliofemoral access site was a normal 7 to 8 mm anatomy.

Procedure

The procedure was performed as planned employing general anesthesia at 22 weeks' gestation. The patient was pretreated with aspirin 81 mg, and heparin was administered during the procedure. Removable lead sheeting (from a catheterization laboratory table shield) was placed on the procedure table underneath the patient providing shielding from above the umbilicus to below the mid-thigh. Removable lead was used for the event when emergency imaging of the abdomen and pelvis was required. In addition, standard gonadal shielding was positioned to further protect the uterus and fetus.

IVUS demonstrated a normal 7 to 8 mm iliofemoral anatomy (Figure 3). Only 3D TEE, fluoroscopy, and fluoro saves (no cineangiography) were used to assist in the positioning and deployment of the 26-mm CoreValve valve with a high implant. If necessary, the valve could have been sized up to 29 mm, which proved unnecessary because 26 mm was delivered successfully. A mild paravalvular leak was observed. A new left bundle branch block occurred, and a temporary pacing wire was placed. Radiation was limited to 10.3 minutes of fluoro time (at 7.5 frames per second), 101.3 mGy of cumulative air kerma, 1325 cGycm² of dose–area product, and only fluoroscopic images were taken. Eighty-seven milliliters of iohexol 240 of contrast was used.

Clinical Outcome

Immediately after the procedure, the fetal heart rate and maternal reported fetal activity were normal. Low-dose aspirin and low-dose heparin were administered after the procedure. The patient was discharged on postoperative day 5 on low-dose aspirin only and with a persistent new left bundle branch block but no high-degree atrioventricular block. The pregnancy progressed uneventfully, and labor was induced at 38 weeks' gestation, resulting in an uncomplicated vaginal delivery of a healthy baby girl.

Conclusions

Symptomatic AS during pregnancy is a high-risk condition for both the mother and the fetus. A TAVR procedure was chosen because of the perceived high likelihood of success and low probability of complications to safely bridge both the mother and fetus to delivery. In the interest of fetal safety

and decreased maternal cancer risk, radiation and contrast exposure had to be minimized. High-quality preoperative and intraoperative 3D TEE and intraoperative IVUS were used. CTA and cineangiography were successfully avoided. Arguably, the most critical piece to the success of this procedure was the heart team evaluation and discussion. The heart team included nontraditional members such as radiation experts and perinatologists, and the team consulted with national and international experts to determine the best course of action for the mother and fetus. The anecdotal experience of this successful case leads us to suggest that TAVR should be researched as a possible low-risk option for the treatment of AS during pregnancy.

Disclosures

None.

References

- Leon MB, Smith CR, Mack M, Miller DC, Moses JW, Svensson LG, Tuzcu EM, Webb JG, Fontana GP, Makkar RR, Brown DL, Block PC, Guyton RA, Pichard AD, Bavaria JE, Herrmann HC, Douglas PS, Petersen JL, Akin JJ, Anderson WN, Wang D, Pocock S; PARTNER Trial Investigators. Transcatheter aortic-valve implantation for aortic stenosis in patients who cannot undergo surgery. *N Engl J Med*. 2010;363:1597–1607. doi: 10.1056/NEJMoa1008232.
- Yap SC, Drenthen W, Pieper PG, Moons P, Mulder BJ, Mostert B, Vliegen HW, van Dijk AP, Meijboom FJ, Steegers EA, Roos-Hesselink JW; ZAHARA Investigators. Risk of complications during pregnancy in women with congenital aortic stenosis. *Int J Cardiol*. 2008;126:240–246. doi: 10.1016/j.ijcard.2007.03.134.
- Weiss BM, von Segesser LK, Alon E, Seifert B, Turina MI. Outcome of cardiovascular surgery and pregnancy: a systematic review of the period 1984–1996. *Am J Obstet Gynecol*. 1998;179(6 pt 1):1643–1653.
- Davies GA, Herbert WN. Congenital heart disease in pregnancy. *J Obstet Gynaecol Can*. 2007;29:409–414.
- Lao TT, Sermer M, MaGee L, Farine D, Colman JM. Congenital aortic stenosis and pregnancy—a reappraisal. *Am J Obstet Gynecol*. 1993;169:540–545.
- Roberts WC. The congenitally bicuspid aortic valve. A study of 85 autopsy cases. *Am J Cardiol*. 1970;26:72–83.
- Campbell M. Calcific aortic stenosis and congenital bicuspid aortic valves. *Br Heart J*. 1968;30:606–616.
- Bauer T, Linke A, Sievert H, Kahlert P, Hambrecht R, Nickenig G, Hauptmann KE, Sack S, Gerckens U, Schneider S, Zeymer U, Zahn R. Comparison of the effectiveness of transcatheter aortic valve implantation in patients with stenotic bicuspid versus tricuspid aortic valves (from the German TAVI Registry). *Am J Cardiol*. 2014;113:518–521. doi: 10.1016/j.amjcard.2013.10.023.

9. Nishimura RA, Otto CM, Bonow RO, Carabello BA, Erwin JP 3rd, Guyton RA, O'Gara PT, Ruiz CE, Skubas NJ, Sorajja P, Sundt TM 3rd, Thomas JD; American College of Cardiology/American Heart Association Task Force on Practice Guidelines. 2014 AHA/ACC guideline for the management of patients with valvular heart disease: executive summary: a report of the American College of Cardiology/American Heart Association Task Force on Practice Guidelines. *J Am Coll Cardiol*. 2014;63:2438–2488. doi: 10.1016/j.jacc.2014.02.537.
10. Sliwa K, Johnson MR, Zilla P, Roos-Hesslink JW. Management of valvular disease in pregnancy: a global perspective. *Eur Heart J*. 2015;36:1078–1089. doi: 10.1093/eurheartj/ehv050.
11. Pessel C, Bonanno C. Valve disease in pregnancy. *Semin Perinatol*. 2014;38:273–284. doi: 10.1053/j.semperi.2014.04.016.
12. European Society of Gynecology (ESG); Association for European Paediatric Cardiology (AEPIC); German Society for Gender Medicine (DGesGM); Regitz-Zagrosek V, Blomstrom Lundqvist C, Borghi C, Cifkova R, Ferreira R, Foidart JM, Gibbs JS, Gohlke-Baerwolf C, Gorenek B, Lung B, Kirby M, Maas AH, Morais J, Nihoyannopoulos P, Pieper PG, Presbitero P, Roos-Hesslink JW, Schaufelberger M, Seeland U, Torracca L; ESC Committee for Practice Guidelines. ESC guidelines on the management of cardiovascular diseases during pregnancy: the Task Force on the Management of Cardiovascular Diseases During Pregnancy of the European Society of Cardiology (ESC). *Eur Heart J*. 2011;32:3147–3197.
13. Padang R, Bannon PG, Jeremy R, Richmond DR, Semsarian C, Vally M, Wilson M, Yan TD. The genetic and molecular basis of bicuspid aortic valve associated thoracic aortopathy: a link to phenotype heterogeneity. *Ann Cardiothorac Surg*. 2013;2:83–91. doi: 10.3978/j.issn.2225-319X.2012.11.17.
14. Immer FF, Bansi AG, Immer-Bansi AS, McDougall J, Zehr KJ, Schaff HV, Carrel TP. Aortic dissection in pregnancy: analysis of risk factors and outcome. *Ann Thorac Surg*. 2003;76:309–314.
15. Gersony DR, McClaughlin MA, Jin Z, Gersony WM. The effect of beta-blocker therapy on clinical outcome in patients with Marfan's syndrome: a meta-analysis. *Int J Cardiol*. 2007;114:303–308. doi: 10.1016/j.ijcard.2005.11.116.
16. Reimold SC, Rutherford JD. Clinical practice. Valvular heart disease in pregnancy. *N Engl J Med*. 2003;349:52–59. doi: 10.1056/NEJMcp021265.
17. Thorne SA. Pregnancy in heart disease. *Heart*. 2004;90:450–456.
18. Hameed A, Karaalp IS, Tummala PP, Wani OR, Canetti M, Akhter MW, Goodwin I, Zapadinsky N, Elkayam U. The effect of valvular heart disease on maternal and fetal outcome of pregnancy. *J Am Coll Cardiol*. 2001;37:893–899.
19. Roeder HA, Kuller JA, Barker PC, James AH. Maternal valvular heart disease in pregnancy. *Obstet Gynecol Surv*. 2011;66:561–571. doi: 10.1097/OGX.0b013e318238605d.
20. Thorne S, MacGregor A, Nelson-Piercy C. Risks of contraception and pregnancy in heart disease. *Heart*. 2006;92:1520–1525. doi: 10.1136/hrt.2006.095240.
21. Yates MT, Soppa G, Smelt J, Fletcher N, van Besouw JP, Thilaganathan B, Jahangiri M. Perioperative management and outcomes of aortic surgery during pregnancy. *J Thorac Cardiovasc Surg*. 2015;149:607–610. doi: 10.1016/j.jtcvs.2014.10.038.
22. American College of Obstetricians and Gynecologists. ACOG practice bulletin: clinical management guidelines for obstetrician-gynecologists: Number 38, September 2002. Perinatal care at the threshold of viability. *Obstet Gynecol*. 2002;100:617–624.
23. Williams GM, Gott VL, Brawley RK, Schauble JF, Labs JD. Aortic disease associated with pregnancy. *J Vasc Surg*. 1988;8:470–475.
24. John AS, Gurley F, Schaff HV, Warnes CA, Phillips SD, Arendt KW, Abel MD, Rose CH, Connolly HM. Cardiopulmonary bypass during pregnancy. *Ann Thorac Surg*. 2011;91:1191–1196. doi: 10.1016/j.athoracsur.2010.11.037.
25. Pomini F, Mercogliano D, Cavalletti C, Caruso A, Pomini P. Cardiopulmonary bypass in pregnancy. *Ann Thorac Surg*. 1996;61:259–268. doi: 10.1016/0003-4975(95)00818-7.
26. Elassy SM, Elmidany AA, Elbawab HY. Urgent cardiac surgery during pregnancy: a continuous challenge. *Ann Thorac Surg*. 2014;97:1624–1629. doi: 10.1016/j.athoracsur.2013.10.067.
27. Bhargava B, Agarwal R, Yadav R, Bahl VK, Manchanda SC. Percutaneous balloon aortic valvuloplasty during pregnancy: use of the Inoue balloon and the physiologic antegrade approach. *Cathet Cardiovasc Diagn*. 1998;45:422–425.
28. McIvor RA. Percutaneous balloon aortic valvuloplasty during pregnancy. *Int J Cardiol*. 1991;32:1–3.
29. Ben-Dor I, Pichard AD, Satler LF, Goldstein SA, Syed AI, Gaglia MA Jr, Weissman G, Maluenda G, Gonzalez MA, Wakabayashi K, Collins SD, Torguson R, Okubagzi P, Xue Z, Kent KM, Lindsay J, Waksman R. Complications and outcome of balloon aortic valvuloplasty in high-risk or inoperable patients. *JACC Cardiovasc Interv*. 2010;3:1150–1156. doi: 10.1016/j.jcin.2010.08.014.
30. McKay RG. The Mansfield Scientific Aortic Valvuloplasty Registry: overview of acute hemodynamic results and procedural complications. *J Am Coll Cardiol*. 1991;17:485–491.
31. Cheung A, Ree R. Transcatheter aortic valve replacement. *Anesthesiol Clin*. 2008;26:465–479. doi: 10.1016/j.anclin.2008.05.002.
32. Leon MB, Smith CR, Mack MJ, Makkar RR, Svensson LG, Kodali SK, Thourani VH, Tuzcu EM, Miller DC, Herrmann HC, Doshi D, Cohen DJ, Pichard AD, Kapadia S, Dewey T, Babaliaros V, Szteto WY, Williams MR, Kereiakes D, Zajarias A, Greason KL, Whisenant BK, Hodson RW, Moses JW, Trento A, Brown DL, Fearon WF, Pibarot P, Hahn RT, Jaber WA, Anderson WN, Alu MC, Webb JG; PARTNER 2 Investigators. Transcatheter or surgical aortic-valve replacement in intermediate-risk patients. *N Engl J Med*. 2016;374:1609–1620. doi: 10.1056/NEJMoa1514616.
33. International Commission on Radiological Protection. ICRP Publication 84: Pregnancy and Medical Radiation. Tarrytown, NY: Pergamon, Elsevier Science, Inc; 2000:46.
34. Wake N, Kumamaru K, Prior R, Rybicki FJ, Steigner ML. Computed tomography angiography for transcatheter aortic valve replacement. *Radiol Technol*. 2013;84:326–340.
35. Hiratzka LF, Bakris GL, Beckman JA, Bersin RM, Carr VF, Casey DE Jr, Eagle KA, Hermann LK, Isselbacher EM, Kazerooni EA, Kouchoukos NT, Lytle BW, Milewicz DM, Reich DL, Sen S, Shinn JA, Svensson LG, Williams DM; American College of Cardiology Foundation/American Heart Association Task Force on Practice Guidelines; American Association for Thoracic Surgery; American College of Radiology; American Stroke Association; Society of Cardiovascular Anesthesiologists; Society for Cardiovascular Angiography and Interventions; Society of Interventional Radiology; Society of Thoracic Surgeons; Society for Vascular Medicine. 2010 ACCF/AHA/AATS/ACR/ASA/SCA/SCAI/SIR/STS/SVM guidelines for the diagnosis and management of patients with thoracic aortic disease. A Report of the American College of Cardiology Foundation/American Heart Association Task Force on Practice Guidelines, American Association for Thoracic Surgery, American College of Radiology, American Stroke Association, Society of Cardiovascular Anesthesiologists, Society for Cardiovascular Angiography and Interventions, Society of Interventional Radiology, Society of Thoracic Surgeons, and Society for Vascular Medicine. *J Am Coll Cardiol*. 2010;55:e27–e129. doi: 10.1016/j.jacc.2010.02.015.
36. Hurwitz LM, Yoshizumi TT, Reiman RE, Paulson EK, Frush DP, Nguyen GT, Toncheva GI, Goodman PC. Radiation dose to the female breast from 16-MDCT body protocols. *AJR Am J Roentgenol*. 2006;186:1718–1722. doi: 10.2214/AJR.04.1917.
37. Cook JV, Kyriou J. Radiation from CT and perfusion scanning in pregnancy. *BMJ*. 2005;331:350. doi: 10.1136/bmj.331.7512.350.
38. Parker MS, Hui FK, Camacho MA, Chung JK, Broga DW, Sethi NN. Female breast radiation exposure during CT pulmonary angiography. *AJR Am J Roentgenol*. 2005;185:1228–1233. doi: 10.2214/AJR.04.0770.
39. Zoghbi WA, Chambers JB, Dumesnil JG, Foster E, Gottdiener JS, Grayburn PA, Khandheria BK, Levine RA, Marx GR, Miller FA Jr, Nakatani S, Quiñones MA, Rakowski H, Rodriguez LL, Swaminathan M, Waggoner AD, Weissman NJ, Zabalgoitia M; American Society of Echocardiography's Guidelines and Standards Committee; Task Force on Prosthetic Valves; American College of Cardiology Cardiovascular Imaging Committee; Cardiac Imaging Committee of the American Heart Association; European Association of Echocardiography; European Society of Cardiology; Japanese Society of Echocardiography; Canadian Society of Echocardiography; American College of Cardiology Foundation; American Heart Association; European Association of Echocardiography; European Society of Cardiology; Japanese Society of Echocardiography; Canadian Society of Echocardiography. Recommendations for evaluation of prosthetic valves with echocardiography and Doppler ultrasound: a report From the American Society of Echocardiography's Guidelines and Standards Committee and the Task Force on Prosthetic Valves, developed in conjunction with the American College of Cardiology Cardiovascular Imaging Committee, Cardiac Imaging Committee of the American Heart Association, the European Association of Echocardiography, a registered branch of the European Society of Cardiology, the Japanese Society of

- Echocardiography and the Canadian Society of Echocardiography, endorsed by the American College of Cardiology Foundation, American Heart Association, European Association of Echocardiography, a registered branch of the European Society of Cardiology, the Japanese Society of Echocardiography, and Canadian Society of Echocardiography. *J Am Soc Echocardiogr*. 2009;22:975–1014, quiz 1082. doi: 10.1016/j.echo.2009.07.013.
40. Husser O, Holzamer A, Resch M, Endemann DH, Nunez J, Bodí V, Schmid C, Riegger GA, Gössmann H, Hamer O, Stroszczyński C, Luchner A, Hilker M, Hengstenberg C. Prosthesis sizing for transcatheter aortic valve implantation—comparison of three dimensional transesophageal echocardiography with multislice computed tomography. *Int J Cardiol*. 2013;168:3431–3438. doi: 10.1016/j.ijcard.2013.04.182.
 41. Altiok E, Koos R, Schröder J, Brehmer K, Hamada S, Becker M, Mahnken AH, Almalla M, Dohmen G, Autschbach R, Marx N, Hoffmann R. Comparison of two-dimensional and three-dimensional imaging techniques for measurement of aortic annulus diameters before transcatheter aortic valve implantation. *Heart*. 2011;97:1578–1584. doi: 10.1136/hrt.2011.223974.
 42. Webb JA, Thomsen HS, Morcos SK; Members of Contrast Media Safety Committee of European Society of Urogenital Radiology (ESUR). The use of iodinated and gadolinium contrast media during pregnancy and lactation. *Eur Radiol*. 2005;15:1234–1240. doi: 10.1007/s00330-004-2583-y.
 43. James AH, Abel DE, Branciazio LR. Anticoagulants in pregnancy. *Obstet Gynecol Surv*. 2006;61:59–69, quiz 70–72.
 44. Ussia GP, Scarabelli M, Mulè M, Barbanti M, Sarkar K, Cammalleri V, Immè S, Aruta P, Pistrutto AM, Gulino S, Deste W, Capodanno D, Tamburino C. Dual antiplatelet therapy versus aspirin alone in patients undergoing transcatheter aortic valve implantation. *Am J Cardiol*. 2011;108:1772–1776. doi: 10.1016/j.amjcard.2011.07.049.
 45. Tello-Montoliu A, Seecheran NA, Angiolillo DJ. Successful pregnancy and delivery on prasugrel treatment: considerations for the use of dual antiplatelet therapy during pregnancy in clinical practice. *J Thromb Thrombolysis*. 2013;36:348–351. doi: 10.1007/s11239-012-0830-7.
 46. Masson JB, Kovac J, Schuler G, Ye J, Cheung A, Kapadia S, Tuzcu ME, Kodali S, Leon MB, Webb JG. Transcatheter aortic valve implantation: review of the nature, management, and avoidance of procedural complications. *JACC Cardiovasc Interv*. 2009;2:811–820. doi: 10.1016/j.jcin.2009.07.005.
 47. Durand E, Borz B, Godin M, Tron C, Litzler PY, Bessou JP, Bejar K, Fraccaro C, Sanchez-Giron C, Dacher JN, Bauer F, Cribrier A, Eltchaninoff H. Transfemoral aortic valve replacement with the Edwards SAPIEN and Edwards SAPIEN XT prosthesis using exclusively local anesthesia and fluoroscopic guidance: feasibility and 30-day outcomes. *JACC Cardiovasc Interv*. 2012;5:461–467. doi: 10.1016/j.jcin.2012.01.018.
 48. Khawaja MZ, Rajani R, Cook A, Khavandi A, Moynagh A, Chowdhary S, Spence MS, Brown S, Khan SQ, Walker N, Trivedi U, Hutchinson N, De Belder AJ, Moat N, Blackman DJ, Levy RD, Manoharan G, Roberts D, Khogali SS, Crean P, Brecker SJ, Baumbach A, Mullen M, Laborde JC, Hildick-Smith D. Permanent pacemaker insertion after CoreValve transcatheter aortic valve implantation: incidence and contributing factors (the UK CoreValve Collaborative). *Circulation*. 2011;123:951–960. doi: 10.1161/CIRCULATIONAHA.109.927152.
 49. Tzikas A, van Dalen BM, Van Mieghem NM, Gutierrez-Chico JL, Nuis RJ, Kauer F, Schultz C, Serruys PW, de Jaegere PP, Geleijnse ML. Frequency of conduction abnormalities after transcatheter aortic valve implantation with the Medtronic-CoreValve and the effect on left ventricular ejection fraction. *Am J Cardiol*. 2011;107:285–289. doi: 10.1016/j.amjcard.2010.09.015.
 50. Grube E, Schuler G, Buellesfeld L, Gerckens U, Linke A, Wenaweser P, Sauren B, Mohr FW, Walther T, Zickmann B, Iversen S, Felderhoff T, Cartier R, Bonan R. Percutaneous aortic valve replacement for severe aortic stenosis in high-risk patients using the second- and current third-generation self-expanding CoreValve prosthesis: device success and 30-day clinical outcome. *J Am Coll Cardiol*. 2007;50:69–76. doi: 10.1016/j.jacc.2007.04.047.

KEY WORDS: aortic valve ■ body mass index ■ body surface area ■ dizziness ■ pregnancy